

GUIDELINES

The Chinese Society of Clinical Oncology (CSCO): Clinical guidelines for the diagnosis and treatment of colorectal cancer, 2024 update

Feng Wang¹  | Gong Chen² | Zhen Zhang³ | Ying Yuan⁴  | Yi Wang⁵ | Yuan-Hong Gao⁶ | Weiqi Sheng⁷ | Zixian Wang¹  | Xinxiang Li⁸ | Xianglin Yuan⁹ | Sanjun Cai⁸ | Li Ren¹⁰ | Yunpeng Liu¹¹ | Jianmin Xu¹⁰  | Yanqiao Zhang¹² | Houjie Liang¹³  | Xicheng Wang¹⁴ | Aiping Zhou¹⁵ | Jianming Ying¹⁶ | Guichao Li³ | Muyan Cai¹⁷  | Gang Ji¹⁸ | Taiyuan Li¹⁹ | Jingyu Wang²⁰ | Hanguang Hu⁴ | Kejun Nan²¹ | Liuhong Wang²² | Suzhan Zhang²³ | Jin Li²⁴ | Rui-Hua Xu²⁵ 

Correspondence

Rui-Hua Xu, Department of Medical Oncology, Sun Yat-sen University Cancer Center, State Key Laboratory of Oncology in South China, Guangdong Provincial Clinical Research Center for Cancer, Sun Yat-sen University, Research Unit of Precision Diagnosis and Treatment for Gastrointestinal Cancer, Chinese Academy of Medical Sciences, Guangzhou, Guangdong, P. R. China.
Email: xurh@sysucc.org.cn

Jin Li, Department of Medical Oncology, Shanghai GoBroad Cancer Hospital, China Pharmaceutical University, Shanghai, P. R. China.
Email: lijin@cSCO.org.cn

Suzhan Zhang, Department of Colorectal Surgery, The Second Affiliated Hospital, Zhejiang University School of Medicine, Hangzhou, Zhejiang, P. R. China.
Email: zuci@zju.edu.cn

Abstract

The 2024 updates of the Chinese Society of Clinical Oncology (CSCO) Clinical Guidelines for the diagnosis and treatment of colorectal cancer emphasize standardizing cancer treatment in China, highlighting the latest advancements in evidence-based medicine, healthcare resource access, and precision medicine in oncology. These updates address disparities in epidemiological trends, clinicopathological characteristics, tumor biology, treatment approaches, and drug selection for colorectal cancer patients across diverse regions and backgrounds. Key revisions include adjustments to evidence levels for intensive treatment strategies, updates to regimens for deficient mismatch repair (dMMR)/ microsatellite instability-high (MSI-H) patients, proficient mismatch repair (pMMR)/ microsatellite stability (MSS) patients who have failed standard therapies, and rectal cancer patients with low recurrence risk. Additionally, recommendations for digital rectal examination and DNA polymerase epsilon (*POLE*)/ DNA polymerase delta 1 (*POLD1*) gene mutation testing have been strengthened. The 2024 CSCO Guidelines are based on both Chinese and international clinical research, as well as expert consensus, ensuring their relevance and applicability in clinical practice, while maintaining a commitment to scientific rigor, impartiality, and timely updates.

Feng Wang, Gong Chen and Zhen Zhang contributed equally.

This is an open access article under the terms of the [Creative Commons Attribution-NonCommercial-NoDerivs](https://creativecommons.org/licenses/by-nc-nd/4.0/) License, which permits use and distribution in any medium, provided the original work is properly cited, the use is non-commercial and no modifications or adaptations are made.

© 2024 The Author(s). *Cancer Communications* published by John Wiley & Sons Australia, Ltd. on behalf of Sun Yat-sen University Cancer Center.

KEYWORDS

adjuvant, chemotherapy, Chinese Society of Clinical Oncology (CSCO), colorectal cancer, diagnosis, immunotherapy, neoadjuvant, radiotherapy, surgery, targeted therapy

BACKGROUND

There exist disparities in the epidemiological characteristics, clinicopathological features, tumor biology, treatment

Abbreviations: 3D-CRT, three dimensional-conformal radiation therapy; 5-FU, 5-fluorouracil; ADC, antibody-drug-conjugates; AJCC, the American Joint Committee on Cancer; APR, abdominoperineal resection; AR, anterior resection; ARMS, amplification-refractory mutation system; AXEPT, the Asian XELIRI Project; BRAF, v-raf murine sarcoma viral oncogene homolog B; CA125, carbohydrate antigen 125; CA199, carbohydrate antigen 199; CAPEOX (also known as XELOX), This chemotherapy combination contains the drugs capecitabine and oxaliplatin; cCR, clinical complete response; CDX, caudal type homeobox; CEA, carcinoembryonic antigen; CEP, centromere protein; CHRPE, congenital hypertrophy of the retinal pigment epithelium; CK, cytokeratin; cM, clinical M staging; cN, clinical N staging; CRS, clinical risk score; CSCO, the Chinese Society of Clinical Oncology; CT, computed tomography; cT, clinical T staging; cTNM, clinical TNM staging; ctDNA, circulating tumor DNA; CTLA-4, cytotoxic T-lymphocyte associated protein 4; dMMR, deficient mismatch repair; DWI, diffusion-weighted imaging; EGFR, epidermal growth factor receptor; EMR, endoscopic mucosal resection; EMVI, extramural vascular invasion; ESD, endoscopic submucosal dissection; ESMO, the European Society for Medical Oncology; FAP, familial adenomatous polyposis; FDG-PET, a fludeoxyglucose-18 (FDG) positron emission tomography (PET); FISH, fluorescence in situ hybridization; FIT, fetal immunochemical test; FOLFIRI, This chemotherapy combination contains the drugs leucovorin calcium (folinic acid), fluorouracil, and irinotecan hydrochloride; FOLFOX, This chemotherapy combination contains the drugs leucovorin calcium (folinic acid), fluorouracil, and oxaliplatin; FOLFOXIRI, The regimen consists of oxaliplatin, irinotecan, leucovorin, 5-fluorouracil, bevacizumab; FOV, field-of-view; HER-2, human epidermal growth factor receptor; IDEA, the International Duration Evaluation of Adjuvant Chemotherapy; IHC, immunohistochemistry; IMRT, intensity-modulated radiation therapy; ITBCC, International Consensus on Tumor Budding in Colorectal Cancer; IV, intravenous; KRAS, kirsten rat sarcoma viral oncogene homolog; LLNM, lateral lymph node metastasis; LV, leucovorin; LVI, vascular and lymphatic invasion; MDT, multidisciplinary team; MEK, mitogen-activated protein kinase kinase; mFOLFOX6, An abbreviation for a combination chemotherapy regimen that is used to treat colorectal cancer. It includes the drugs leucovorin calcium (folinic acid), fluorouracil, and oxaliplatin; MMR, mismatch repair; MOSAIC, Multicenter International Study of Oxaliplatin/Fluorouracil/Leucovorin in the Adjuvant Treatment of Colon Cancer; MRD, minimal residual disease; MRF, mesorectal fascia; MRI, magnetic resonance imaging; MSI, microsatellite instability; MSI-H, microsatellite instability-high; MSI-L, microsatellite instability-low; MSKCC, Memorial Sloan Kettering Cancer Center; MUTYH, mutY DNA glycosylase; NCCN, National Comprehensive Cancer Network; NCI, National Cancer Institute; NGS, next-generation sequencing technology; NMPA, the National Medical Products Administration; NTRK, neurotrophic tyrosine receptor kinase; ORR, objective response rates; OS, overall survival; pCR, pathological

patterns, and drug selections between colorectal cancer patients in China and other countries. The Chinese Society of Clinical Oncology (CSCO) has organized a panel of senior experts specializing in all sub-specialties of colorectal cancer to compose a clinical guideline for the diagnosis and treatment of colorectal cancer since 2016 and renews it annually for cancer therapy standardization in China. These guidelines encompass evidence-based medicine principles while also accounting for the accessibility of healthcare resources and the latest progressions in precision medicine of oncology.

In recent years, the approach of developing clinical practice guidelines has been transformed towards a focus on healthcare resource availability, particularly on the imbalance and lack of healthcare resources in developing countries and regions. China, given its vast geographic expanse and variable economic and academic developments across the regions, CSCO Guidelines require comprehensively considering three significant aspects, including regional disparities, availability of drugs and diagnostic/treatment modalities, and societal value of cancer treatments. Therefore, CSCO Guidelines categorize the recommendations for each clinical question according to the strength of evi-

complete response; PD-1, programmed cell death protein 1; PEMR, piecemeal endoscopic mucosal resection; PET, positron emission tomography; PFS, progress-free survival; PJS, Peutz-Jeghers syndrome; pTNM, pathological TNM staging; pM, pathological M staging; pMMR, proficient mismatch repair; pN, pathological N staging; PNI, perineural invasion; POLDI, DNA polymerase delta 1; POLE, DNA polymerase epsilon; pT, pathological T staging; RAS, rat sarcoma virus; RFA, radiofrequency ablation; rTNM, patients who experience recurrence after a period of tumor-free interval following treatment; SBRT, stereotactic body radiotherapy; SM, submucosal; STK11, serine/threonine kinase 11; SUV, standardized uptake value; T2WI, T2-weighted imaging; TAS-102, Trifluridine/Tipiracil; TD, tumor deposit; TMB, tumor mutation burden; TME, total mesorectal excision; TNM, tumor, node, metastatic; TNT, total neoadjuvant therapy; TRG, tumor regression grade; UGT1A1, UDP glucuronosyltransferase 1 family, polypeptide A1; UICC, the Union for International Cancer Control; US, ultrasound; VEGF, vascular endothelial growth factor; VMAT, volumetric modulated arc therapy; WHO, the World Health Organization; ymrcN, Post neoadjuvant magnetic resonance imaging based clinical N staging; ymrcT, Post neoadjuvant magnetic resonance imaging based clinical T staging; ymrEMVI, Post neoadjuvant magnetic resonance imaging based extramural vascular invasion status; ymrMRF/anal+, Residual tumor signals in the original lesion of rectal cancer, intramesorectal lymph nodes, and EMVI. The distance between the DWI high signal and MRF/anal is ≤ 1 mm post neoadjuvant therapy; ypTNM, pathological TNM staging post neoadjuvant therapy.

dence and expert consensus, while also considering the accessibility and cost-effectiveness of accessible therapies. The recommendations based on robust evidence and with high accessibility are categorized as Grade I, those supported by relatively potent evidence but with lower expert consensus or limited accessibility are designated as Grade II, and recommendations that are clinically feasible but lack substantial evidence are classified as Grade III.

The 2024 CSCO Clinical Guidelines for the Diagnosis and Treatment of Colorectal Cancer include the diagnosis, treatment, follow-up, and screening of colon cancer and rectal cancer. Based on the previous version of the CSCO Colorectal Cancer Guidelines, the 2024 version has provided multiple updates as follows:

1. Diagnosis methods for colorectal cancer: a digital rectal exam was added (Grade I).
2. Principles of pathological diagnosis: DNA polymerase epsilon/DNA polymerase delta 1(*POLE/POLD1*) gene mutation testing was added (Grade III).
3. The treatment for the potentially resectable group:
 - (i) For rat sarcoma virus (*RAS*) and v-raf murine sarcoma viral oncogene homolog B1 (*BRAF*) wild-type patients who are suitable for intensive treatment, “FOLFOXIRI + Cetuximab” was removed from Grade III recommendations.
 - (ii) For *RAS* and *BRAF* wild-type patients who are suitable for intensive treatment and with a primary lesion located in the right-sided colorectum, “FOLFOXIRI ± Bevacizumab” was changed from Category 2A to Category 1A (Grade I).
 - (iii) For *RAS* or *BRAF* mutation patients who are suitable for intensive treatment, “FOLFOXIRI ± Bevacizumab” was changed from Category 2A to Category 1A (Grade I).
4. Second-line treatment regimen for the palliative treatment group:
 - (i) For the microsatellite instability-high (MSI-H)/deficient mismatch repair (dMMR) patients who were not previously treated with immune checkpoint inhibitors in the first-line treatment, Grade II recommendations are modified to “Envafolelimab, Serplulimab, Tislelizumab, or Pucotenlimab (Category 2A), Pembrolizumab and Nivolumab (Category 2A)”, and Grade III recommendations are modified to “Nivolumab + Ipilimumab (Category 2A)”.
 - (ii) For patients (MSS or MSI-L/pMMR), both *RAS* and *BRAF* are wild-types) who were previously treated with Oxaliplatin and Irinotecan therapy and for those patients (MSS or MSI-L/pMMR, with *RAS* or *BRAF* mutation) who were previously treated with Oxaliplatin and Irinotecan, “Trifluridine/Tipiracil (TAS-102) (Category 1A)” is changed to “Trifluridine/Tipiracil (TAS-102) ± Bevacizumab (Category 1A, Grade I)”, and Trifluridine/Tipiracil (TAS-102) + Bevacizumab (Category 2A)” is removed from Grade II recommendations.
 - (iii) Notes are added to summarize the progress of various clinical trials on the immunotherapy of MSS/pMMR metastatic colorectal cancer.
5. Third-line treatment regimen for the palliative treatment group:
 - (i) For MSI-H/dMMR patients who were previously treated with immune checkpoint inhibitors in the first and second lines, Grade II recommendations are modified to “Envafolelimab, Serplulimab, Tislelizumab, or Pucotenlimab (Category 2A), Pembrolizumab and Nivolumab (Category 2A)”, and Grade III recommendations are modified to “Nivolumab + Ipilimumab (Category 2A)”.
 - (ii) For patients (MSS or MSI-L/pMMR, both *RAS* and *BRAF* are wild-type) who were previously treated with Oxaliplatin and Irinotecan therapy and for those patients (MSS or MSI-L/pMMR, with *RAS* or *BRAF* mutation) who were previously treated with Oxaliplatin and Irinotecan, “Trifluridine/Tipiracil (TAS-102) (Category 1A)” is changed to “Trifluridine/Tipiracil (TAS-102) ± Bevacizumab (Category 1A, Grade I)”, and Trifluridine/Tipiracil (TAS-102) + Bevacizumab (Category 2A)” is removed from Grade II recommendations.
 - (iii) Notes are added to summarize the progress of various clinical trials on the immunotherapy of MSS/pMMR metastatic colorectal cancer.
6. Treatment principles for rectal cancer patients with pMMR/MSS or unknown MMR/MS status: For patients with “cT3, N_{any} and mesorectal fascia (MRF)⁻; cT1-2, N+ and with no difficulty in the preservation of the anal sphincter”, the following is added to Grade II recommendations: for highly selective low recurrence risk patients: chemotherapy (assessment) + selective chemoradiotherapy (reassessment) + rectal cancer radical surgery ± chemotherapy (chemoradiotherapy/chemotherapy based on postoperative pathological findings) (Category 1B).

CSCO Guidelines established recommendation grades based on both Chinese and international clinical research findings and supplemented by insights and opinions of CSCO experts. The CSCO Guidelines Working Committee firmly asserts that the guidelines are founded on robust evidence meanwhile taking feasibility and accessibility into consideration. CSCO Guidelines incorporate expert perspectives, aiming at addressing the intricacies of clinical practice, particularly in China, with thorough evaluations and guarantees of scientific rigor, impartiality, and timeliness.

1. The multidisciplinary team (MDT) model for the diagnosis and treatment of colorectal cancer

Contents	Grade I recommendations	Grade II recommendations	Grade III recommendations
MDT discipline composition	<ul style="list-style-type: none"> • Surgery Department: Colorectal Surgery (Gastrointestinal Surgery, General Surgery), Hepatobiliary Surgery • Medical Oncology Department • Radiation Oncology Department • Imaging Department 	<ul style="list-style-type: none"> • Thoracic Surgery Department • Interventional Therapy Department • Pathology Department • Endoscopy Department • Ultrasound Department 	Other related disciplines
MDT member requirements	Senior residents and above	Associate chief physicians and above	None
MDT discussion content	<ul style="list-style-type: none"> • Patients with liver metastases only • Patients with potentially resectable metastases • Patients with mid-low rectal cancer 	<ul style="list-style-type: none"> • Patients requiring special adjuvant treatment decisions • Patients with local recurrence of rectal cancer 	<ul style="list-style-type: none"> • Patients deemed necessary for MDT by attending physician (e.g., difficult or controversial diagnosis and treatment) • Patients recommended for entry into clinical studies • Rare cases
MDT daily activities	<ul style="list-style-type: none"> • Fixed disciplines/fixed experts • Fixed time (recommend to hold every 1-2 weeks) • Fixed location • Fixed equipment (projector, information system) 	Depend on individual circumstances	None

Notes: The role of multidisciplinary teams (MDTs) should be emphasized in the diagnosis and treatment of colorectal cancer. It is recommended that eligible institutions incorporate the diagnosis and treatment of as many colorectal cancer patients as possible into MDT management, especially those with recurrent or metastatic colorectal cancer. During the implementation of MDT, experts from multiple disciplines jointly analyze the patient's clinical manifestations, imaging, pathology, and molecular biology data to make a comprehensive assessment of the patient's general condition, disease diagnosis, stage/invasion scope, progression potential, and prognosis, and formulate the most suitable overall treatment strategies for patients, based on the current Chinese and international treatment standards/guidelines, evidence-based medicine, and the available treatment methods. MDT principles should permeate throughout the entire process of a patient's diagnosis and treatment. MDT should adjust treatment plans promptly according to the changes in the patient's physiological condition and tumor response during treatment to maximize the survival of the patient, improve cure rates, and enhance the quality of life.

Abbreviations: MDT, multidisciplinary team.

2. Principles of colorectal cancer diagnosis

2.1. Screening for colorectal cancer in asymptomatic healthy individuals

Clinical assessments	Grade I recommendations	Grade II recommendations	Grade III recommendations
Colorectal cancer screening for general-risk individuals	<ol style="list-style-type: none"> 1. Individuals aged 50-74 years should undergo initial screening with a high-risk factor questionnaire survey [1-5] and fetal immunochemical test (FIT) [6-8]. Those with positive results should undergo colonoscopy. Subsequent screenings should involve FIT at least once a year, and individuals with positive results should undergo colonoscopy. 2. In eligible regions, individuals aged 50-74 years should directly undergo colonoscopy [9-13]. Those with no detectable colorectal tumors during colonoscopy should undergo colonoscopy every 5 years. Those with detectable colorectal tumors should undergo colonoscopy in the following 1-3 years based on tumor size and pathological type. Subsequent screenings may extend to every 3-5 years if no tumor recurrence is detected. 	None	<ul style="list-style-type: none"> • Fecal DNA [14] test^a • CT colonography [15]^b

(Continues)

Clinical assessments	Grade I recommendations	Grade II recommendations	Grade III recommendations
Colorectal cancer screening for high-risk individuals	<ol style="list-style-type: none"> Colorectal cancer high-risk populations include individuals with a history of colorectal adenomas, a family history of colorectal cancer, and inflammatory bowel disease [9–13]. Annual screening for colorectal cancer should begin at the age of 40 [9]. 	<ol style="list-style-type: none"> Patients with advanced colorectal adenomas (diameter ≥ 1 cm, or with villous structure, or with high-grade dysplasia) should repeatedly undergo colonoscopy within 1-3 years after diagnosis. If no adenoma recurrence is detected, the follow-up interval can be extended to 3-5 years [16]. Individuals with a family history of colorectal cancer should undergo genetic screening. Carriers of inherited mutations in the family should undergo regular colonoscopy, while non-carriers should follow the screening recommendations for the general-risk population (for details see “5 Genetic screening and diagnostic principles for hereditary colorectal cancer”). Patients with inflammatory bowel disease should have regular specialized consultations and discuss colonoscopy intervals with their physicians based on the extent, severity, and existence duration of the lesions. 	Non-advanced adenoma patients should repeatedly undergo colonoscopy within 2-3 years after diagnosis. If no adenoma recurrence is detected, the follow-up interval can be extended to 3-5 years [17, 18].

Abbreviations: FIT, fetal immunochemical test.

^aFetal immunochemical test (FIT)-DNA test is relatively expensive and might be considered when medical resources are relatively abundant. For individuals with positive FIT results, performing FIT-DNA testing before colonoscopy can improve the detection rate by colonoscopy.

^bCT colonography may be applied for individuals who have contraindications for colonoscopy.

2.2. Basic principles for diagnosis

2.2.1. Diagnosis methods for colon cancer

Purpose	Grade I recommendations	Grade II recommendations	Grade III recommendations
Diagnosis	<ul style="list-style-type: none"> Full colonoscopy + biopsy^a Digital rectal exam^b 	<ul style="list-style-type: none"> Contrast-enhanced abdominal/pelvic CT^c Surgical exploration 	None
Staging diagnosis (for colonoscopically confirmed patients)	Non-contrast or contrast-enhanced chest CT and contrast-enhanced abdominal/pelvic CT ^d	<ul style="list-style-type: none"> Non-contrast chest CT and contrast-enhanced abdominal/pelvic MRI^{e,f} Serum CEA CA199 	<ul style="list-style-type: none"> Chest X-ray Abdominal/pelvic US^f

(Continues)

Purpose	Grade I recommendations	Grade II recommendations	Grade III recommendations
Staging diagnosis (for patients with liver metastases that cannot be confirmed by CT)	Non-contrast scan and contrast-enhanced upper abdominal MRI ^g	Hepatocyte-specific contrast-enhanced upper abdominal MRI ^g	Contrast-enhanced upper abdominal US ^h

Abbreviations: CA199, carbohydrate antigen 199; CEA, carcinoembryonic antigen; CT, computed tomography; MRI, magnetic resonance imaging; US, ultrasound.

^aColonoscopy is generally prohibited in patients with clinically evident intestinal obstruction, as bowel preparation before the examination may exacerbate the obstruction or cause perforation.

^bA digital rectal exam can provide specific clinical signs of whether there are tumor lesions in the pelvic floor, which is a specific clinical sign of peritoneal metastasis.

^cFor patients who are not eligible, who refuse a full colonoscopy, or whose colonoscopy cannot examine the entire colon, it is recommended to perform a contrast-enhanced abdominal/pelvic CT scan after bowel cleansing.

^dContrast-enhanced chest CT is recommended for diagnosis and differential diagnosis of metastatic lymph nodes. Continuous thin-section axial, coronal, and sagittal reconstructed images are recommended for diagnosis and differential diagnosis of pulmonary metastases from colorectal cancer wherever possible [19]. Enhanced abdominal and pelvic CT is recommended for diagnosis of ovarian metastases and peritoneal metastases.

^eFor patients with contraindications to venous contrast, it is recommended to perform contrast-enhanced abdominal/pelvic MRI plus non-contrast-enhanced chest CT.

^fWhen the diagnosis of ovarian metastasis cannot be confirmed by CT, pelvic MRI or gynecologic ultrasound is recommended to support the diagnosis, and MRI is recommended to include T2-weighted imaging (T2WI), diffusion-weighted imaging (DWI), and multi-phase T1-weighted enhanced imaging sequences [20].

^gWhen the diagnosis of liver metastases cannot be confirmed by CT or when treatment decisions for liver metastases need to be changed, liver MRI including T2WI, DWI, and multi-phase T1-weighted enhanced imaging sequences is recommended to determine the number, size, and distribution of liver metastases. Eligible patients may directly choose Hepatocyte-specific contrast-enhanced liver MRI, which is more helpful in detecting lesions smaller than 1 cm, especially metastases that cannot be visualized by CT after chemotherapy [21, 22].

^hFor eligible patients, contrast-enhanced liver ultrasound or contrast-enhanced intraoperative ultrasound can be performed to further clarify the diagnosis of liver metastases, especially metastases that cannot be visualized by CT after chemotherapy [22].

PET/CT can be used to detect potential metastases when there is clinical suspicion of metastasis that cannot be confirmed by other imaging examinations, or before major treatment decisions are made (e.g., when there is

a possibility of curative treatment in recurrent metastatic patients), thus helping to avoid overtreatment [23]. However, PET/CT is not recommended as a routine test for the diagnosis of colorectal cancer.

2.2.2. Diagnosis methods for rectal cancer

Purpose	Grade I recommendations	Grade II recommendations	Grade III recommendations
Diagnosis	<ul style="list-style-type: none"> • Full colonoscopy + biopsy^a • Digital rectal exam^b 	<ul style="list-style-type: none"> • Sigmoidoscopy + biopsy • Transanal mass biopsy • Non-contrast and contrast-enhanced pelvic CT^c 	None
Staging diagnosis - primary tumor (for colonoscopically confirmed patients)	<ul style="list-style-type: none"> • High-resolution pelvic MRI^d • Transrectal ultrasound^d 	Non-contrast and contrast-enhanced pelvic CT ^e	None
Staging diagnosis - distant metastasis tumor (for colonoscopically confirmed patients)	Non-contrast or contrast-enhanced chest CT plus contrast-enhanced abdominal/pelvic CT ^f	<ul style="list-style-type: none"> • Non-contrast chest CT and contrast-enhanced abdominal/pelvic MRI^{g,h} • Serum CEA • CA199 	<ul style="list-style-type: none"> • Chest X-ray • Abdominal/pelvic US^h

(Continues)

Purpose	Grade I recommendations	Grade II recommendations	Grade III recommendations
Staging diagnosis (for patients with liver metastases that cannot be confirmed by CT)	Non-contrast and contrast-enhanced upper abdominal MRI ⁱ	Hepatocyte-specific contrast-enhanced upper abdominal MRI ⁱ	Contrast-enhanced upper abdominal ultrasound ^j

Abbreviations: CA199, carbohydrate antigen 199; CEA, carcinoembryonic antigen; CT, computed tomography; MRI, magnetic resonance imaging; US, ultrasound.

^aColonoscopy is generally prohibited in patients with clinically evident intestinal obstruction, as bowel preparation before the examination may exacerbate the obstruction or cause perforation.

^bAlthough it cannot serve as diagnostic evidence, it's emphasized that clinicians should perform digital rectal exams on all patients with suspected rectal cancer.

^cFor patients who are not eligible, who refuse a full colonoscopy, or whose colonoscopy cannot examine the entire colon, it is recommended to perform a contrast-enhanced abdominal/pelvic CT scan after bowel cleansing.

^dHigh-resolution pelvic MRI is the optimal imaging method for diagnosing rectal cancer with cT3 and higher stages, cN stages, mesorectal fascia, extramural vascular invasion, and anal canal structures [24]. Both rectal endoscopic ultrasound and MRI are superior to CT for cT staging of rectal cancer, and rectal endoscopic ultrasound is better than MRI in the diagnosis of cT2 and lower-stage disease [25].

^eWhen patients have contraindications for MRI scanning, non-contrast and contrast-enhanced pelvic CT is recommended.

^fContrast-enhanced chest CT is recommended for diagnosis and differential diagnosis of metastatic lymph nodes. Continuous thin-section axial, coronal, and sagittal reconstructed images are recommended for diagnosis and differential diagnosis of pulmonary metastases from colorectal cancer wherever possible [19]. Enhanced abdominal and pelvic CT is recommended for diagnosis of ovarian metastases and peritoneal metastases.

^gFor patients with contraindications to venous contrast, it is recommended to perform contrast-enhanced abdominal/pelvic MRI plus non-contrast-enhanced chest CT.

^hWhen the diagnosis of ovarian metastasis cannot be confirmed by CT, pelvic MRI or gynecologic ultrasound is recommended to support the diagnosis, and MRI is recommended to include T2-weighted imaging (T2WI), diffusion-weighted imaging (DWI), and multi-phase T1-weighted enhanced imaging sequences [20].

ⁱWhen the diagnosis of liver metastases cannot be confirmed by CT or when treatment decisions for liver metastases need to be changed, liver MRI including T2WI, DWI, and multi-phase T1-weighted enhanced imaging sequences is recommended to determine the number, size, and distribution of liver metastases. Eligible patients may directly choose liver-specific contrast agent-enhanced MRI, which is more helpful in detecting lesions smaller than 1 cm, especially metastases that cannot be visualized by CT after chemotherapy [21, 22].

^jFor eligible patients, contrast-enhanced liver ultrasound or contrast-enhanced intraoperative ultrasound can be performed to further clarify the diagnosis of liver metastases, especially metastases that cannot be visualized by CT after chemotherapy [22].

PET/CT can be used to detect potential metastases when there is clinical suspicion of metastasis that cannot be confirmed by other imaging examinations, or before major treatment decisions are made (e.g., when there is

a possibility of curative treatment in recurrent metastatic patients), thus helping to avoid overtreatment [23]. However, PET/CT is not recommended as a routine test for the diagnosis of colorectal cancer.

2.2.3. Diagnosis methods for rectal-anal cancer

2.2.3.1. Content of rectal-anal cancer imaging diagnosis

Item	Descriptions
Rectal cancer location [24, 26, 27]	The distance from the tumor's lower edge to the lower edge of the external anal sphincter and the puborectal muscle's lower edge line; the tumor's quadrant (clockwise) location ^{a,b} .
Clinical T staging (cT) of rectal cancer [27, 28]	T1: Tumor invades the mucosa and submucosa. T2: Tumor invades but does not penetrate the muscularis propria. T3: Tumor penetrates the muscularis propria but does not invade the visceral peritoneum. T3 substaging based on the vertical distance between tumor invasion into the mesorectal part and the muscularis propria: T3a (<1 mm), T3b (1-5 mm), T3c (6-15 mm), T3d (>15 mm). T4a: Tumor invades the visceral peritoneum ^c . T4b: Tumor invades adjacent organs or structures outside the mesorectal fascia but not solely the visceral peritoneum ^d .
Clinical N staging (cN) of rectal cancer [28]	For lymph nodes with a short-axis diameter ≥ 5 mm, irregular morphology, unclear boundaries, and heterogeneous signals/echoes are recommended to be considered while diagnosing metastatic lymph nodes ^e .

(Continues)

Item	Descriptions
Imaging diagnosis of lateral lymph node metastasis in rectal cancer [29, 30]	Lateral lymph nodes include the internal iliac lymph nodes, obturator lymph nodes, and external iliac lymph nodes. A short-axis diameter ≥ 5 mm and < 10 mm is the threshold for suspected diagnosis of lateral lymph node metastasis, while a short-axis diameter ≥ 10 mm is the threshold for confirmed diagnosis of lateral lymph node metastasis. After neoadjuvant therapy, there is no widely accepted threshold for diagnosing tumor residue, and the treatment plan for lateral lymph nodes needs to be determined after MDT discussion ^f
EMVI [31]	After rectal cancer invades through the muscularis propria, it invades surrounding blood vessels and forms cancer emboli, known as EMVI. MRI tracks the blood vessels around the rectum, and EMVI is diagnosed based on the irregular vascular morphology with partial or complete replacement of vascular flow signals by tumor signals ^g
Imaging diagnosis of rectal cancer involving the MRF [24, 27, 28]	The distance from the primary tumor, metastatic lymph nodes within the mesorectum, and EMVI to the MRF is ≤ 1 mm ^h
Imaging diagnosis of a safe surgical resection plane [24, 27, 32]	The safe surgical resection plane is determined based on the tumor's location, including the primary tumor, metastatic lymph nodes within the mesorectum, and EMVI invading to or protruding from the MRF, levator ani muscle, puborectal muscle, internal anal sphincter, intersphincteric space between the internal and external sphincters, or external anal sphincter ⁱ .

Abbreviations: cT, clinical T staging; cN, clinical N staging; EMVI, extramural vascular invasion; MRI, magnetic resonance imaging; MRF, mesorectal fascia; MDT, multidisciplinary team.

^aTo date, there is no uniform definition of the rectum. Different specialties may adopt different definitions for clinical purposes. For example, according to the 2nd edition of the 2018 National Comprehensive Cancer Network (NCCN) Guidelines, the rectum is defined as the area below the line connecting the sacral promontory and the upper edge of the pubic symphysis on mid-sagittal MRI [32, 33].

^bThe location of rectal cancer is closely related to risk stratification, treatment decisions, and surgical approaches. Given its close association with the pathological circumferential resection margin, radiologists are recommended to annotate the distance between rectal cancer and the puborectal muscle, and the involved quadrant, especially the anterior 1/4 quadrant (clockwise from 10 o'clock to 2 o'clock).

^cRectal cancer at cT4a stage: Rectal cancer invading the visceral peritoneum with a distance to the MRF of > 1 mm is diagnosed as T4aMRF⁻. Rectal cancer invading the visceral peritoneum with a distance to the MRF of ≤ 1 mm or invading the MRF is diagnosed as T4aMRF⁺ [27].

^dRectal cancer at cT4b stage: Rectal cancer invades pelvic organs and structures. The invaded pelvic organs include the ureters, bladder, urethra, prostate gland, seminal vesicle, cervix, vagina, ovaries, small intestine, and colon. The invaded structures include direct invasion rather than hematogenous metastasis to the pelvic bones, pelvic floor muscles (coccygeus muscle, piriformis muscle, levator ani muscle, anal sphincter muscle, puborectalis muscle, external anal sphincter, etc), pelvic floor nerves, sacrococcygeal ligaments or sacral cornua, extramural rectal vessels, fat, and other structures.

^eRectal cancer at cN stage: The evidence for clinical diagnosis of lymph node metastasis includes short-axis diameter ≥ 5 mm, irregular morphology, unclear boundaries, and heterogeneous signals or echoes. Regional lymph node metastases including mesorectal, distal sigmoid mesentery, para-rectal vessel, and internal iliac lymph nodes will be reported as cN stage. Non-regional lymph node metastases including external iliac, common iliac, obturator, and inguinal lymph nodes will be reported as cM stage. If rectal cancer extends downward to the dentate line (puborectal muscle), inguinal lymph nodes are considered regional lymph node metastases, and it will be reported as cN stage. Radiologists are recommended to label the lymph node locations.

^fLateral lymph nodes: Lower rectal cancer or cT3-4 are considered high-risk factors for lateral lymph node metastasis. Before neoadjuvant therapy, a short-axis diameter ≥ 7 mm is suggested as the diagnostic threshold for lateral lymph node metastasis. After neoadjuvant therapy, a significant reduction or disappearance of lateral lymph nodes indicates a low probability of tumor residue. Lateral lymph node recurrence is considered at a high risk if the inguinal lymph node is ≥ 4 mm or the obturator lymph node is ≥ 6 mm after neoadjuvant therapy [29].

^gTumor deposit (TD): A study has proposed imaging diagnostic criteria for TD, including irregular morphology, spiculated protrusions, heterogeneous signals or echoes, location in the vascular course area, and no direct connection to the primary lesion of rectal cancer [34]. TD is associated with the prognosis of rectal cancer patients and requires close attention. However, there are difficulties in differential imaging diagnosis between TD and lymph nodes completely invaded by tumors.

^hMRF: When the distance from the primary lesion of rectal cancer, metastatic lymph nodes within the mesorectum, and EMVI to the MRF is ≤ 1 mm, and without visceral peritoneum invasion, it is diagnosed as T3MRF⁺. When the primary lesion of rectal cancer invades structures beyond the MRF, it is diagnosed as T4b. When TD can be clearly diagnosed by imaging and the distance between the TD and the MRF is ≤ 1 mm, it is diagnosed as MRF⁺.

ⁱSafe surgical resection plane: High-resolution MRI scanning is required before surgery to determine the anatomical planes involved in rectal cancer or tumor tissue, including MRF, internal anal sphincter, intersphincteric space between the internal and external sphincters, external anal sphincter, puborectalis muscle, and levator ani muscle. Radiologists are recommended to label MRF^{+/-} in the visible MRF area. Radiologists are recommended to assess and annotate the anatomical layers affected by lower rectal or anal canal cancer based on coronal images parallel to the anal canal. If cancer involves the internal sphincter, intersphincteric space between the internal and external sphincters, and/or the external sphincter, it should be recorded as "anal⁺" [27, 35].

2.2.3.2. Imaging diagnosis for assessing the therapeutic effect of chemoradiotherapy in rectal-anal cancer

Items	Descriptions
Imaging methods for assessing the efficacy of chemoradiotherapy in rectal cancer [24, 27, 36, 37]	It is recommended to use axial small FOV high-resolution T2WI non-fat-suppressed sequences, DWI sequences, pre- and post-chemoradiotherapy ADC values, and changes in ADC values as the main methods and quantitative indicators for evaluating the efficacy of rectal cancer treatment ^a . The accuracy of evaluating the efficacy of rectal cancer treatment using a combined clinical, imaging and pathological model has been continuously confirmed, however, high-level evidence, and software and hardware development are still needed to support its clinical application.
Time interval between neoadjuvant chemoradiotherapy and imaging examination [38]	To avoid interference from bowel wall and perienteric inflammatory edema during imaging evaluation after neoadjuvant treatment, 6-8 weeks interval between neoadjuvant chemoradiotherapy and imaging examination is recommended for rectal cancer. Depending on the treatment regimen and objectives, it is recommended to extend the monitoring time points beyond 8 weeks ^b .
Baseline imaging characteristics of rectal cancer [24, 27, 36, 39]	Before chemoradiotherapy for rectal cancer, baseline cT and cN staging, EMVI, tumor diameter or volume ^c , DWI showing high tumor signal, and ADC value are important reference indicators for evaluating treatment efficacy.
Imaging characteristics of rectal cancer after chemoradiotherapy [24, 27, 36, 39, 40]	Manifestations of rectal cancer, intramesorectal lymph node metastases and EMVI regression include partial or complete replacement of tumor tissue with fibrous tissue or mucus ^d , changes in tumor diameter or volume, and changes in ADC values. These manifestations can be used as the basis for evaluating treatment efficacy.
Imaging basis for diagnosing cCR of rectal cancer after chemoradiotherapy [24, 27, 39-41] ^e	It is recommended to compare the MRI results before and after treatment. When post-treatment high-resolution T2WI non-fat-suppressed and DWI sequences show no tumor signals, and there is no clear difference in ADC values between the original tumor area and the surrounding bowel wall, these MRI features may serve as one of the criteria for diagnosing cCR. When diagnosing cCR with MRI is challenging, PET/CT can be used as an adjunct diagnostic tool.

Abbreviations: ADC, apparent diffusion coefficient; cCR, clinical complete response; cN, clinical N staging; cT, clinical T staging; DWI, diffusion-weighted imaging; EMVI, extramural vascular invasion; FOV, field-of-view; MRI, magnetic resonance imaging; PET/CT, positron emission tomography/computed tomography, T2WI, T2-weighted imaging.

^aIt is recommended to maintain consistent pelvic MRI scan parameters and angles before and after rectal cancer treatment. Rectal cleansing and injection of an appropriate amount of ultrasound gel can be performed before the examination.

^bDepending on the therapy differences of total neoadjuvant therapy (TNT), consolidation chemotherapy, and immunotherapy, it is recommended to increase the interval between the end of chemoradiotherapy and surgery by an additional 6-12 weeks beyond the initial 8 weeks.

^cIt is recommended that the maximum length and maximum thickness of the tumor be measured in conjunction with multi-angle scans. The tumor area containing only the tumor should be delineated layer by layer along the tumor axis, and the volume should be calculated thereafter.

^dIn T2WI non-fat-suppressed and DWI sequences, the presence of a mixed tumor and fibrous signals in the original tumor area and EMVI indicates incomplete remission. An incomplete remission is also indicated if the short axis of metastatic lymph nodes remains ≥ 5 mm. The presence of mucinous components in the original tumor lesion, EMVI, and lymph nodes may make it difficult to distinguish from the tumor.

^eThe MRI characteristics for diagnosing clinical complete response (cCR) are not universally agreed upon. However, the absence of tumor signals or only residual fibrous tissue in the original tumor lesion and EMVI on T2WI non-fat-suppressed and DWI sequences, as well as the disappearance of original lymph nodes or a short axis smaller than 5 mm, are characteristics used in the diagnosis of cCR in the majority of studies.

2.2.3.3. Recommendations of contents and conclusions in structured reports for rectal cancer or anal cancer

1. Contents of the pre-chemoradiotherapy report: Distance from the tumor's lower margin to the lower margin of the external sphincter muscle and the lower margin of the levator ani muscle, tumor quadrant; tumor infiltration depth and its relative relationship with surrounding structures and organs; location, size, and the number of regional lymph nodes; EMVI score; MRF[±] or anal^{+/-}; size and the number of lateral lymph nodes; location, size, and the number of non-regional lymph nodes; distant metastasis status such as

liver, peritoneal seeding, lung metastasis, etc.; relevant vascular and intestinal anatomical variations, etc.

2. Conclusions of the pre-chemoradiotherapy report: Rectal cancer cT staging; cN staging; EMVI^{+/-}; MRF^{+/-}; anal^{+/-}; lateral lymph nodes^{+/-}; non-regional lymph node metastasis should be reported.
3. Contents of the post-chemoradiotherapy report: Distance from the remaining tumor's lower margin to the lower margin of the external sphincter muscle and the lower margin of the levator ani muscle; quadrant where the remaining tumor is located; remaining tumor infiltration depth and its relative relationship with surrounding structures and organs; changes in the location, size, and the number of regional lymph

node metastases; EMVI score; persistence of MRF^{+/-} or anal^{+/-}; changes in the location, size, and the number of lateral lymph nodes; changes in the location, size, and the number of non-regional lymph node metastases; distant metastases status such as liver, peritoneal seeding, lung metastasis, etc.; relevant vascular and intestinal anatomical variations, etc.

4. Conclusions of the post-chemoradiotherapy report: Rectal cancer ymrcT staging; ymrcN staging; ymrEMVI, ymrMRF, ymranal, and the lateral lymph nodes remain positive/remission to negative/persistently negative; (changes in non-regional lymph nodes should be reported).

2.3. Principles of pathological diagnosis

Items	Grade I recommendations			Grade II recommendations	Grade III recommendations
	Gross examinations	Microscopic examinations	Immunohistochemistry/ Molecular pathology testings		
Biopsy ^a (including endoscopic biopsy or tumor puncture biopsy)	Tissue size and numbers	<ul style="list-style-type: none"> Clarify the nature and type of lesions Tumor/non-tumor Benign/malignant Histological type Histological grade 	Mismatch repair (MMR) protein expression ^b /MSI ^c	Immunohistochemical biomarker detection for differential diagnosis ^d	None
Adenoma local excision specimen ^{a,e} (Snare excision/endoscopic mucosal resection/endoscopic submucosal dissection)	<ul style="list-style-type: none"> Tumor size Pedunculated/non-pedunculated 	<ul style="list-style-type: none"> Adenoma type Dysplasia/intraepithelial neoplasia grade (high-grade/low-grade) When accompanied by invasive carcinoma^f: Histological type Histological grade Depth of invasion Lateral margin and basal margin Vascular invasion Tumor budding^g 	MMR protein expression ^b /MSI ^c	Immunohistochemical biomarker detection for differential diagnosis ^d	None
Radical surgery Specimen ^{a,h}	<ul style="list-style-type: none"> Specimen type Tumor location Length of bowel segment Macroscopic tumor type Tumor size Distance from tumor to both surgical margins Presence of perforation Integrity of TME specimen mesorectumi Number, size, and grouping of detected lymph nodesj 	<ul style="list-style-type: none"> Histological type^k Histological grade^l Depth of invasion Vascular invasion Perineural invasion Both margins Circumferential margin^m Number of lymph node metastases and total number Number of tumor deposits Tumor budding^g TNM stageⁿ Tumor regression grade (TRG)^o 	MMR protein expression ^b /MSI ^c	<ul style="list-style-type: none"> Immunohistochemical marker detection for differential diagnosis^d RAS and BRAF gene mutation testing^{p,q} 	None
Metastatic colorectal cancer surgery/biopsy specimen	Same as above	Same as above	<ul style="list-style-type: none"> MMR protein expression^b/MSI^c RAS and BRAF gene mutation testing^{p,q} 	None	<ul style="list-style-type: none"> HER-2 status NTRK fusion POLE/POLD1 gene mutation testing^f

Abbreviations: BRAF, v-raf murine sarcoma viral oncogene homolog B; HER-2, human epidermal growth factor receptor; MMR, mismatch repair; MRI, magnetic resonance imaging; MSI, microsatellite instability; NTRK, neurotrophic tyrosine receptor kinase; POLD1, DNA polymerase delta 1; POLE, DNA polymerase epsilon; RAS, rat sarcoma virus; TME, total mesorectal excision; TNM, tumour, node, and metastasis; TRG, tumor regression grade.

^aAll specimens should be fixed within 30 minutes post-removal in fresh 3.7% neutral buffered formalin. The fixative volume should be 10 times the tissue volume, and the fixation duration should be between 8-48 hours.

^bMismatch repair (MMR) protein detection: The immunohistochemical detects the expression of four common MMR proteins (mutL homolog 1[MLH1], mutS homolog 2 [MSH2], mutS homolog 6 [MSH6], and postmeiotic segregation increased 2 [PMS2]), with positive expression located in the cell nucleus. Loss of expression of any one protein indicates deficient MMR (dMMR), while positive expression of all four proteins indicates proficient MMR (pMMR).

^cMicrosatellite (MSI) detection: Commonly used detection panels include the National Cancer Institute (NCI) Panels (BAT-25, BAT-26, D5S346, D17S250, D2S123) consisting of two mononucleotide repeat sites and three dinucleotide repeat sites, and the Promega Panel (BAT-25, BAT-26, NR-21, NR-24, MONO-27) consisting of five mononucleotide repeat sites. The definition criteria are as follows: stabilities at all five sites are microsatellite stable (MSS), instability at one site is microsatellite instability-low (MSI-L), and

instabilities at two or more sites are microsatellite instability-high (MSI-H). MSI is mostly caused by mutations and functional deficiencies in MMR genes, and MSI status can also be assessed by detecting MMR protein loss. Generally, dMMR is equivalent to MSI-H, and pMMR is equivalent to MSI-L or MSS. The dMMR/MSI-H colorectal cancer treatment has specific characteristics.

^dSelect appropriate immunohistochemical biomarkers for differential diagnosis. The typical immunophenotype of colorectal adenocarcinoma is cytokeratin (CK) 7⁻/CK20⁺/caudal type homeobox (CDX) 2⁺.

^eFor optimal fixation, specimens should be fully extended by endoscopists or surgeons, with the mucosal surface facing upward. They should be pinned at the edges on cork or foam boards. Tissue should be cut vertically to the mucosal surface at intervals of 2-3 mm.

^fAdenomas with an invasive cancer is an adenoma containing adenocarcinoma that penetrates the muscular layer of the mucosa and infiltrates into the submucosa (pT1). Adenomas with high-grade intraepithelial neoplasia include adenomas with severe dysplasia, carcinoma in situ, and intramucosal carcinoma. Adverse prognostic factors include high-grade adenocarcinoma, tumor distance less than 1 mm from the margin, vascular invasion, and high-grade (Grade 3) tumor budding [42].

^gTumor budding is the scattered single tumor cells or clusters (≤ 4 of tumor cells) at the invasion front. Previous studies have shown that tumor budding is a prognostic indicator for stage II colorectal cancer [43-45]. In pT1 colorectal cancer, high-grade tumor budding is associated with an increased risk of lymph node metastasis [46]. The 2016 International Consensus on Tumor Budding in Colorectal Cancer (ITBCC), published in 2017, has been widely recognized, and it can be used as a reference for grading and reporting colorectal cancer tumor budding. Tumor budding is graded on a three-level scale, specifically as follows: a hot spot area is selected for budding counting under a 20 \times objective lens (0.785 mm), with 0-4 being Grade 1 (low-grade), with 5-9 being Grade 2 (general-grade), and with ≥ 10 being Grade 3 (high-grade) [47].

^hRadical surgery specimens are typically opened along the opposite side of the tumor and fixed, and board fixation is recommended.

ⁱThe integrity assessment criteria of total mesorectal excision (TME) for rectal cancer specimens can be found in “2.3.1 Appendix to principles of pathological diagnosis: Criteria for assessing mesorectal integrity” [48, 49].

^jLymph nodes should be sampled and grouped according to the direction of lymphatic drainage (paracolic, intermediate, central). In radical surgery specimens without adjuvant treatment, the total number of detected lymph nodes should generally be no less than 12. If fewer than 12 lymph nodes are found initially, a re-examination is recommended.

^kColorectal cancer histological subtypes refer to the World Health Organization (WHO) Classification of Tumors of the Digestive System, 2019 edition [50].

^lHistological grading includes the traditional 4-grade system and the 2-grade system of the WHO classification, based on the degree of differentiation (see “2.3.2. Appendix to principles of pathological diagnosis: Relationship between histological grades and histological types”).

^mThe circumferential margin, or “basal” margin, is the part of the intestinal wall not covered by the peritoneum. Surgeons are recommended to stain or mark it, with a positive circumferential margin defined as ≤ 1 mm between the tumor and margin [51].

ⁿPathological Tumor Node Metastasis (pTNM) Staging adopts the American Joint Committee on Cancer (AJCC)/the Union for International Cancer Control (UICC) 8th edition [52], edition.

^pRat sarcoma virus (*RAS*) and v-raf murine sarcoma viral oncogene homolog B (*BRAF*) gene mutation testing: Detection sites include the 2nd, 3rd, and 4th exons of the kirsten rat sarcoma viral oncogene homolog (*KRAS*) and neuroblastoma RAS viral oncogene homolog (*NRAS*) genes, and the V600E mutation of the *BRAF* gene. Considering the good consistency of *RAS* and *BRAF* gene status between primary and metastatic colorectal cancer lesions, both primary and metastatic lesions can be tested based on sample availability [53]. While there is inconsistency in treatment response between primary and metastatic lesions, tests are recommended for both primary and metastatic lesions. In addition to predicting efficacy in metastatic colorectal cancer [54, 55], *RAS* and *BRAF* gene status also have prognostic implications for colorectal cancer patients [52, 56-58].

^qGene mutation testing can be performed using DNA direct sequencing or amplification-refractory mutation system (ARMS) method. For *KRAS* mutation testing, in addition to the 2nd, 3rd, and 4th exons, attention should be paid to whether the detection method covers other important gene mutation regions and types (such as G12C and G12D mutation). If the ARMS detects positive results covering G12C and G12D mutations, further clarification of the mutation type should be performed using single-tube allele-specific ARMS or Sanger sequencing to better guide subsequent treatment. High-throughput sequencing technology, also known as next-generation sequencing technology (NGS), which has higher throughput and faster speed, is gradually being used in clinical genetic testing. Using certified NGS technology platforms and testing products, along with strict quality control and standardized operating procedures, is necessary to ensure the accuracy of the test results [59, 60]. It is recommended to clearly state the gene status (wild-type, mutant, or suspicious) in the gene testing report. It is recommended to use 5% as the cutoff of a mutation abundance when using quantitative detection methods such as NGS to detect *RAS* and *BRAF* gene mutations [52, 61].

^rThe use of anti-human epidermal growth factor receptor (HER)-2 therapy, neurotrophic tyrosine receptor kinase (NTRK) inhibitors, and immune checkpoint inhibitors is increasingly emphasized in the treatment of colorectal cancer. If possible, colorectal cancer patients who fail standard treatment can undergo testing for HER-2 status, *NTRK* gene fusion, and DNA polymerase delta 1/DNA polymerase epsilon (*POLE/POLD1*) gene mutations. The method for HER-2 status detection in colorectal cancer can employ immunohistochemistry and fluorescence in situ hybridization (FISH), which is similar to that used for breast cancer and gastric cancer. Currently, the criteria for determining HER-2 positivity in colorectal cancer are solely based on clinical studies, and an authoritative institution-certified diagnostic interpretation standard has not yet been established. In a positive clinical study, the definition of immunohistochemistry (IHC) HER-2 positivity includes more than 50% of tumor cells exhibiting 3+ positivity (strong membranous staining at the base and lateral sides or entire membrane); patients with an HER-2 score of 2+ should undergo further FISH testing to clarify the HER-2 status, where a HER-2 gene amplification was defined as an HER-2/(centromere protein) CEP17 ratio > 2.0 in more than 50% of tumor cells [62]. *NTRK* gene fusion is extremely rare in colorectal cancer, with an incidence of approximately 0.35%. It is limited to *RAS* and *BRAF* wild-type colorectal cancer, and the vast majority of cases occur in dMMR/MSI-H colorectal cancer. Several methods are available for detecting *NTRK* gene fusion, with IHC staining serving as a rapid and economical screening method. However, the verification of *NTRK* gene fusion requires more definitive techniques, such as FISH or NGS [63, 64]. The *POLE/POLD1* genes are associated with DNA synthesis and damage response. Mutations occurring in the DNA polymerase domains of the *POLE/POLD1* protein result in tumor hypermutation [65]. This functional mutation increases both the quantity and quality of immunogenic mutations in tumors, activates and enhances T cell response, improves the tumor immune microenvironment, and consequently leads to better prognosis and greater sensitivity to immunotherapy [66, 67]. Two percent to 8% of MSS/pMMR colorectal cancer harbor somatic *POLE* functional mutations, while *POLD1* mutations are extremely rare [65]. Single-gene sequencing can be used for *POLE/POLD1* mutation detection. However, large-panel NGS can not only detect genetic alterations, including *POLE/POLD1*, but also obtain tumor mutation burden (TMB) data. Using certified NGS technology platforms and detecting products, along with strict quality control and standardized operating procedures, is necessary to ensure the accuracy of the test results.

Circulating tumor DNA (ctDNA) testing plays an important role in predicting recurrence risk [68], evaluating minimal residual disease (MRD), and providing earlier indications of tumor recurrence [69, 70], thus playing a vital role in enabling more precise risk stratification in stage II colon cancer patients to guide the use of chemotherapy and other treatments [71]. The mainstream ctDNA testing technologies currently include two approaches: tumor-informed (customized panel) and tumor-agnostic (fixed panel). Tumor-informed ctDNA testing involves whole-exome

sequencing of tumor tissue for personalized detection, followed by amplification and ultra-high-depth sequencing; it provides high sensitivity and accuracy, though at a higher cost and with limited detection of new mutations or secondary resistant mutations. Tumor-agnostic ctDNA testing uses panel-fixed plasma testing, covering relatively more sites and achieving medium to high-depth sequencing, offering wider applicability at relatively lower costs but lower sensitivity. Only clinically validated ctDNA testing methods should be applied in practice.

2.3.1. Appendix to principles of pathological diagnosis: Criteria for assessing mesorectal integrity

Integrity	Mesorectum	Defect	Cone-shaped	Circumferential margin
Intact	Intact mesorectal tissue, smooth	Depth ≤ 5 mm	None	Smooth, regular
Relatively intact	Moderately bulky mesorectal tissue, irregular	Depth > 5 mm but not reaching the muscular layer	Not apparent	Irregular
Not intact	Small pieces of mesorectal tissue	Reaching the muscular layer	Yes	Irregular

2.3.2. Appendix to principles of pathological diagnosis: Relationship between histological grades and histological types

Histological grades			Histological types
2-grade system	4-grade system		
Low grade	Grade 1	Well-differentiated adenocarcinoma	
	Grade 2	Moderately-differentiated adenocarcinoma	
High grade	Grade 3	Poorly-differentiated adenocarcinoma	
	Grade 4		

3. Principles for colon cancer treatment

3.1. Treatments for non-metastatic colon cancer

3.1.1. Treatments for resectable colon cancer

3.1.1.1. Endoscopic treatments

3.1.1.1.1. Endoscopic treatment strategies

For colon adenomas or certain T1-stage colon adenocarcinomas, endoscopic treatment can be considered.

Stages	Stratifications	Grade I recommendations	Grade II recommendations	Grade III recommendations
Adenomas and T1N0 colorectal cancer ^{a,b,c,d}	Pedunculated polyps or non-pedunculated polyps with a diameter of 5-20 mm	Snare polypectomy ^a	EMR	None
	1. Flat lesions of 5-20 mm 2. Sessile lesions of > 10 mm suspected to be villous adenomas or sessile serrated adenomas/polyps 3. Suspected high-grade intraepithelial neoplasia of ≤ 20 mm, expected to be completely resected	EMR	ESD	None
	Mucosal or submucosal adenomas of > 20 mm [72]	PEMR ^e	ESD	None
	1. Partial colon cancer of T1 stage (submucosal invasion < 1 mm); 2. Lateral spreading tumors of ≥ 20 mm; 3. Colon polyps with fibrosis [73–75], villous adenomas of ≥ 25 mm	ESD	Surgical treatment ^f	None

Abbreviations: EMR, endoscopic mucosal resection; ESD, endoscopic submucosal dissection; PEMR, piecemeal endoscopic mucosal resection; T, primary tumor; N, regional lymph nodes.

^aFor all non-pedunculated polyps or those suspected of malignancy, it is recommended to decide on endoscopic resection only after definitive pathology confirmation. Various special endoscopic examination methods aid in determining the benign or malignant nature of polyps.

^bThe risk of regional lymph node metastasis in T1-stage cancer is approximately 15%, and local resection under endoscopy cannot determine lymph node status. After endoscopic treatment for partial colon cancer of T1 stage (submucosal invasion <1 mm), not only a local colonoscopy examination is required, but also tumor marker carcinoembryonic antigen (CEA) testing, abdominal ultrasound, chest and abdominal CT scans [76].

^cHistological criteria for assessing curative endoscopic resection of T₁ colon cancer: 1) lesions with submucosal invasion <1 mm; 2) absence of lymph vascular invasion; 3) well-differentiated tumors; 4) no tumor budding; 5) the distance of tumor to the margin ≥1 mm [72, 77].

^dWhen there is uncertainty about whether the margin is negative or positive, an endoscopic re-examine is recommended within 3 to 6 months. If the margin is negative, a follow-up endoscopy can be performed within 1 year after endoscopic treatment [73, 74].

^eLarger lesions may require piecemeal endoscopic mucosal resection (PEMR). However, PEMR has a higher local recurrence rate and requires enhanced monitoring [75].

^fRefer to section “3.1.1.2 Surgical treatment” for further details.

3.1.1.1.2. Management strategies after endoscopic resection of polyps

Pathological stages ^a	Stratifications	Grade I recommendations	Grade II recommendations	Grade III recommendations
High-grade intraepithelial neoplasia	None	Observation	None	None
pT1N0M0 pedunculated polyp with cancer infiltration	Favourable prognosis ^b	Observation	None	None
pT1N0M0 sessile polyp with cancer infiltration		Observation ^c	Colon resection + regional lymph node dissection ^d	None
pT1N0M0 pedunculated or sessile polyp with cancer infiltration	Poor prognosis ^e	Colon resection + regional lymph node dissection ^{d,f}	None	Observation ^c

Abbreviations: pTNM, pathological tumor node metastasis staging.

^aSee “2.3 Principles of pathological diagnosis” for details.

^bA favorable prognosis is determined when all the following criteria are met [78]: complete specimen excision, negative margins, and histological features indicating a favorable prognosis (low grade, no vascular or lymphatic invasion).

^cPatients should be informed that the rate of adverse events significantly increases with sessile adenomatous polyps, including disease recurrence, mortality, and hematogenous spread. The risk is primarily associated with positive margins after endoscopic resection [79–82].

^dAll local resections or colectomies can be performed by either traditional open surgery or minimally invasive approaches such as laparoscopy or robotic surgery, depending on the availability of local technology and equipment.

^eA poor prognosis is determined when any of the following criteria are met [78]: specimen fragmentation, margins unable to be evaluated or positive (presence of tumor within 1 mm of margin or tumor cells visible at electrosurgical margin [78, 83, 84]), and histological features indicating a poor prognosis (high grade, vascular or lymphatic invasion). Additionally, it was reported that TD in pT1 colorectal cancer is associated with an increased risk of lymph node metastasis (see reference [46]).

^fPatients with poor prognosis are advised to undergo colon resection and regional lymph node dissection [78, 85, 86].

3.1.1.2. Surgical treatment

Clinical stages	Stratifications	Grade I recommendations	Grade II recommendations	Grade III recommendations
cT1-4N0-2M0, stage I-III, without symptoms requiring emergency treatment	None	Colon resection + regional lymph node dissection ^a	For cT4b dMMR/MSI-H patients, consider preoperative treatment with immune checkpoint inhibitors (PD-1 monoclonal antibody ± CTLA-4 monoclonal antibody) [87, 88], followed by radical surgery ^a .	None

(Continues)

Clinical stages	Stratifications	Grade I recommendations	Grade II recommendations	Grade III recommendations
cT1-4N0-2M0, stage I-III, with symptoms requiring emergency treatment	Intestinal obstruction	Surgery ^{b,c}	Stent placement, stage II radical surgery ^d	None
	Perforation	Surgery ^e	None	None
	Bleeding	Colon resection ± regional lymph node dissection	<ul style="list-style-type: none"> Endoscopic or interventional embolization for hemostasis Scheduled radical surgery 	None

Abbreviations: CTLA-4, cytotoxic T-lymphocyte associated protein 4; cTNM, clinical tumor node metastasis staging; dMMR, deficient mismatch repair; MSI-H, microsatellite instability-high; PD-1, programmed cell death protein 1.

^aRadical surgery involves colon resection with complete regional lymph node dissection [89, 90]. Suspicious metastatic lymph nodes at the root of the tumor vessels and outside the dissection area should also be removed or biopsied. Only complete resection surgery can be considered radical [52, 91].

^bOptional surgical approaches include stage I resection with anastomosis, stage I resection with anastomosis + proximal protective stoma, stage I resection + proximal protective stoma + distal closure, or stage II resection after stoma.

^cLaparoscopic surgery is not recommended for patients with obstruction.

^dIntestinal stents are typically suitable for lesions in the distal colon. Their placement can decompress the proximal colon, allowing for one-stage anastomosis in cases of elective colon resection [92].

^eDepending on the degree of abdominal contamination choose the optional surgical approaches referred to note b, along with thorough irrigation and drainage.

3.1.1.3. Adjuvant chemotherapy after surgery

Pathological stages	Stratification	Grade I recommendations	Grade II recommendations	Grade III recommendations
Stage I	T1-2N0M0	Observation (Category 1A)	None	None
Stage II ^{a,b,c,d,e,f,g}	Low-risk (T3N0M0, dMMR, regardless of the presence of high-risk factors)	Observation (Category 1A)	None	None
	Average-risk (T3N0M0, pMMR without high-risk factors)	Fluoropyrimidine monotherapy ^h (Category 1A)	Observation	None
	High-risk (T3N0M0/pMMR with high-risk factors, or T4N0M0)	Combination chemotherapy regimen ⁱ (Category 1A)	Fluoropyrimidine monotherapy (restricted to pMMR patients) (Category 1B)	Observation (Category 3)
Stage III ^{e,f}	T _{any} N+M0	Combination chemotherapy regimen ⁱ (Category 1A)	Fluoropyrimidine monotherapy ^h (Category 1B)	None

Abbreviations: TNM, tumor, node, metastasis staging; dMMR, deficient mismatch repair; pMMR, proficient mismatch repair.

^aFor stage II patients: High-risk factors include T4, poorly differentiated histology (high grade, excluding MSI-H), vascular invasion, perineural invasion, preoperative bowel obstruction or tumor site perforation, positive or uncertain margins, inadequate margin distance, or less than 12 lymph nodes examined [59]; low-risk refers to MSI-H or dMMR; average-risk refers to those with neither high- nor low-risk factors.

^bBased on the findings of the Multicenter International Study of Oxaliplatin/Fluorouracil/Leucovorin in the Adjuvant Treatment of Colon Cancer (MOSAIC) trial and potential long-term sequelae after using Oxaliplatin, the FOLFOX regimen is not suitable for adjuvant therapy in stage II patients without high-risk factors [93].

^cAll stage II patients should undergo MMR testing. Detailed information is available in the section “2.3 Principles of pathological diagnosis”. Patients with dMMR or MSI-H in stage II may have a better prognosis and may not benefit from adjuvant chemotherapy with fluoropyrimidine monotherapy [94].

^dThe specific regimen for adjuvant chemotherapy should consider the conditions of patients, including age, physical status, and underlying diseases. There is no evidence to show that adding Oxaliplatin to 5-FU/LV can benefit patients aged 70 or older [93].

^eAdjuvant chemotherapy should be initiated as soon as possible after postoperative recovery. It generally starts around 3 weeks and no later than 2 months postoperatively. The total duration of adjuvant chemotherapy is 6 months. Based on the IDEA study results [95, 96], high-risk stage II and low-risk stage III patients (T₁₋₃N₁) may consider 3-month CAPEOX adjuvant chemotherapy.

^fExcept in clinical trials, the following drugs are not recommended for adjuvant chemotherapy, including Irinotecan, Tegafur, Trifluridine/Tipiracil (TAS-102), all targeted therapies (such as Bevacizumab, Cetuximab, Panitumumab, Afibercept, Regorafenib, Fruquintinib), and all immune checkpoint inhibitors (such as Pembrolizumab and Nivolumab).

^gThe recent DYNAMIC study suggested that the minimal residual disease (MRD) detected by ctDNA testing may change the adjuvant chemotherapy strategy of certain stage II colon cancer patients. However, there were no significant differences in survival between intervention in MRD-positive patients and observation in MRD-negative patients [71].

^hRecommended fluoropyrimidine monotherapy regimens include orally administered Capecitabine (preferred) and 5-fluorouracil/leucovorin (5-FU/LV) continuous intravenous infusion biweekly.

ⁱRecommended combination chemotherapy regimens include CAPEOX (also known as XELOX) and mFOLFOX6. Based on the IDEA study results, CAPEOX is preferred.

3.1.1.4. Common post-operative adjuvant chemotherapy regimens for colon cancer

Fluoropyrimidine-based monotherapy regimens

- [Capecitabine]
 - Capecitabine, 1,250 mg/m², orally, twice a day, days 1-14
 - Repeat every 3 weeks for 8 cycles
- [Simplified biweekly 5-FU infusion/LV regimen (sLV5FU2)]
 - LV 400 mg/m², intravenous drip for 2 hours, day 1;
 - Followed by 5-FU 400 mg/m² IV bolus, day 1, followed by 1,200 mg·m⁻²·d⁻¹ continuous intravenous infusion for 2 days (total dose 2,400 mg/m², infusion for 46-48 hours)
 - Repeat every 2 weeks for 12 cycles

Combination chemotherapy regimens

- [CAPEOX (also known as XELOX)]
 - Oxaliplatin 130 mg/m², intravenous infusion over 2 hours, day 1;
 - Capecitabine 1,000 mg/m², orally, twice a day, days 1-14;
 - Repeat every 3 weeks for 8 cycles
- [mFOLFOX6]
 - Oxaliplatin 85 mg/m², intravenous infusion over 2 hours, day 1;
 - LV 400 mg/m², intravenous infusion for 2 hours, day 1;
 - 5-FU 400 mg/m², intravenous bolus, day 1, followed by 1,200 mg·m⁻²·d⁻¹ continuous intravenous infusion over 2 days (total dose 2,400 mg/m², infusion for 46-48 hours)
 - Repeat every 2 weeks for 12 cycles

3.1.2. Treatments for unresectable colon cancer

For certain patients in T4b and M0 stages who cannot achieve curative resection with combined organ resection,

it is recommended to refer to the treatment recommendations below.

Stratifications	Grade I recommendations	Grade II recommendations	Grade III recommendations
Asymptomatic primary lesion and potentially resectable	Conversion drug therapy ^{a,b,c,d}	Concurrent chemoradiotherapy ^e	<ul style="list-style-type: none"> • Palliative treatment^{a,b,d} • Endoscopic stent implantation^f • Palliative surgical treatment
Asymptomatic primary lesion and unresectable	Palliative drug therapy ^{a,b,d} ± colostomy	<ul style="list-style-type: none"> • Concurrent chemoradiotherapy^e • Best supportive care 	<ul style="list-style-type: none"> • Endoscopic stent implantation^f • Intestinal anastomosis bypass surgery
Symptomatic primary lesion and potentially resectable	Surgery for symptom relief + conversion therapy with drugs ^{a,b,c,d}	Interventional embolization/endoscopic treatment + conversion therapy with drugs ^{a,b,c,d}	Best supportive care
Symptomatic primary lesion and unresectable	Surgery for symptom relief + palliative drug therapy ^{a,b,d}	Interventional embolization/endoscopic treatment + palliative drug therapy ^{a,b,d}	Best supportive care

Abbreviations: T, primary tumor; M, distant metastasis.

^aFor initially unresectable colon cancer, fluoropyrimidine monotherapy, combination chemotherapy with Oxaliplatin or Irinotecan, or even triple-drug combination chemotherapy, can be used based on the specific situation of the patient [97].

^bMultiple clinical studies on advanced colorectal cancer have shown that chemotherapy combined with Bevacizumab or Cetuximab can improve the prognosis of the patients [98-101], but the combination of two targeted drugs is not recommended [102, 103].

^cFor patients with the potential for conversion to resectability, a high response rate chemotherapy regimen or a combination of chemotherapy and targeted therapy is recommended. Patients should be evaluated every 2 months. In combination with Bevacizumab, the last treatment should be administered at least 6 weeks before surgery. If Bevacizumab is to be continued after surgery, treatment should be resumed 6-8 weeks postoperatively.

^dBased on the results of the KEYNOTE-177 study, patients with MSI-H/dMMR can consider using PD-1 immune checkpoint inhibitors for conversion therapy or palliative treatment [104].

^eLocal radiotherapy can improve the remission rate of treatment and increase the probability of conversion resection for certain T4b patients with locally invasive sigmoid colon cancer [105].

^fFor T4b colon cancer patients with obstruction, endoscopic stent implantation [106, 107] or bypass surgery can be performed to relieve the obstruction.

3.2. Principles for metastatic colon cancer treatment

3.2.1. Concurrent metastatic colon cancer

3.2.1.1. Treatments for initially resectable metastatic colon cancer

For resectable metastatic colon cancer, surgical resection is a potentially curative treatment option. Technical requirements include sufficient residual liver volume and R0 resection margins [108]. Patients with localized lung

metastases have relatively good prognoses, but relevant comprehensive treatment research data are limited. Therefore, it is recommended to follow the treatment principles for liver metastases after a multidisciplinary discussion. If the number of liver metastases exceeds five, please refer to the recommendation for initially unresectable colon cancer in note a of “3.1.2 Treatment of unresectable colon cancer”.

Stages	Risk stratifications	Grade I recommendations	Grade II recommendations	Grade III recommendations
Asymptomatic resectable with liver metastasis only	Low (CRS 0-2) ^a	Colon resection + simultaneous or staged ^b resection of metastatic lesions + postoperative adjuvant chemotherapy	<ul style="list-style-type: none"> • Neoadjuvant chemotherapy^c after primary lesion relief + colon resection + simultaneous or staged resection^b, radiofrequency ablation (RFA) and other local treatments^d to treat metastatic lesions + postoperative adjuvant chemotherapy • Colon resection + neoadjuvant chemotherapy^c + metastasis resection, /RFA and other local treatments^d + postoperative adjuvant chemotherapy 	Simultaneous or staged ^b colon resection and resection of metastatic lesions + postoperative observation
	High (CRS 3-5) ^a	Neoadjuvant chemotherapy ^c + colon resection + simultaneous or staged resection ^b , RFA and other local treatments ^d to treat metastatic lesions + postoperative adjuvant chemotherapy	<ul style="list-style-type: none"> • Colon resection + neoadjuvant chemotherapy^c + metastasis lesion resection, /RFA and other local treatments^d + postoperative adjuvant chemotherapy • Simultaneous or staged^b colon resection and resection of metastatic lesions^c, /RFA and other local treatments^f + postoperative adjuvant chemotherapy 	None
Symptomatic primary tumor (obstruction, bleeding, perforation) with liver metastasis only	Low (CRS 0-2) ^a	Colon resection + simultaneous or staged resection ^b of metastatic lesions + postoperative adjuvant chemotherapy	<ul style="list-style-type: none"> • Colon resection + neoadjuvant chemotherapy^c + metastasis resection, RFA and other local treatments^d + postoperative adjuvant chemotherapy • Neoadjuvant chemotherapy after symptom relief^c + colon resection + simultaneous or staged resection^b, RFA and other local treatments^d for treating metastatic lesions + postoperative adjuvant chemotherapy 	Simultaneous or staged ^b colon resection and metastasis resection, RFA and other local treatments ^d + postoperative observation
	High (CRS 3-5) ^a	Colon resection + neoadjuvant chemotherapy ^c + metastasis resection, RFA and other local treatments ^d + postoperative adjuvant chemotherapy	<ul style="list-style-type: none"> • Simultaneous or staged^b colon resection and resection of metastatic lesions^c/RFA and other local treatments^d + postoperative adjuvant chemotherapy • Neoadjuvant chemotherapy after symptom relief^c + colon resection + simultaneous or staged^b resection, RFA and other local treatments^d to treat metastatic lesions + postoperative adjuvant chemotherapy 	None

Abbreviations: CRS, clinical risk score; RFA, radiofrequency ablation.

^aThe five parameters of the Clinical Risk Score (CRS) include 1) positive lymph nodes of the primary tumor; 2) synchronous or metachronous metastases occurring within 12 months of primary tumor resection; 3) more than one liver metastatic lesions; 4) preoperative CEA level >200 ng/mL, and 5) the maximum diameter of metastatic tumor >5 cm. Each parameter scores 1 point. CRS score of 0-2 is considered as low-risk, while 3-5 is considered as high-risk. A higher CRS score indicates a greater risk of postoperative recurrence and higher benefits from perioperative chemotherapy [109, 110]. Recent studies have shown that the addition of relevant molecular biomarker test to CRS can improve its performance in predicting recurrence risk [111].

^bThe order of surgical resection for primary and metastatic lesions in synchronous metastatic colon cancer, including simultaneous or staged surgery, which mainly depends on the physical conditions of patients and comprehensive assessments of surgical tolerance and safety. The priority of resection of either the primary lesion or the metastatic lesion in staged surgery depends on the primary factors affecting the patient's survival and quality of life. If the metastatic lesions are the dominant factor, metastatic lesion resection should be performed first, followed by primary lesion resection [112].

^cNeoadjuvant chemotherapy can reduce the tumor size preoperatively and decrease the incidence of micrometastases, thereby increasing the R0 resection rate. To restrict the occurrence of drug-induced liver damage, the duration of neoadjuvant chemotherapy is generally limited to 2-3 months. The preferred neoadjuvant chemotherapy regimen is Oxaliplatin-based (FOLFOX/CAPEOX), while Irinotecan-based regimens (FOLFIRI) can be selected depending on individual circumstances.

^dLocal treatment methods include radiofrequency ablation (RFA), microwave ablation, stereotactic body radiotherapy (SBRT), and others [113].

3.2.1.2. Treatments for initially unresectable metastatic colon cancer

Stratifications	Grade I recommendations	Grade II recommendations	Grade III recommendations
Primary lesion with bleeding and perforation	Primary lesion resection, followed by systemic therapy	Primary lesion resection and local therapy aimed at alleviating symptoms for metastatic lesions	None
Primary lesion with obstruction	Local obstruction relief (colon stent placement/colostomy/primary lesion resection), followed by systemic therapy	After local obstruction relief and systemic therapy, the primary lesion should be resected at appropriate timing	After local obstruction relief, local treatments aimed at alleviating symptoms for metastatic lesions is recommended
Asymptomatic primary lesion	Systemic therapy, followed by evaluation of the possibility of local treatment (both primary and metastatic lesions)	Primary lesion resection followed by systemic therapy	Primary lesion resection, followed by local treatments aimed at alleviating symptoms for metastatic lesions

All patients with initially unresectable metastatic colon cancer who plan to receive systemic therapy can be classified into potentially resectable and palliative treatment

groups based on the potential of metastatic lesions for R0 resection. These patients should especially be managed and treated under the guidance of the MDT throughout the entire process.

3.2.1.2.1. Treatments for the potentially resectable group

Stratifications	Substratifications	Grade I recommendations	Grade II recommendations	Grade III recommendations
Suitable for intensive treatment (<i>RAS</i> and <i>BRAF</i> wild-type)	Left-sided tumors ^a	FOLFOX/FOLFIRI + Cetuximab ^a (Category 2A)	<ul style="list-style-type: none"> FOLFOX/CAPEOX/FOLFIRI ± Bevacizumab (Category 2A) FOLFOXIRI ± Bevacizumab (Category 2A) 	Other local treatments (Category 2B)
	Right-sided tumors ^a	<ul style="list-style-type: none"> FOLFOX/CAPEOX/FOLFIRI + Bevacizumab (Category 2A) FOLFOXIRI ± Bevacizumab (Category 1A) 	<ul style="list-style-type: none"> CAPEOX (Category 2A) FOLFOX/FOLFIRI ± Cetuximab^a (Category 2B) 	
Suitable for Intensive treatment (<i>RAS</i> or <i>BRAF</i> mutation)	None	<ul style="list-style-type: none"> FOLFOX/CAPEOX/FOLFIRI + Bevacizumab (Category 2A) FOLFOXIRI ± Bevacizumab (Category 1A) 	FOLFOX/CAPEOX/FOLFIRI (Category 2A)	Other local treatments (Category 2B)

Abbreviations: *BRAF*, v-raf murine sarcoma viral oncogene homolog B; CAPEOX, this chemotherapy combination contains the drugs capecitabine and oxaliplatin; FOLFOX, this chemotherapy combination contains the drugs leucovorin calcium (folinic acid), fluorouracil, and oxaliplatin; FOLFIRI, this chemotherapy combination contains the drugs leucovorin calcium (folinic acid), fluorouracil, and irinotecan hydrochloride; FOLFOXIRI, the regimen consists of oxaliplatin, irinotecan, leucovorin, 5-fluorouracil, bevacizumab; *RAS*, rat sarcoma virus.

3.2.1.2.2. The first-line treatment regimen for the palliative treatment group

Stratifications	Stratifications	Grade I recommendations	Grade II recommendations	Grade III recommendations
MSI-H/dMMR	None	Pembrolizumab ^b (Category 1A)	None	Nivolumab + Ipilimumab (Category 3) ^b
Suitable for intensive treatment (MSS or MSI-L/pMMR, RAS and BRAF wild-type)	Left-sided tumors ^a	<ul style="list-style-type: none"> FOLFOX/FOLFIRI ± Cetuximab (Category 1A) CAPEOX (Category 1A) 	<ul style="list-style-type: none"> FOLFOX/CAPEOX/FOLFIRI + Bevacizumab (Category 1A) FOLFOXIRI ± Bevacizumab (Category 1B) 	Other local treatments (Category 3)
	Right-sided tumors ^a	FOLFOX/CAPEOX/FOLFIRI ± Bevacizumab (Category 1A)	<ul style="list-style-type: none"> FOLFOXIRI ± Bevacizumab (Category 1B) FOLFOX/FOLFIRI ± Cetuximab^a (for patients with contraindications to Bevacizumab) (Category 2A) 	
Unsuitable for intensive treatment (MSS or MSI-L/pMMR, RAS and BRAF wild-type)	None	Fluoropyrimidine monotherapy ± Bevacizumab (Category 1A)	<ul style="list-style-type: none"> Monotherapy with Cetuximab^a (left-sided tumors) (Category 2B) Dose-reduced doublet chemotherapy (FOLFOX/FOLFIRI) ± Cetuximab^a (Category 2B) Dose-reduced doublet chemotherapy (FOLFOX/CAPEOX/FOLFIRI) ± Bevacizumab (Category 2B) 	<ul style="list-style-type: none"> Trifluridine/Tipiracil + Bevacizumab (Category 2B) Other local treatments (Category 3)
Suitable for intensive treatment (MSS or MSI-L/pMMR, RAS or BRAF mutation)	None	FOLFOX/CAPEOX/FOLFIRI ± Bevacizumab (Category 1A)	FOLFOXIRI ± Bevacizumab (Category 1B)	Other local treatments (Category 3)
Unsuitable for intensive treatment (MSS or MSI-L/pMMR, RAS or BRAF mutation)	None	Fluoropyrimidine monotherapy ± Bevacizumab (Category 1A)	Dose-reduced doublet chemotherapy (FOLFOX/CAPEOX/FOLFIRI) ± Bevacizumab (Category 2B)	<ul style="list-style-type: none"> Trifluridine/Tipiracil + Bevacizumab (Category 2B) Other local treatments (Category 3)

Abbreviations: *BRAF*, v-raf murine sarcoma viral oncogene homolog B; CAPEOX, this chemotherapy combination contains the drugs capecitabine and oxaliplatin; FOLFOX, this chemotherapy combination contains the drugs leucovorin calcium (folinic acid), fluorouracil, and oxaliplatin; FOLFIRI, this chemotherapy combination contains the drugs leucovorin calcium (folinic acid), fluorouracil, and irinotecan hydrochloride; FOLFOXIRI, the regimen consists of oxaliplatin, irinotecan, leucovorin, 5-fluorouracil, bevacizumab; MSI-L, microsatellite instability-low; MSS, microsatellite stable; pMMR, proficient mismatch repair; RAS, rat sarcoma virus.

3.2.1.2.3. The second-line treatment regimen for the palliative treatment group

Stratifications	Grade I recommendations	Grade II recommendations	Grade III recommendations
MSI-H/dMMR, not previously treated with immune checkpoint inhibitors in the first line	None	<ul style="list-style-type: none"> • Envafoimab, Serplulimab, Tislelizumab, or Pucotenlimab^b (Category 2A) • Pembrolizumab and Nivolumab^l (Category 2A) 	Nivolumab + Ipilimumab ^b (Category 2A)
Previously treated with Oxaliplatin in the first line (MSS or MSI-L/pMMR, RAS and BRAF wild-type)	FOLFIRI ± targeted therapy (Cetuximab ^c or Bevacizumab ^c) (Category 2A)	<ul style="list-style-type: none"> • Irinotecan ± Cetuximab^c (Category 2A) • Irinotecan + Raltitrexed (Fluorouracil intolerable) (Category 2A) • Irinotecan + Capecitabine ± Bevacizumab^d (Category 1B) 	Other local treatments (Category 3)
Previously treated with Irinotecan in the first line (MSS or MSI-L/pMMR, RAS and BRAF wild-type)	<ul style="list-style-type: none"> • FOLFOX ± targeted therapy (Cetuximab^c or Bevacizumab^c) (Category 2A) • CAPEOX ± Bevacizumab^c (Category 1A) 	<ul style="list-style-type: none"> • Oxaliplatin + Raltitrexed (Fluorouracil intolerable) (Category 2A) 	Other local treatments (Category 3)
Previously treated with Oxaliplatin in the first line (MSS or MSI-L/pMMR, RAS or BRAF mutation)	FOLFIRI ± Bevacizumab ^c (Category 1A)	<ul style="list-style-type: none"> • Irinotecan ± Bevacizumab^c (Category 2A) • Irinotecan + Raltitrexed (Fluorouracil intolerable) (Category 2A) • Irinotecan + Capecitabine ± Bevacizumab^d (Category 1B) 	<ul style="list-style-type: none"> • Other local treatments (Category 3) • Irinotecan + Cetuximab + Vemurafenib (RAS wild-type/BRAF V600E mutation)^e (Category 2B) • BRAF inhibitor + Cetuximab ± MEK inhibitor (RAS wild-type/BRAF V600E mutation)^e (Category 2B)
Previously treated with Irinotecan in the first line (MSS or MSI-L/pMMR, RAS or BRAF mutation)	FOLFOX/CAPEOX ± Bevacizumab ^c (Category 1A)	<ul style="list-style-type: none"> • Oxaliplatin + Raltitrexed (Fluorouracil intolerable) (Category 2A) 	<ul style="list-style-type: none"> • Other local treatments (Category 3) • BRAF inhibitor + Cetuximab ± MEK inhibitor (RAS wild-type/BRAF V600E mutation)^e (Category 2B)
Not previously treated with Irinotecan or Oxaliplatin in the first line (MSS or MSI-L/pMMR)	<ul style="list-style-type: none"> • FOLFOX/FOLFIRI ± Targeted Therapy (Cetuximab^{c,f} or Bevacizumab^c) (Category 2A) • CAPEOX ± Bevacizumab^c (Category 2A) 	<ul style="list-style-type: none"> • Irinotecan ± Targeted Therapy (Cetuximab^{c,f} or Bevacizumab^e) (Category 2A) • Oxaliplatin or Irinotecan + Raltitrexed (Fluorouracil intolerable) (Category 2A) • Irinotecan + Capecitabine ± Bevacizumab^d (Category 1B) 	<ul style="list-style-type: none"> • Other local treatments (Category 3) • Irinotecan + Cetuximab + Vemurafenib (RAS wild-type/BRAF V600E mutation)^e (Category 2B) • BRAF inhibitor + Cetuximab ± MEK inhibitor (RAS wild-type/BRAF V600E mutation)^e (Category 2B)

Abbreviations: BRAF, v-raf murine sarcoma viral oncogene homolog B; CAPEOX, this chemotherapy combination contains the drugs capecitabine and oxaliplatin; MSI-H, microsatellite instability-high; dMMR, deficient mismatch repair; MSS, microsatellite stable; MEK, mitogen-activated protein kinase kinase; FOLFOX, this chemotherapy combination contains the drugs leucovorin calcium (folinic acid), fluorouracil, and oxaliplatin; FOLFIRI, this chemotherapy combination contains the drugs leucovorin calcium (folinic acid), fluorouracil, and irinotecan hydrochloride; RAS, rat sarcoma virus;

3.2.1.2.4. The third-line treatment regimen for the palliative treatment group

Stratifications	Grade I recommendations	Grade II recommendations	Grade III recommendations
MSI-H/dMMR, not previously treated by immune checkpoint inhibitors in first-line and second-line treatment	None	<ul style="list-style-type: none"> Envafolelimab, Serplulimab, Tislelizumab, or Pucotenlimab^b (Category 2A) Pembrolizumab and Nivolumab^b (Category 2A) 	Nivolumab + Ipilimumab ^b (Category 2A)
Previously treated with Oxaliplatin and Irinotecan (MSS or MSI-L/pMMR, RAS and BRAF wild-type)	<ul style="list-style-type: none"> Cetuximab ± Irinotecan (Cetuximab therapy naïve) (Category 1A) Regorafenib^g (Category 1A) Fruquintinib^h (Category 1A) Trifluridine/Tipiracil ± Bevacizumabⁱ (Category 1A) 	Clinical trials ^j	<ul style="list-style-type: none"> Anti-HER-2 therapy (HER-2 amplification)^k (Category 2B) Cetuximab ± Irinotecan (Previously treated with Cetuximab) (Category 3) Raltitrexed (No previous Raltitrexed treatment) (Category 3) Best supportive care Other local treatments (Category 3)
Previously treated with Oxaliplatin and Irinotecan (MSS or MSI-L/pMMR, RAS or BRAF mutation)	<ul style="list-style-type: none"> Regorafenib^g (Category 1A) Fruquintinib^h (Category 1A) Trifluridine/Tipiracil ± Bevacizumabⁱ (Category 1A) 	Clinical trials ^j	<ul style="list-style-type: none"> Irinotecan + Cetuximab + Vemurafenib (RAS wild-type/BRAF V600E mutation)^e (Category 2B) BRAF inhibitor + Cetuximab ± MEK inhibitor (RAS wild-type/BRAF V600E mutation)^e (Category 2B) Raltitrexed (No previous Raltitrexed treatment) (Category 3) Best supportive care Other local treatments (Category 3)

Abbreviations: BRAF, v-raf murine sarcoma viral oncogene homolog B; RAS, rat sarcoma virus; MSI-H, microsatellite instability-high; dMMR, deficient mismatch repair; MSS, microsatellite stable; MEK, mitogen-activated protein kinase kinase; HER-2, human epidermal growth factor receptor.

Notes for sections 3.2.1.2.1 to 3.2.1.2.4

^aIn recent years, many retrospective studies have shown that the prognosis of patients with metastatic colon cancer located on the right side (from the cecum to the splenic flexure) is significantly worse than that of patients with left-sided (from the splenic flexure to the rectum) metastatic colon cancer. In RAS wild-type patients, the efficacy of anti-epidermal growth factor receptor (EGFR) monoclonal antibody (Cetuximab) is significantly correlated with tumor location, while no significant association has been observed between the efficacy of anti-vascular endothelial growth factor (VEGF) monoclonal antibody (Bevacizumab) and tumor location. Subgroup analysis of head-to-head randomized controlled trials comparing chemotherapy combined with Bevacizumab or Cetuximab has shown that in left-sided colon cancer, Cetuximab is superior to Bevacizumab in both ORR and OS. However, in right-sided colon cancer, although Cetuximab may have a certain advantage in ORR, Bevacizumab is superior in OS [114, 115].

^bBased on the results of the KEYNOTE-177 study [104], Pembrolizumab was approved for use in China in June 2021. Pembrolizumab is indicated as a first-line monotherapy for patients with unresectable/metastatic colorectal cancer with KRAS, NRAS, and BRAF wild-type and MSI-H or dMMR. Based on other Chinese-based and foreign clinical trial results and NCCN guidelines [116], immune checkpoint inhibitors (PD-1/PD-L1) are recommended for MSI-H/dMMR advanced colorectal cancer patients in second-line and later-lines. Chinese-manufactured Envafolelimab, Serplulimab, and Tislelizumab, as well as imported Pembrolizumab and Nivolumab, have been approved to treat unresectable/metastatic MSI-H/dMMR solid tumors in adults (including patients with advanced colorectal cancer who have failed standard treatment), which are therefore prioritized. Based on the results of the CheckMate142 clinical study and the 5-year follow-up [117], and considering current drug availability as well as Ipilimumab's approval in the United States but not in China, the CSCO Guidelines recommend Nivolumab combined with Ipilimumab for the treatment of MSI-H/dMMR advanced colorectal cancer in the first-, second-, and third-lines (all Grade 3 recommendations).

^cIf a combination of Cetuximab and chemotherapy is used as first-line treatment in the palliative treatment group, Cetuximab is not recommended in the second-line treatment. However, if a combination of Bevacizumab and chemotherapy is used as first-line treatment, Bevacizumab can be retained in the second-line treatment when switching to a different chemotherapy regimen [118].

^dAccording to the results of the literature [119] and AXEPT study [120], the efficacy of combining Irinotecan and Capecitabine is non-inferior to FOLFIRI for Asian patients as a second-line treatment. Therefore, the combination of Irinotecan and Capecitabine can be selected as second-line or later-line treatment according to the patient's tolerance, while the optimal dose and usage of this regimen need to be further determined. The dose of Irinotecan should be reduced for patients with (UDP glucuronosyltransferase 1 family, polypeptide A1) UGT1A1*28 and *6 homozygous or heterozygous variants.

^eIrinotecan + Cetuximab + Vemurafenib regimen is recommended for the treatment of RAS wild-type/BRAF V600E mutation patients in second-line and later-lines according to the results of the SWOG S1406 study [121]. BRAF inhibitors + Cetuximab is recommended for the treatment of RAS wild-type/BRAF V600E mutation patients in second-line and later lines according to the results of the BEACON study and the NCCN guidelines [116]. A combined treatment with BRAF inhibitors + Cetuximab + MEK inhibitors may be considered for patients with extensive metastases and high tumor burden [55].

^fCetuximab may be considered for RAS and BRAF wild-type patients.

^gRegorafenib was approved by the National Medical Products Administration (NMPA) in March 2017 as a third-line treatment for patients with advanced colorectal cancer who have failed fluorouracil, oxaliplatin, irinotecan, or anti-VEGF and anti-EGFR targeted therapy. The China-led clinical trial in Asia (CONCUR) demon-

strated that Chinese patients treated with Regorafenib experienced a greater survival benefit than in Western populations [122]. The first cycle of Regorafenib can follow a dose-escalation method, that is, 80 mg/day in the first week, 120 mg/day in the second week, and 160 mg/day in the third week [123].

^bFruquintinib [124] is another small molecule anti-angiogenic targeted drug for advanced colorectal cancer approved by the NMPA in September 2018. It is suitable for patients with metastatic colorectal cancer who previously received Fluoropyrimidine-, Oxaliplatin-, and Irinotecan-based chemotherapy regimens and who previously received or are not suitable for anti-VEGF treatment and anti-EGFR treatment (RAS wild-type).

ⁱTrifluridine/Tipiracil (TAS-102, FTD/TPI) [125] is an orally administered drug for advanced colorectal cancer approved by the NMPA in August 2019. It is suitable for patients with metastatic colorectal cancer who previously received Fluoropyrimidine-, Oxaliplatin-, and Irinotecan-based chemotherapy regimens and who previously received or are not suitable for anti-VEGF treatment and anti-EGFR treatment (RAS wild-type). In addition, a global randomized phase III study of advanced colorectal cancer patients who failed standard treatment demonstrated that the combination of Trifluridine/Tipiracil and Bevacizumab significantly prolonged the OS and PFS of patients compared to Trifluridine/Tipiracil monotherapy [126].

^jAfter the failure of standard treatment or before enrollment in clinical trials, HER-2 IHC testing and NGS testing at qualified testing institutions may be conducted to assist subsequent treatment decisions. Given the limitations of current treatment efficacy, it is recommended to encourage patients to voluntarily participate in clinical trials that match their condition.

^kAlthough there is a lack of data on anti-HER-2 targeted therapy for HER-2 amplified colorectal cancer in China, the combination of Trastuzumab + Pertuzumab or Trastuzumab + Lapatinib is recommended for HER-2 amplified patients in the third-line treatment according to the NCCN guidelines in 2022 [116]. In a global Phase II clinical study (DESTINY-CRC01), the anti-HER-2 ADC drug Trastuzumab deruxtecan showed promising efficacy in advanced colorectal cancer patients with HER-2 overexpression/amplification who failed in the standard treatment [127]. Therefore, advanced colorectal cancer patients with HER-2 overexpression/amplification are encouraged to participate in the clinical trials related to anti-HER-2 ADCs.

A regimen combining 5-FU/LV (or Capecitabine) with Oxaliplatin or Irinotecan [116, 128] plus molecular targeted therapy should be selected for potentially resectable patients, a. A potent FOLFOXIRI ± Bevacizumab regimen can be cautiously used for highly selected potentially resectable patients [129]. The TRICE study found that, in RAS wild-type patients with initially unresectable liver metastases (including both technically unresectable and those technically resectable but with ≥5 metastatic lesions), compared to FOLFOX + Cetuximab, FOLFOXIRI + Cetuximab increased the objective response rate (ORR) and tumor regression depth. However, this regimen failed to improve the R0 resection rate and progression-free survival (PFS) and significantly increased the incidence of grade 3-4 neutropenia and diarrhea. Patients who successfully converted and underwent R0 resection of both primary and metastatic lesions are generally recommended to continue adjuvant chemotherapy post-surgery, aiming to complete a total of six months of perioperative treatment. It is currently controversial whether to continue targeted therapy after surgery when targeted therapy is effective before surgery. For potentially resectable MSI-H/dMMR patients, KEYNOTE-177 study has demonstrated that traditional chemotherapy combined with targeted therapy was suboptimal with a limited ORR. To achieve maximum tumor regression, conversion therapy with immune checkpoint inhibitors (PD-1 inhibitors) may be considered.

Besides, the resectability of metastases should be assessed closely during conversion therapy. It is recommended to perform an imaging evaluation every 6-8 weeks. Surgical treatment should be timely performed when metastases become resectable.

For patients in the potential resectable group whose primary and metastatic lesions cannot achieve R0 resection after receiving conversion therapy for more than six months, and for patients in the palliative treatment group who have achieved a response or stable disease after receiving

4-6 months of first-line treatment, maintenance treatment may be considered. This may include low-toxicity 5-FU/LV or Capecitabine monotherapy ± Bevacizumab, or temporary discontinuation of systemic treatment to reduce the toxicity with high-intensity combination chemotherapy [130, 131]. The trials on Cetuximab for maintenance treatment are limited.

In patients with unresectable metastases, there is no consensus on whether asymptomatic primary lesions should be resected or the optimal resection timing. Therefore, individualized decisions need to be made for each case within the MDT framework. Multiple factors need to be comprehensively analyzed to determine the performance of primary lesion resection, including tumor progression rate, expected survival, primary lesion location and size, circumference/degree of intestinal stenosis, willingness and feasibility of receiving systemic treatment, etc. [132-134].

The results of the CodeBreak 300 randomized Phase III clinical study showed that in KRAS G12C mutant advanced colorectal cancer patients with standard treatment failure, the combination of KRAS G12C inhibitor Sotorasib and panitumumab significantly prolonged PFS [135] compared with the investigator's choice regimen (Trifluridine/Tipiracil [TAS-102] or Regorafenib). In another Phase II clinical study (NCT04585035), KRAS G12C inhibitor Garsorasib combined with Cetuximab showed promising efficacy in KRAS G12C mutant advanced colorectal cancer patients with standard treatment failure. In consideration of drug availability, patients with KRAS G12C mutant advanced colorectal cancer are encouraged to participate in clinical trials related to KRAS G12C inhibitors ± anti-EGFR treatment.

For patients with MSS/pMMR advanced colorectal cancer, the presence of POLE/POLD1 pathogenic mutation may indicate a greater efficacy of immune checkpoint inhibitor therapy [136-139]. In terms of immune-targeted

combination therapy, several phase I/II clinical studies have explored the efficacy of PD-1 antibodies combined with Regorafenib, Fruquintinib, and other drugs with anti-angiogenic effects in MSS/pMMR advanced colorectal cancer patients who have failed standard treatment, but most studies have reported suboptimal ORR [140–143]. A recent phase II clinical study showed promising efficacy of the triple combination of Chidamide (histone deacetylase inhibitor) with Bevacizumab and PD-1 antibody in MSS/pMMR advanced colorectal cancer patients who failed standard treatment (ORR 44%, median PFS 7.3 months) [144]. Therefore, MSS/pMMR advanced colorectal cancer patients are encouraged to participate in clinical trials involving the “histone deacetylase inhibitor + anti-VEGF + PD-1 antibody” combination regimen. In addition, several phase II studies (CheckMate 9×8, AtezoTRIBE, ASTRUM015 [145], BBCAPX [146]) have explored the efficacy of combining PD-1/PD-L1 antibodies with first-line standard treatment (FOLFOX/XELOX/FOLFOXIRI + Bevacizumab) in MSS/pMMR advanced colorectal cancer. However, the results of these study are inconsistent and further phase III studies are still warranted.

3.2.2. Treatment of recurrent metastatic colon cancer after surgery

3.2.2.1. Treatment of resectable metastatic colon cancer

There is no concern about primary tumors in this group of patients. The treatment principles can refer to the description in the “Asymptomatic primary tumor with synchronous liver metastasis” under the section “3.2.1.1 Treatment of initially resectable metastatic colon cancer”.

3.2.2.2. Treatment of unresectable metastatic colon cancer

The treatment principles can refer to the description in the “Asymptomatic primary lesion” under the section “3.2.1.2 Treatment of initially unresectable metastatic colon cancer”.

3.2.3. Common systemic treatment regimens for metastatic colon cancer

- [mFOLFOX6]
 - Oxaliplatin 85 mg/m², intravenous infusion over 2 hours, day 1;
 - LV 400 mg/m², intravenous infusion over 2 hours, day 1;
 - 5-FU 400 mg/m², intravenous bolus, day 1, followed by 1,200 mg·m⁻²·d⁻¹ continuous intravenous infusion over 2 days (total dose 2,400 mg/m², infusion over 46-48 hours);
 - Repeat every 2 weeks
- [mFOLFOX6 + Bevacizumab]
 - Oxaliplatin 85 mg/m², intravenous infusion over 2 hours, day 1;
 - LV 400 mg/m², intravenous infusion over 2 hours, day 1;
 - 5-FU 400 mg/m², intravenous bolus, day 1, followed by 1,200 mg·m⁻²·d⁻¹ continuous intravenous infusion over 2 days (total dose 2,400 mg/m², infusion over 46-48 hours);
 - Bevacizumab 5 mg/kg, intravenous infusion, day 1;
 - Repeat every 2 weeks
- [mFOLFOX6 + Cetuximab]
 - Oxaliplatin 85 mg/m², intravenous infusion over 2 hours, day 1;
 - LV 400 mg/m², intravenous infusion over 2 hours, day 1;
 - 5-FU 400 mg/m², intravenous bolus, day 1; followed by 1,200 mg/(m²·day) continuous intravenous infusion for 2 days (total dose 2,400 mg/m², infusion over 46-48 hours);
 - Cetuximab 400 mg/m², intravenous infusion, initial intravenous infusion over more than 2 hours, then 250 mg/m² intravenous infusion over more than 60 minutes, weekly;
 - Or Cetuximab 500 mg/m², intravenous infusion, day 1, initial infusion over more than 2 hours, every 2 weeks
- [CAPEOX]
 - Oxaliplatin 130 mg/m², intravenous infusion over more than 2 hours, day 1;
 - Capecitabine 1,000 mg/m², orally, twice a day, days 1-14;
 - Repeat every 3 weeks
- [CAPEOX + Bevacizumab]
 - Oxaliplatin 130 mg/m², intravenous infusion over more than 2 hours, day 1;
 - Capecitabine 1,000 mg/m², orally, twice a day, days 1-14;
 - Bevacizumab 7.5 mg/kg, intravenous infusion, day 1;
 - Repeat every 3 weeks
- [FOLFIRI]
 - Irinotecan 180 mg/m², intravenous infusion over 30-90 minutes, day 1;
 - LV 400 mg/m², intravenous infusion over 2 hours, day 1;
 - 5-FU 400 mg/m², intravenous bolus, day 1; followed by 1,200 mg·m⁻²·d⁻¹ continuous intravenous infusion for 2 days (total dose 2,400 mg/m², infusion over 46-48 hours);
 - Repeat every 2 weeks
- [FOLFIRI + Bevacizumab]
 - Irinotecan 180 mg/m², intravenous infusion over 30-90 minutes, day 1;
 - Leucovorin (LV) 400 mg/m², intravenous infusion over 2 hours, day 1;

- 5-FU 400 mg/m², intravenous bolus injection, day 1; followed by 1,200 mg·m⁻²·d⁻¹ continuous intravenous infusion for 2 days (total dose 2,400 mg/m², infusion over 46-48 hours);
- Bevacizumab 5 mg/kg, intravenous infusion, day 1;
- Repeat every 2 weeks
- [FOLFIRI + Cetuximab]
 - Irinotecan 180 mg/m², intravenous infusion over 30-90 minutes, day 1;
 - LV 400 mg/m², intravenous infusion over 2 hours, day 1;
 - 5-FU 400 mg/m², intravenous bolus, day 1; followed by 1,200 mg·m⁻²·d⁻¹ continuous intravenous infusion for 2 days (total dose 2,400 mg/m², infusion over 46-48 hours);
 - Repeat every 2 weeks
 - Cetuximab 400 mg/m², intravenous infusion, initial intravenous infusion over more than 2 hours, then 250 mg/m² intravenous infusion over more than 60 minutes, weekly;
 - Or Cetuximab 500 mg/m², intravenous infusion, day 1, infusion over more than 2 hours, every 2 weeks
- [CapIRI]
 - Irinotecan 180 mg/m², intravenous infusion over 30-90 minutes, day 1;
 - Capecitabine 1,000 mg/m², orally, twice a day, days 1-7;
 - Repeat every 2 weeks
- [CapIRI + Bevacizumab]
 - Irinotecan 180 mg/m², intravenous infusion over 30-90 minutes, day 1;
 - Capecitabine 1,000 mg/m² each time, orally, twice a day, days 1-7;
 - Bevacizumab 5 mg/kg, intravenous infusion, day 1;
 - Repeat every 2 weeks
- [mXELIRI]
 - Irinotecan 200 mg/m², intravenous infusion over 30-90 minutes, day 1;
 - Capecitabine 800 mg/m², orally, twice a day, days 1-14;
 - Repeat every 3 weeks
- [mXELIRI + Bevacizumab]
 - Irinotecan 200 mg/m², intravenous infusion over 30-90 minutes, day 1;
 - Capecitabine, 800 mg/m² each time, orally, twice a day, days 1-14;
 - Bevacizumab 7.5 mg/kg, intravenous infusion, day 1;
 - Repeat every 3 weeks
 - For patients with *UGT1A1**28 and *6 homozygous or heterozygous variants, the recommended dose of Irinotecan is 150 mg/m²,
- [Capecitabine]
 - 1,250 mg/m² each time, orally, twice a day, day 1-14;
 - Repeat every 3 weeks.
- [Capecitabine + Bevacizumab]
 - 1,250 mg/m² each time, orally, twice a day, day 1-14;
 - Bevacizumab 7.5 mg/kg, intravenous infusion, day 1;
 - Repeat every 3 weeks.
- [Simplified biweekly 5-FU infusion/LV regimen (sLV5FU2)]
 - LV 400 mg/m², intravenous infusion over 2 hours, day 1;
 - Followed by 5-FU dose: 400 mg/m², intravenous bolus, day 1; then continuous intravenous infusion at a rate of 1,200 mg·m⁻²·d⁻¹ for 2 days (total dose 2,400 mg/m², infusion for 46-48 hours);
 - Repeat every 2 weeks.
- [FOLFOXIRI]
 - Irinotecan 165 mg/m², intravenous infusion, day 1;
 - Oxaliplatin 85 mg/m², intravenous infusion, day 1;
 - LV 400 mg/m², intravenous infusion, day 1;
 - 5-FU total dose: 2,400-3,200 mg/m², day 1, continuous intravenous infusion for 48 hours;
 - Repeat every 2 weeks.
- [FOLFOXIRI + Bevacizumab]
 - Irinotecan: 165 mg/m², intravenous infusion, day 1;
 - Oxaliplatin: 85 mg/m², intravenous infusion, day 1;
 - LV: 400 mg/m², intravenous infusion, day 1;
 - 5-FU total dose: 2,400-3,200 mg/m², day 1, continuous intravenous infusion for 48 hours;
 - Bevacizumab dose: 5 mg/kg, intravenous infusion, day 1;
 - Repeat every 2 weeks.
- [Irinotecan]
 - Irinotecan 125 mg/m², intravenous infusion over 30-90 minutes, day 1 and 8; repeat every 3 weeks;
 - Or Irinotecan: 300-350 mg/m², intravenous infusion over 30-90 minutes, day 1; repeat every 3 weeks.
- [Cetuximab + Irinotecan]
 - Cetuximab initial dose: 400 mg/m², intravenous infusion, then 250 mg/m² weekly;
 - or Cetuximab 500 mg/m², intravenous infusion, once every 2 weeks;
 - Irinotecan 300-350 mg/m², intravenous infusion, repeat every 3 weeks;
 - or Irinotecan 180 mg/m², intravenous infusion, repeat every 2 weeks;
 - or Irinotecan 125 mg/m², intravenous infusion, day 1 and 8, repeat every 3 weeks.
- [Cetuximab]
 - Cetuximab, initial dose 400 mg/m², intravenous infusion, then 250 mg/m², once a week;
 - or Cetuximab 500 mg/m², intravenous infusion, once every 2 weeks.
- [Regorafenib]
 - Regorafenib 160mg, orally, once a day, day 1-21, repeat every 28 days;

- or dose titration in the first cycle: 80 mg/d in week 1, 120 mg/d in week 2, 160 mg/d in week 3.
- [Fruquintinib]
 - Fruquintinib 5mg, orally, once a day, day 1-21, repeat every 28 days.
- [Trifluridine/Tipiracil (TAS-102, FTD/TPI)]
 - Trifluridine/Tipiracil (TAS-102) 35 mg/m² (maximum single dose 80mg), orally, twice a day, day 1-5 and days 8-12, repeat every 28 days.
- [Trifluridine/Tipiracil (TAS-102, FTD/TPI) + Bevacizumab]
 - Trifluridine/Tipiracil (TAS-102, FTD/TPI) 35 mg/m² (maximum single dose 80mg), orally, twice a day, day 1-5 and days 8-12, repeat every 28 days;
 - Bevacizumab 5 mg/kg, intravenous infusion, day 1, repeat every 14 days;
 - or Trifluridine/Tipiracil (TAS-102, FTD/TPI) 35 mg/m² (maximum single dose 80mg), orally, twice a day, day 1-5, repeat every 14 days;
 - Bevacizumab 5 mg/kg, intravenous infusion, day 1, repeat every 14 days.
- [Raltitrexed]
 - Raltitrexed 3 mg/m², intravenous infusion (in 50-250ml 0.9% sodium chloride injection or 5% glucose injection) over 15 minutes, repeat every 3 weeks;
 - Raltitrexed 2 mg/m², intravenous infusion (in 50-250ml 0.9% sodium chloride injection or 5% glucose injection) over 15 minutes, repeat every 2 weeks (preferably selected when used in combination with Oxaliplatin or Irinotecan).
- [Pembrolizumab] (for dMMR/MSI-H only)
 - Pembrolizumab 200mg, intravenous infusion, day 1, repeat every 3 weeks;
 - or Pembrolizumab 2 mg/kg, intravenous infusion, day 1, repeat every 3 weeks.
- [Nivolumab] (for dMMR/MSI-H only)
 - Nivolumab 3 mg/kg, intravenous infusion, day 1, repeat every 2 weeks;
 - or Nivolumab 240mg, intravenous infusion, day 1, repeat every 2 weeks;
 - or Nivolumab 480mg, intravenous infusion, day 1, repeat every 4 weeks
- [Nivolumab + Ipilimumab] (for dMMR/MSI-H only)
 - Nivolumab 3 mg/kg, intravenous infusion over 30 minutes, day 1, repeat every 3 weeks;
 - Ipilimumab 1 mg/kg, intravenous infusion over 30 minutes, day 1, repeat every 3 weeks;
 - After a total of 4 cycles, Nivolumab 3 mg/kg or Nivolumab 240mg, intravenous infusion, day 1, repeat every 2 weeks; or Nivolumab 480mg, intravenous infusion, day 1, repeat every 4 weeks
- [Envafolelimab] (for dMMR/MSI-H only)
 - Envafolelimab 150mg, subcutaneous injection, day 1, repeat weekly
- [Serplulimab] (for dMMR/MSI-H only)
 - Serplulimab 3 mg/kg, intravenous infusion, day 1, repeat every 2 weeks
- [Tislelizumab] (for dMMR/MSI-H only)
 - Tislelizumab 200mg, intravenous infusion, day 1, repeat every 3 weeks
- [Trastuzumab + Pertuzumab] (for HER-2 amplification only)
 - Trastuzumab, initial dose 8 mg/kg, intravenous infusion, day 1; followed by 6 mg/kg intravenous infusion, repeat every 3 weeks;
 - Pertuzumab, initial dose 840mg, intravenous infusion, day 1; followed by 420mg intravenous infusion, repeat every 3 weeks
- [Trastuzumab + Lapatinib] (for HER-2 amplification only)
 - Trastuzumab, initial dose 8 mg/kg, intravenous infusion, day 1; followed by 6 mg/kg intravenous infusion, repeat every 3 weeks;
 - Lapatinib 1,000mg, oral administration, once daily
- [Vemurafenib + Irinotecan + Cetuximab] (for RAS wild-type/*BRAF* V600E mutation only)
 - Vemurafenib 960mg, oral administration, twice a day;
 - Irinotecan 180 mg/m², intravenous infusion, day 1, once every 2 weeks;
 - Cetuximab 500 mg/m², intravenous infusion, day 1, once every 2 weeks.
- [Dabrafenib + Cetuximab ± Trametinib] (for RAS wild-type/*BRAF* V600E mutation only)
 - Dabrafenib 150mg, oral administration, twice a day;
 - Cetuximab 500 mg/m², intravenous infusion, day 1, repeat every 2 weeks;
 - or ± Trametinib 2 mg, oral administration, once a day.

3.3. Follow-up of colon cancer

Objectives ^{a,b}	Grade I recommendations	Grade II recommendations	Grade III recommendations
Postoperative follow-up of stages I-III patients	<p><u>Follow-up frequency</u></p> <ul style="list-style-type: none"> • Stage I: Every 6 months for 5 years • Stages II-III: Every 3 months for 3 years; then every 6 months until 5 years postoperatively; annually after 5 years <p><u>Follow-up contents (each time, unless otherwise specified):</u></p> <ul style="list-style-type: none"> • Physical examination, emphasizing digital rectal exam • Blood CEA testing • Liver ultrasound examination for stages I-II • Chest-abdomen-pelvis CT annually for stage III or in case of abnormal CEA or ultrasound • Colonoscopy^c 	<p>Higher frequency of follow-up compared to Grade I recommendations</p> <ul style="list-style-type: none"> • Contrast-enhanced chest-abdomen-pelvis CT • Testing for previously elevated markers 	<p>None</p> <ul style="list-style-type: none"> • Contrast-enhanced liver ultrasound^d • PET/CT^e
Follow-up after R0 resection/destruction of metastatic lesions in stage IV patients	<p><u>Follow-up/monitoring frequency:</u></p> <ul style="list-style-type: none"> • Every 3 months for the first 3 years, then every 6 months until 5 years postoperatively annually after 5 years <p><u>Follow-up/monitoring contents:</u></p> <ul style="list-style-type: none"> • Physical examination • Blood CEA testing • Contrast-enhanced chest-abdomen-pelvis CT every 6-12 months 	<p>Higher frequency of follow-up compared to Grade I recommendations</p> <ul style="list-style-type: none"> • Abdominal-pelvic ultrasound examination • Chest X-ray • Colonoscopy^c • Testing for previously elevated markers 	<p>None</p> <ul style="list-style-type: none"> • Contrast-enhanced liver ultrasound^d • PET/CT^e

Abbreviations: CT, computed tomography; CEA, carcinoembryonic antigen; PET, positron emission tomography.

^aThe primary purpose of follow-up/monitoring is to detect metastatic or recurrence disease that may be treated with potentially curative intent, while also considering the cost-effectiveness from a health economics perspective. There is no high-level evidence-based medicine to support the definition of the best follow-up/monitoring strategy.

^bIf a patient's physical condition does not allow for anticancer treatment required upon recurrence, routine tumor follow-up/monitoring is not advocated.

^cStrategies for colonoscopy [147]: Colonoscopy is recommended within 1 year after surgery. Colonoscopy should be performed 3-6 months postoperatively if preoperative tumor obstruction prevents full colonoscopy. The colonoscopy re-examination should be performed within one year if progressive adenomas (tubulovillous adenomas, diameter larger than 1 cm, or high-grade dysplasia) are found during each colonoscopy. The colonoscopy re-examination should be performed within 3 years and then every 5 years thereafter if no advanced adenomas are found during each colonoscopy.

^dIt is applicable when liver metastasis is suspected with ordinary ultrasound or CT examination.

^ePET/CT is only recommended for clinical suspicion of recurrence while routine imaging is negative, for instance, persistent elevation of CEA level. PET is not recommended as a routine follow-up/monitoring tool.

Recent studies have shown that dynamic ctDNA monitoring aids in the early detection of postoperative recurrence and metastasis [68, 69, 148]. However, there is

still debate over whether it should be routinely used for postoperative follow-up and treatment guidance.

4. Principles for rectal cancer treatment

4.1. Principles for non-metastatic rectal cancer treatment

4.1.1. Principles for rectal adenomas treatment

Stage	Stratifications	Grade I recommendations	Grade II recommendations	Grade III recommendations
Rectal high-grade intraepithelial neoplasia	Distance from lesion to the anal verge \leq 8 cm	Transanal excision or endoscopic resection	TEM ^a	Laparoscopic or open rectal segmental resection
	Distance from lesion to the anal verge 8-15 cm	Endoscopic resection	1. TEM ^a 2. Laparoscopic or open rectal segmental resection	None

Abbreviations: TEM, transanal endoscopic microsurgery.

^aTEM is a surgical technique used to remove tumors through the anus with specialized instruments. It allows for the excision of lesions closer to the anal verge (within 20 cm), offering the advantages of full-thickness excision and suturing under direct visualization [76, 149].

All principles in “3.1.1.1.1 Endoscopic treatment strategies” apply to the treatment of rectal adenomas.

Postoperative management of rectal adenomas after local excision should follow the strategies outlined in “3.1.1.1.2 Management strategies after endoscopic resection of polyps”.

4.1.2. Principles of rectal cancer of cT1-2N0 treatment

Stage	Stratification	Grade I recommendations	Grade II recommendations	Grade III recommendations
cT1N0	With difficulties in anal sphincter preservation ^a	<ul style="list-style-type: none"> Transanal local excision^b Radical surgery of rectal cancer^c 	Concurrent chemoradiotherapy ^d for patients with a strong desire of sphincter preservation, if <ul style="list-style-type: none"> cCR^e – watch and wait^f ycT₁ – transanal local excision 	None
	Without difficulties in anal sphincter preservation	Radical surgery of rectal cancer ^c	1. Endoscopic resection ^b 2. Transanal local excision (including TEM) ^b	None
cT2N0	With difficulties in anal sphincter preservation ^a	Radical surgery of rectal cancer ^c	Preoperative concurrent chemoradiotherapy ^d for patients with a strong desire for sphincter preservation, if <ul style="list-style-type: none"> cCR^e – watch and wait^f ycT₁ – transanal local excision ycT₂ – radical surgery of rectal cancer^c 	None
	Without difficulties in anal sphincter preservation	Radical surgery of rectal cancer ^c	None	None
cT1-2N0	With medical factors precluding surgery	None	Concurrent chemoradiotherapy ^g	Short-course radiotherapy ^h ± chemotherapy ⁱ

Abbreviations: cTN, clinical tumor, node staging; cCR, clinical complete response; TEM, transanal endoscopic microsurgery, ycT, clinical T staging after neoadjuvant therapy; APR, abdominoperineal resection; TME, total mesorectal excision; LLNM, lateral lymph node metastasis.

^aIt applies to patients with a strong desire to preserve the anal sphincter and who are unwilling to undergo APR.

^bSalvage radical surgery of rectal cancer is required if any of the following pathological findings are present after local resection: poorly differentiated tumor histology, vascular invasion, positive margins, tumor infiltration beyond the outer 1/3 of the submucosal layer (SM₃ level), submucosal infiltration >1 mm, or T2 stage tumor. Chemotherapy and radiotherapy should be considered if salvage surgery is not agreed.

^cRadical surgery for rectal cancer:

1) Mid-low rectal cancer should undergo TME [150], while upper rectal cancer should undergo wide mesorectal excision (removal of at least 5cm of the rectal mesentery).

2) Laparoscopic/robot-assisted radical rectal cancer surgery: Despite the advantages of minimally invasive and anus-preserving procedures, the long-term oncological efficacy still needs further evaluation and is recommended to be performed in experienced centers.

3) Surgical principles of lateral lymph node dissection: The diagnostic criteria for baseline lateral lymph node metastasis (LLNM) are described in the “Imaging Diagnosis” section. Prophylactic dissection of lateral lymph nodes without confirmed imaging diagnosis is not recommended. For confirmed LLNM on imag-

ing, preoperative neoadjuvant chemoradiotherapy is recommended, followed by lateral lymph node dissection. If the lymph node disappears on imaging after treatment, follow-up observation may be conducted.

^dIf patients are considering non-radical surgical treatment, conventionally fractionated concurrent chemoradiotherapy with a dose of 50-54 Gy administered in 25-30 fractions is recommended. For eligible centers, intermittent consolidation chemotherapy after conventional fractionated concurrent chemoradiotherapy is recommended. According to the TAU-TEM trial [151], local excision is prioritized. An intensified local treatment regimen may be considered for patients who are ineligible for surgery or explicitly refuse surgical treatment, with treatment strategies informed by trials including WW2 and OPERA [152-154]. Risks of increased bleeding and other toxic reactions need to be thoroughly communicated with the patients. For patients with dMMR/MSI-H, extrapolation from the results of immunotherapy clinical studies for locally advanced rectal cancer at Memorial Sloan Kettering Cancer Center (MSKCC) and Sun Yat-sen University Cancer Center [41, 155] may be considered. After MDT discussion, immune checkpoint inhibitors may be administered first, followed by an evaluation for surgery and the development of a surgical plan. It is strongly recommended to conduct a treatment response assessment using pelvic MRI, abdominal/pelvic CT scans, colonoscopy, and digital rectal examination (DRE) 2-3 months after treatment completion. For patients undergoing non-radical surgical treatment, close follow-up is recommended as follows, i) performing colonoscopy and DRE every 3 months within 2 years after treatment, then once every 6-12 months thereafter; ii) performing MRI scans once every 3-6 months within 2 years after treatment, then once every 6-12 months thereafter; and iii) maintaining the follow-up for at least 5 years. DRE is simple and painless, eligible patients may consider increasing the frequency of examinations.

^eCurrently, the internationally recognized criteria for cCR [156] include, i) normal findings on DRE in the original tumor area, with no palpable tumor mass; ii) no visible tumor signs on endoscopy, or only minimal residual erythematous ulcers or scars; iii) on high-resolution pelvic MRI, substantial reduction, without observable residual tumor masses or with only residual fibrosis (may relate to limited DWI signals, or associated with residual bowel wall thickening due to edema), with no suspicious lymph nodes; iv) endoscopic biopsy is not mandatory for defining cCR. Patients meeting the criteria of DRE, sigmoidoscopy, and MRI cCR standards should not be performed the endoscopic biopsy.

^fThe “watch-and-wait” strategy is currently being explored both internationally and in China. It should be implemented with thorough patient communication and high-frequency follow-up. Additionally, patients who are considered for the “watch-and-wait” approach should be provided with detailed information as follows: Given the current limitations of diagnostic methods, the concordance rate between cCR and pathological complete response (pCR) remains unsatisfactory. The risk of tumor residue (including the rectal wall beyond the mucosa and the lymph nodes within the mesentery) and subsequent tumor in situ regrowth and even distant metastasis exist. Patients are required to follow close post-treatment monitoring. Detailed should also be provided of remedial treatment measures and consequences following tumor recurrence or metastasis.

^gRefer to note b of section 4.1.3.

^hRefer to note e of section 4.1.3.

ⁱRefer to note d of section 4.1.3.

4.1.3. Treatment principles for rectal cancer of cT3/cT4 or N+

This section applies to intermediate and lower rectal cancer, where the tumor is located less than 10 cm from the anal verge as assessed by MRI. For high rectal cancer located more than 10 cm from the anal verge, treatment principles for colon cancer should be followed. In cases where risk stratification is well controlled by MRI, stratified treatment may be considered and be informed of the 2017 ESMO and 2020 ASTRO guidelines for rectal cancer treatment.

4.1.3.1. Treatment principles for rectal cancer patients with pMMR/MSS or unknown MMR/MS status

For dMMR/MSI-H patients, especially those with difficulties in preserving the anal sphincter or unable to achieve R0 resection in T4b stage, neoadjuvant immunotherapy may be considered, followed by MDT evaluation to determine the timing and approach of surgery. Patients are recommended to be informed of the MSKCC study on immunotherapy for locally advanced rectal cancer (e.g., Dostarlimab) [41] to aid in drug selection of neoadjuvant immunotherapy. Besides, similar medica-

tions or participation in clinical trials may be considered based on the accessibility of the drugs.

Radical surgery for rectal cancer:

1. Mid-low rectal cancer should undergo TME [150], while upper rectal cancer should undergo wide mesorectal excision (removal of at least 5 cm of the rectal mesentery).
2. Laparoscopic/robot-assisted radical rectal cancer surgery: Despite the advantages of minimally invasive and anus-preserving procedures, the long-term oncological efficacy still needs further evaluation and is recommended to be performed in experienced centers.
3. Surgical principles of lateral lymph node dissection: The diagnostic criteria for baseline lateral lymph node metastasis (LLNM) are described in the “Imaging Diagnosis” section. Prophylactic dissection of lateral lymph nodes without confirmed imaging diagnosis is not recommended. For confirmed LLNM on imaging, preoperative neoadjuvant chemoradiotherapy is recommended, followed by lateral lymph node dissection. If the lymph node disappears on imaging after treatment, follow-up observation may be conducted.

Stages	Stratifications	Grade I recommendations	Grade II recommendations	Grade III recommendations
cT3N _{any} and MRF ^{-a} ; cT1-2N ⁺	Without difficulties in anal sphincter preservation	Concurrent chemoradiotherapy ^b ± interval chemotherapy ^c (reassessment) + radical rectal cancer surgery + adjuvant chemotherapy ^{d,e} (Category 1A)	<ul style="list-style-type: none"> • Short-course radiotherapy^f + radical surgery of rectal cancer + adjuvant chemotherapy^{d,e} (Category 1B) • For highly selective patients with low risk of recurrence^g: chemotherapy (assessment) + selective chemoradiotherapy^h (reassessment) + radical rectal cancer surgery ± chemotherapy (based on postoperative pathological findings for chemoradiotherapy/chemotherapy) (Category 1B) 	Radical surgery of rectal cancer ± Adjuvant treatment ^{d,e,i}
	With difficulties in anal sphincter preservation	Concurrent chemoradiotherapy ^b ± interval chemotherapy ^c (reassessment) + radical surgery of rectal cancer + adjuvant chemotherapy ^{d,e} (Category 1A)	<ul style="list-style-type: none"> • Chemotherapy^j + concurrent chemoradiotherapy^b (reassessment) + radical surgery of rectal cancer ± chemotherapy^{d,e,j} (Category 1B) • Intensified concurrent chemoradiotherapy regimen^b (Capecitabine combined with Irinotecan) (reassessment) + radical surgery of rectal cancer + adjuvant chemotherapy^{d,e} (Category 1B) • Short-course radiotherapy^j + 12-16 weeks of chemotherapy + radical surgery of rectal cancer (Category 1B) 	None
cT3N _{any} with MRF ⁺ ; cT4N _{any} ^k	None	Concurrent chemoradiotherapy ^b ± Interval Chemotherapy ^c (reassessment) + radical surgery of rectal cancers + adjuvant chemotherapy ^{d,e} (Category 1A)	<ul style="list-style-type: none"> • Chemotherapy^j + concurrent chemoradiotherapy^b (reassessment) + radical surgery of rectal cancers ± chemotherapy^{d,e,j} (Category 1B) • Intensified concurrent chemoradiotherapy regimen^b (capecitabine combined with Irinotecan) (reassessment) + radical surgery of rectal cancers + adjuvant chemotherapy^{d,e} (Category 1B) • Short-course radiotherapy^f + 12-16 weeks of chemotherapy + radical rectal cancers surgery (Category 1B) 	None
cT3-4 or N ⁺ , or patients with cCR after neoadjuvant chemoradiotherapy (evaluation criteria refer to Notes e in section 4.1.2)	Preservation of the anus without technical difficulties	Radical rectal cancer surgery ± adjuvant chemotherapy ^{d,e}	• Watch and wait (refer to Notes f in section 4.1.2) ^l	None
	Preservation of the anus with technical challenges but strongly desired by the patient	Watch and wait (refer to Notes f in section 4.1.2) ^l	None	None

(Continues)

Stages	Stratifications	Grade I recommendations	Grade II recommendations	Grade III recommendations
cT3-4 or N+, or patients do not undergo preoperative radiotherapy due to preoperative contraindications to comprehensive treatment or other reasons	After radical surgery of rectal cancer pT1-2N0 After radical surgery of rectal cancer pT3-4 or N+	Observation patients with no contraindications to chemoradiotherapy after reassessment: adjuvant chemotherapy ^{d,e,m} + adjuvant chemoradiotherapy ^{b,e} + adjuvant chemotherapy ^d (Category 1A)	None • Patients with no contraindications to chemoradiotherapy after reassessment: adjuvant chemoradiotherapy ^{b,e,m} + adjuvant chemotherapy ^d (Category 1B)	None None
cT3-4N _{any}	With medical factors precluding surgery	None	• Concurrent chemoradiotherapy ^b ± Chemotherapy ^d	None

Abbreviations: cTN, clinical tumor, node staging; pTN, pathological tumor, node staging; MRF, mesorectal fascia; cCR, complete clinical remission.

^aThe mesorectal fascia (MRF) is assessed by measuring the closest distance from the tumor to the mesorectal fascia. A negative MRF indicates that the distance from the tumor to both the mesorectal fascia and the levator ani muscle is greater than 1 mm, with no invasion into the intersphincteric plane.

^bThe treatment strategy of preoperative chemoradiotherapy is the standard treatment for locally advanced mid-low rectal cancer (stage II, III) [157–160] (see 4.1.4 Appendix of rectal cancer management). A general trend is to intensify systemic chemotherapy before and after preoperative radiotherapy. Several studies have shown survival benefits or increased pCR, although the optimal method remains unclear. Concurrent use of Bevacizumab or Cetuximab with rectal cancer radiotherapy is not recommended outside of clinical trials. For patients who strongly wish to preserve anus function but face technical difficulties, it may be beneficial to implement a higher intensity treatment regimen before surgery to achieve a higher pCR rate, for instance, the CinClare study of concurrent chemoradiotherapy with Capecitabine and Irinotecan [161], the FOWARC study of concurrent chemoradiotherapy with FOLFOX [162], or combining chemotherapy during the interval period [163], which includes the total neoadjuvant therapy (TNT) approach [164, 165]. The radiation field can refer to the “Consensus and Contouring Atlas for the Delineation of Clinical Target Volume in Pre-/Post-operative Image-Guided Intensity Modulated Radiotherapy for Rectal Cancer” and the RTOG pelvic contouring atlas [166]. The surgical approach for rectal cancer radical surgery is determined based on the efficacy evaluation after preoperative chemoradiotherapy.

^cMeasures of tumor regression after intensified chemoradiotherapy are as follows: 1) Prolonging the interval period. After traditional long-course chemoradiotherapy, waiting for 6–11 weeks before surgery allow patients to recover from the toxicity of preoperative treatment and enable sufficient tumor regression. The feasibility of R0 resection should be reassessed preoperatively. 2) Consolidation chemotherapy. Studies suggested that adding consolidation chemotherapy after chemoradiotherapy can further enhance tumor regression and improve pCR rates. Consolidation chemotherapy regimens may include FOLFOX, CAPEOX, 5-FU/LV, or Capecitabine, with a recommended duration of 12–16 weeks. Surgery should be performed 2–4 weeks after the end of consolidation chemotherapy, following MRI reassessment. 3) Adopting the TNT treatment model. This model prioritizes concurrent chemoradiotherapy followed by sequential systemic chemotherapy, which is more conducive to tumor regression and can help avoid TME surgery [164, 165]. A “watch and wait” strategy (see Notes e and f in section 4.1.2) may be considered for patients achieving cCR based on DRE, rectal MRI, and direct endoscopic evaluation. This non-surgical treatment method should be conducted in experienced multidisciplinary centers.

^dThe postoperative adjuvant chemotherapy regimen is outlined in section “3.1.1.3 Adjuvant chemotherapy after surgery”. Patients receiving preoperative neoadjuvant chemoradiotherapy should undergo postoperative adjuvant chemotherapy, with a recommended total treatment duration of 6 months [167]. For patients with pathological stage ≤ ypII after preoperative neoadjuvant chemoradiotherapy, fluoropyrimidine monotherapy may be considered following thorough communication with the patient [168].

^eIt is recommended to start postoperative adjuvant treatment as early as possible, and no later than 8 weeks after surgery. In cases where postoperative complications such as poor perineal wound healing or delayed recovery of intestinal function occur, the start of postoperative adjuvant radiotherapy may be appropriately delayed, while it is recommended that this delay should not exceed 12 weeks.

^fShort-course radiotherapy: It is recommended to conduct multidisciplinary discussions regarding the use of short-course radiotherapy [169–173], considering the necessity of downstaging and potential long-term toxic reactions. The specific scheme of classic short-course radiotherapy is 5×5 Gy, once daily, 5 Gy each time, for a total of 5 days, continuously irradiated. It is recommended to employ Three dimensional-conformal radiation therapy (3D-CRT) or Intensity-modulated radiation therapy (IMRT) (Volumetric modulated arc therapy [VMAT]). Concurrent use of chemotherapy drugs and targeted drugs is not recommended. For patients with low recurrence risk (T3) who do not require organ preservation, surgery may be considered within 1 week after completing short-course radiotherapy.

Conversely, for patients at high recurrence risk (MRI evaluation with one of the following: cT4a/b, EMVI⁺, cN2, MRF⁺, positive lateral lymph nodes), consolidation chemotherapy is recommended after short-course radiotherapy, followed by surgical treatment.

^gThe indications for selective chemoradiotherapy include low risk of recurrence, mid-upper rectal cancer without difficulty or demand in preserving the anus, and standard rectal cancer MR staging of cT2N1 and cT3N0-1 [174]. It should be noted that preoperative neoadjuvant chemoradiotherapy is still required for cT4 and cN2, and low rectal cancer. In addition, preoperative neoadjuvant chemoradiotherapy is recommended for rectal cancer with positive lateral lymph nodes.

^hThe chemotherapy regimen is FOLFOX, 5-6 cycles. Specified strategies are as follows, preoperative neoadjuvant chemotherapy with the FOLFOX regimen for 6 cycles followed by evaluation. If less than four cycles are completed or if tumor regression <20% after completing 5-6 cycles, concurrent chemoradiotherapy may be performed.

ⁱConsidering the toxicity of chemoradiotherapy, for patients with locally low-risk recurrence (peritoneum covered, MRF⁻, EMVI⁻, T3a/b [i.e., tumor invasion depth of 1-5 mm beyond the muscle layer]), and no difficulty in preserving the anal sphincter, a treatment regimen of surgery plus adjuvant chemotherapy may be considered [175-177].

^jThe combination of chemotherapy + chemoradiotherapy + surgery may be considered as a treatment option. The preoperative chemotherapy regimen may refer to adjuvant chemotherapy, or the research pattern of the PRODIGE 23 study enrolled patients with good physical condition [178, 179].

^kFor pMMR/MSS patients, several phase II studies have suggested that combining neoadjuvant chemotherapy with immunotherapy achieved higher pCR rates [180-184]. The first phase III trial, UNION, which evaluated the sequential treatment of neoadjuvant short-course radiotherapy, immunotherapy, and chemotherapy for locally advanced rectal cancer, confirmed a significant improvement in pCR. However, long-term efficacy is still under follow-up [185].

^lIf non-surgical treatment is considered, it is recommended to prioritize the model of chemotherapy followed by consolidation chemotherapy [179] (see Notes d of 4.1.2).

^mAdjuvant treatment should be performed if comprehensive treatment is acceptable after reassessment. The total duration of adjuvant treatment, including chemotherapy and radiotherapy, should not exceed 6 months [167].

4.1.4. Appendix of rectal cancer management

4.1.4.1. Principles of radiotherapy

1. The radiation field should include the tumor (or tumor bed) with a safety margin of 2-5 cm, presacral lymph nodes, internal iliac lymph nodes, and obturator lymph nodes. External iliac lymph nodes may be considered for irradiation when T4 tumors invade anterior structures.
2. Use three-dimensional precision radiotherapy, such as 3D-CRT/VMAT or IMRT. Efforts should be made to minimize the inclusion of the small intestine within the radiation field by changing the patient's position or using other methods.
3. Radiation dose: Pelvic dose of 45.0-50.4 Gy over 25-28 fractions, with a single fraction dose of 1.8-2.0 Gy.
4. For resectable tumors or postoperative cases, after delivering 45 Gy of radiation, additional doses should be considered for the local tumor or tumor bed to reduce the volume and dose of intestinal radiation. For preoperative radiotherapy, an extra dose of 5.4 Gy/3 fractions is recommended, and for postoperative radiotherapy, 5.4-9.0 Gy/3-5 fractions.
5. Short-course radiotherapy (25 Gy in 5 fractions) followed by surgery within 1 week may be considered a treatment option for rectal cancer patients staged as T3 by endorectal ultrasound or rectal MRI and without a requirement for sphincter preservation.
6. The dose to the small intestine should be limited to within 50 Gy. Specific limitations can refer to the dose constraint parameters recommended by QUANTEC (volume V15 <120 mL based on small bowel loops, and volume V45 <195 mL based on the entire abdominal cavity).
7. For unresectable tumors, considering the condition of surrounding normal tissues, the radiation dose can be locally escalated to 54-56 Gy if technically feasible. If resection remains unfeasible after assessment, and surrounding normal tissues can tolerate it, the dose may be further increased to 60 Gy.
8. Concurrent chemotherapy is not recommended for short-course radiotherapy. Fluoropyrimidine-based chemotherapy is used concurrently during long-course radiotherapy. To preserve the anal sphincter, strategies including tumor shrinkage improvement or watch and wait may be required, and concurrent chemoradiotherapy with Capecitabine plus Irinotecan may be considered. Synchronous Irinotecan administration should be based on *UGT1A1* gene typing. The recommended doses for patients with *UGT1A1*1*1* (6/6 type) or *UGT1A1*1*28* (6/7 type) genotype are 80 mg/m² once a week and 65 mg/m² once a week, respectively.
9. For patients with limited liver or lung metastases, such as oligometastasis, radiation therapy may be appropriate for highly selected cases or those involved in clinical trials. Highly conformal radiation techniques should be applied in such cases. The recommended techniques include stereotactic body radiotherapy, IMRT, and 3D-CRT (Category 3).
10. The management of adverse events includes: 1) Providing guidance and the use of vaginal dilators for female patients to alleviate symptoms of vaginal stenosis. 2) Informing male patients about the risk of infertility and providing information on relevant sperm banks. 3) Informing female patients about the risk of infertility and providing information on egg, oocyte, and ovarian tissue banks before treatment.

4.1.4.2. Common chemotherapy regimens

4.1.4.2.1. Concurrent chemoradiotherapy regimens

- Radiotherapy + Capecitabine: Radiotherapy for 5 weeks with concurrent Capecitabine 825 mg/m² twice a day, 5 days per week.
- Radiotherapy + 5-FU Continuous Infusion: 225 mg·m⁻²·d⁻¹, continuously infused during radiotherapy, 5 days per week.
- Radiotherapy + Irinotecan combined with Capecitabine: For *UGT1A1**1*1 (6/6 type) and *UGT1A1**1*28 (6/7 type) genotypes, the recommended doses of Irinotecan are 80 mg/m² once a week and 65 mg/m² once a week, respectively; Capecitabine 625 mg/m² twice a day, 5 days per week.

4.1.4.2.2. Postoperative adjuvant chemotherapy regimens

The regimens are described in “3.1.1.4 Common postoperative adjuvant chemotherapy regimens for colon cancer”.

4.2. Treatment principles for metastatic rectal cancer

4.2.1. Treatment principles for synchronous metastatic rectal cancer

For synchronous metastatic rectal cancer, where the primary rectal tumor and distant metastases are present at the same time, both local treatment for the primary tumor and systemic treatment for distant metastases are necessary. The order of local and systemic treatments should be decided through MDT discussions. In general, priority should be given to addressing the highest health threat, while referring to the treatment principles for metastatic colon cancer and stratifying treatment based on MMR/MS status.

Stratifications ^a				
Primary tumor	Metastatic tumor	Grade I Recommendations	Grade II Recommendations	Grade III Recommendations
Resectable, lower than moderate risk of recurrence	Resectable	Same as “3.2.1.1 Treatment principles for initially resectable metastatic colon cancer”		
	Unresectable	Same as “3.2.1.2 Treatment principles for initially unresectable metastatic colon cancer”		
Resectable, high and very high risk of recurrence	Resectable	Concurrent chemoradiotherapy ^b + systemic therapy ^c + surgery ^d	Systemic therapy ^c ± concurrent chemoradiotherapy ^b + surgery ^d	None
	Unresectable	Systemic therapy ^c MDT evaluation of resectability	Short course radiotherapy + systemic therapy ^c	None
Unresectable	Resectable	Systemic therapy ^c + concurrent chemoradiotherapy ^b MDT evaluation of resectability	Systemic therapy ^c ± radiotherapy ^b	None
	Unresectable	Systemic therapy ^c ± radiotherapy ^b	None	None

Abbreviations: MDT, multidisciplinary team.

^aThe risk assessment for local recurrence of primary rectal tumors follows the ESMO classification method. In brief, moderate risk includes very low T2, low/medium/high T3c/d, N1-2 (non-extra mesorectal spread), MRF⁻, EMVI⁻, and high risk includes very low T3, low/medium T3c/d, N1-2 (extramesorectal spread), MRF⁻, EMVI⁺, and very high risk includes very low T4, low/medium/high T3 with MRF⁺, T4b, lateral lymph node involvement. The criteria for determining the resectability of metastases are described in the colon cancer section.

^bThe information on radiotherapy is detailed in section “4.1.3 Treatment principles for rectal cancer of cT3/cT4 or N+”.

^cDetailed information on systemic chemotherapy can be found in the relevant sections on colon cancer.

^dSurgery may involve simultaneous or staged resection of the primary rectal tumor and distant metastases.

4.2.2. Treatment principles for postoperative recurrent metastatic rectal cancer

The treatment principles for postoperative recurrent metastatic rectal cancer can be informed in the section

“3.2.2 Treatments of recurrent metastatic colon cancer”. Stratified treatment based on MMR/MS status of patients should be applied.

4.2.2.1. Treatment principles for locally recurrent rectal cancer after surgery

Objectives	Grade I recommendations	Grade II recommendations	Grade III recommendations
Diagnosis of postoperative recurrence	<ul style="list-style-type: none"> Clinical symptoms^a, physical signs^b Digital rectal exam (including vaginal exam in females) Blood CEA and CA199 level Colonoscopy + biopsy^c Pelvic enhanced MRI Contrast-enhanced thoracoabdominal CT 	<ul style="list-style-type: none"> Contrast-enhanced pelvic CT Rectal endoscopic ultrasound Pelvic/perineal mass puncture biopsy^c 	<ul style="list-style-type: none"> PET/CT Surgical exploration with biopsy^c
Classifications and evaluation of postoperative recurrence	<ul style="list-style-type: none"> Comprehensive discussion with MDT^d Leeds classification^e Assessment of surgical resectability^f 		
Treatment of locally recurrent disease without distant metastasis (resectable ^f , no prior chemoradiotherapy)	<ul style="list-style-type: none"> Concurrent chemoradiotherapy, followed by surgery ± adjuvant chemotherapy Surgery (if intolerant to chemoradiotherapy) Chemotherapy alone (if intolerant to surgery) 	Surgery ± postoperative radiotherapy/chemotherapy	None
Treatment of locally recurrent disease without distant metastasis (resectable ^f , with prior chemoradiotherapy)	<ul style="list-style-type: none"> Surgery ± postoperative chemotherapy Chemotherapy alone (if intolerant to surgery) 	Palliative treatment	None
Treatment of locally recurrent disease without distant metastasis (unresectable ^f)	<ul style="list-style-type: none"> With previous chemoradiotherapy: palliative treatment Without previous chemoradiotherapy: chemoradiotherapy All patients should be evaluated for the possibility of re-resection after treatment 	Palliative treatment	None
Treatment of locally recurrent rectal cancer with distant metastasis	Refer to “4.2.1 Treatment principles for synchronous metastatic rectal cancer”		

Abbreviations: CA199, carbohydrate antigen 199; CEA, carcinoembryonic antigen; CT, computed tomography; MRI, magnetic resonance imaging; PET, positron emission tomography; MDT, multidisciplinary team.

^aLocal recurrence symptoms: Common symptoms such as pelvic or perineal pain, altered sensation, discomfort, etc. Other symptoms include rectal bleeding, increased frequency of bowel movements, and symptoms similar to primary rectal cancer. These symptoms are mainly observed in patients who have undergone anterior resection (AR) for rectal cancer.

^bLocal recurrence signs: A perineal or pelvic mass is the most common sign of local recurrence rectal cancer. In female patients, a pelvic or perineal lesion can be palpated through the vaginal exam. In patients who have undergone AR surgery, a digital rectal exam may detect lower pelvic lesions or anastomotic recurrence.

^cPost-recurrence pathological biopsy: Treatment can generally begin based on clinical and imaging findings. However, if the patient may undergo organ-destructive curative surgery (e.g., pelvic visceral clearance surgery) after diagnosis, pathological confirmation of tumor recurrence is necessary.

^dMDT evaluation of recurrence after rectal cancer surgery: In addition to routine participation in colorectal cancer MDT disciplines, other specialties such as urology, gynecology, plastic surgery, etc., may be involved based on the site of tumor recurrence.

^eLeeds classification for postoperative recurrence [186].

^fAssessment of resectability of local recurrence after rectal cancer surgery: Contraindications for surgery are detailed in section “4.2.2.1.2 Surgical contraindications for local recurrence of rectal cancer”. The central type of Leeds classification has the highest resection rate, while the lateral type has the lowest [187–192].

For more specific details on diagnostic imaging, please refer to “2.2 Basic principles for diagnosis”. For the overall diagnostic and treatment process of local recurrence after rectal cancer surgery, see “4.2.2.1.3 Diagnostic and treatment process for postoperative recurrence of rectal cancer”.

4.2.2.1.1. Leeds classification method for locally recurrent rectal cancer [186]

Anatomical types	Definitions
Central type	The lesion is confined to pelvic organs or connective tissue, without invading the bony pelvis.
Lateral wall type	The lesion involves structures of the pelvic sidewall, including the sciatic foramina and extended through this area to affect the sciatic nerve, which innervates the piriformis muscle and the glyteal region.
Sacral side type	The lesion is located in the presacral space, adherent to or invading the sacrum.
Mixed type	A combination of sacral side and lateral wall involvement.

4.2.2.1.2. Surgical contraindications for local recurrence of rectal cancer

Relative contraindications	Absolute contraindications
Presence of distant metastases	Tumor encasement of the internal iliac vessels
Initial presentation as Stage IV	Tumor extending beyond the sacrospinous ligament (i.e., extra pelvic extension through the sciatic foramina)
Extensive involvement of the pelvic sidewalls	Lower limb edema due to compression of lymphatics or veins
Anticipated R1 or R2 resection only	Bilateral ureteral obstruction or hydronephrosis
Involvement of sacrum above S2-S3 junction	Poor general condition

Abbreviations: R1, microscopic residual tumor.

4.2.2.1.3. Diagnostic and treatment process for postoperative recurrence of rectal cancer (Figure 1)

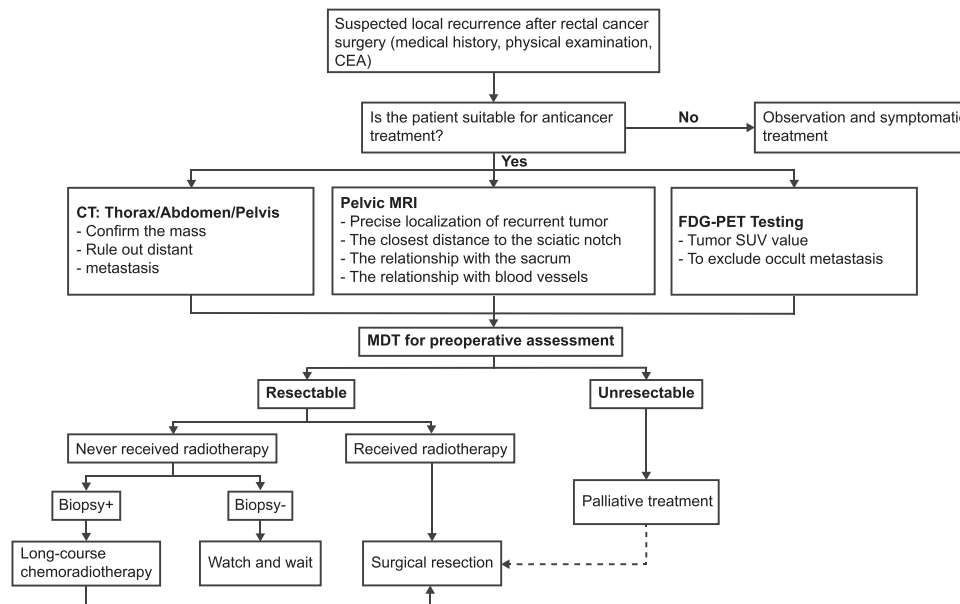


FIGURE 1 The diagnostic and treatment process for postoperative recurrence of rectal cancer. Abbreviations: CEA, carcinoembryonic antigen; CT, computed tomography; MRI, magnetic resonance imaging; FDG-PET, A fludeoxyglucose-18 (FDG)-positron emission tomography (PET); SUV, standardized uptake value; MDT, multidisciplinary team.

4.2.2.2. Treatment principles for postoperative metastatic rectal cancer

Refer to “3.2.2 Treatment of recurrent metastatic colon cancer after surgery”.

4.2.3. Follow-up for rectal cancer

Purpose ^{a,b}	Grade I recommendations	Grade II recommendations	Grade III recommendations
Postoperative follow-up of stages I-III cancer patients	<p><u>Follow-up frequency</u></p> <ul style="list-style-type: none"> • Stage I: Every 6 months for 5 years • Stages II-III: Every 3 months for 3 years; then every 6 months until 5 years postoperatively; annually after 5 years <p><u>Follow-up contents</u> (each time, unless otherwise specified)</p> <ul style="list-style-type: none"> • Physical examination, emphasizing DRE • Blood CEA testing • Liver ultrasound examination (for stages I-II) • Contrast-enhanced pelvic MRI annually • Contrast-enhanced thoracoabdominal CT annually (for stage III or in case of abnormal CEA, ultrasound) • Colonoscopy^{c,d} 	<p>Higher frequency of follow-up compared to Grade I recommendations</p> <ul style="list-style-type: none"> • Contrast-enhanced abdominal CT • Testing for previously elevated markers 	<p>None</p> <ul style="list-style-type: none"> • Liver ultrasound contrast-enhanced imaging^e • PET/CT^f
Follow-up after R0 resection/destruction of metastatic lesions in stage IV patients	<p><u>Follow-up/monitoring frequency</u>: Every 3 months for the first 3 years, then every 6 months until 5 years, annually after 5 years,</p> <p><u>Follow-up/monitoring contents</u>:</p> <ul style="list-style-type: none"> • Physical examination • Blood CEA level • Contrast-enhanced thoraco-abdominal CT and contrast-enhanced pelvic MRI every 6-12 months 	<p>Higher frequency of follow-up compared to Grade I recommendations</p> <ul style="list-style-type: none"> • Chest X-ray • Abdominal and pelvic ultrasound examination • Testing for previously elevated markers • Colonoscopy^{c,d} 	<p>None</p> <ul style="list-style-type: none"> • Liver ultrasound contrast-enhanced imaging^e • PET/CT^f

Abbreviations: CEA, carcinoembryonic antigen; CT, computed tomography; DRE, digital rectal examination; MDT, multidisciplinary team; MRI, magnetic resonance imaging; PET, positron emission tomography.

^aThe primary purpose of follow-up/monitoring is to detect recurrent or metastasis that may be treated with potentially curative intent, while also considering the cost-effectiveness from a health economics perspective. There is no high-level evidence in evidence-based medicine to support the definition of the best follow-up/monitoring strategy.

^bIf the patient’s physical condition does not allow for anticancer treatment in case of recurrence, routine tumor follow-up/monitoring is not advocated.

^cThe primary purpose of postoperative colonoscopy follow-up for rectal cancer is to detect new adenomas or multiple primary cancers. Local recurrence at the anastomosis site of higher rectal cancer is rare, while local recurrence at the anastomosis site of lower rectal cancer can be monitored by DRE.

^dStrategies for colonoscopy [147]: Colonoscopy is recommended within 1 year after surgery. If a preoperative colonoscopy cannot be performed due to tumor obstruction, a colonoscopy examination should be conducted 3-6 months after surgery. If progressive adenomas (tubulovillous adenoma with a diameter > 1 cm, or high-grade dysplasia) are found during each colonoscopy, a re-examination should be conducted within 1 year. If no progressive adenomas are found during each colonoscopy, re-examinations should be conducted within 3 years and then every 5 years.

^eIt is applicable when liver metastasis is suspected with ordinary ultrasound or CT examination.

^fPET/CT is only recommended for clinical suspicion of recurrence while routine imaging is negative, for instance, persistent elevation of CEA level. PET is not recommended as a routine follow-up/monitoring tool.

Recent studies have shown that dynamic ctDNA monitoring helps to provide early warning of postoperative recurrent metastasis [68, 69, 148], but there is still con-

trovery over whether it should be routinely used for postoperative follow-up and to guide treatment.

5. Genetic screening and diagnostic principles for hereditary colorectal cancer

Clinical assessments	Grade I recommendations	Grade II recommendations	Grade III recommendations
General principles of screening for hereditary colorectal cancer [193]	<p>All colorectal cancer patients should be asked about their family history of tumors and confirmed about bowel polyps. Patients who meet the following criteria should undergo disease-specific screening:</p> <ol style="list-style-type: none"> 1. Patients with ≥ 20 polyps throughout the colorectum or individuals in families with confirmed familial adenomatous polyposis (FAP) should undergo FAP screening [194]. 2. Patients with obvious pigmented lesions on the oral mucosa, lips, nose, cheeks, periorbital region, genitalia, extremities, perianal area, or individuals in families with confirmed Peutz-Jeghers syndrome (PJS) should undergo PJS screening. 3. Colorectal cancer patients aged ≤ 70 years should all undergo Lynch syndrome screening after excluding FAP and PJS. 	<p>Patients with ≥ 10 polyps throughout the colorectum or individuals in families with FAP should undergo FAP screening [194].</p>	<p>Colorectal cancer patients should all undergo Lynch syndrome screening after excluding FAP and PJS.</p>
Screening for FAP [195, 196]	<p>Patients with 10-20 intestinal polyps found during endoscopy should be alert to the possibility of polyposis caused by germline gene mutations. A detailed family history should be obtained. A physical examination should be performed to determine whether the patient has characteristic features such as congenital hypertrophy of the retinal pigment epithelium (CHRPE) [197], cranial osteomas [198], or the possibility of abdominal desmoid tumors [199]. The presences of CHRPE, smooth abdominal masses, or cranial osteomas suggests a high likelihood of hereditary polyposis syndrome. Regardless of family history, regular colonoscopy is recommended, and further examination should be conducted at tertiary or provincial cancer specialized hospitals.</p>	<p>For patients with ≥ 20 intestinal polyps found during endoscopy, it is essential to inquire about family history and perform cranial, abdominal, and fundus examinations. Additionally, colonoscopy may be recommended for their first-degree relatives, who should further receive consultation at tertiary or provincial cancer specialized hospitals. Regardless of family history, all patients may be recommended for FAP genetic screening [200] (see Figure 2).</p>	<p>For patients with ≥ 10 intestinal polyps found during endoscopy, a physical examination should be performed to determine whether the patient has characteristic features such as CHRPE, cranial osteomas, or the possibility of abdominal desmoid tumors. The presences of CHRPE, smooth abdominal masses, or cranial osteomas suggests a high likelihood of hereditary polyposis syndrome. Regardless of family history, it is recommended to perform regular colonoscopy and genetic screening for FAP (see Figure 2).</p>
Screening for Lynch syndrome [201–204]	<p>Patients who meet the following criteria should be highly suspected as a Lynch syndrome family and recommended for further genetic testing (see Figure 3) [205, 206]: There are at least two cases of histologically confirmed colorectal cancer in the family, of which two cases are in the relationship between parents and children or siblings (first-degree relatives), and any of the following conditions are met:</p> <ol style="list-style-type: none"> 1. At least one case is a patient with multiple colorectal cancers including adenomas. 2. At least one case of colorectal cancer occurring before the age of 50. 3. At least one case of Lynch syndrome-related extracolonic malignancy in the family, including gastric cancer, endometrial cancer, small intestine cancer, ureteral and renal pelvis cancer, ovarian cancer, and hepatobiliary system cancer [207]. 	<p>Patients with colorectal cancer aged ≤ 70 years are recommended for Lynch syndrome genetic screening (see Figure 4) [208–212].</p>	<p>All colorectal cancer patients are recommended for Lynch syndrome genetic screening (see Figure 4) [208–212].</p>

Clinical assessments	Grade I recommendations	Grade II recommendations	Grade III recommendations
Screening for PJS [213]	<ol style="list-style-type: none"> When encountering pediatric cases of intestinal intussusception or rectal bleeding of unknown causes and obvious pigmented lesions on the oral mucosa, lips, nose, cheeks, periorbital region, genitalia, extremities, or perianal area, a family history should be inquired, and the possibility of PJS should be alerted. Patient should be advised to seek medical consultation at tertiary or provincial cancer specialized hospitals. When obvious pigmented lesions are found on the oral mucosa, lips, nose, cheeks, periorbital region, genitalia, extremities, or perianal area in adults, a family history should be inquired, and gastroenterography or intestinal endoscopy should be recommended. If intestinal polyps are found or there is a family history of tumors, the patient should seek medical consultation at tertiary or provincial cancer specialized hospitals. 	When obvious pigmented lesions are found on the oral mucosa, lips, nose, cheeks, periorbital region, genitalia, extremities, or perianal area in adults, a family history should be inquired, and gastroenterography should be recommended. If small intestinal polyps are found or there is a family history of tumors, <i>STK11</i> gene mutation testing should be conducted [214].	None
Management strategies after genetic screening	<ol style="list-style-type: none"> Carriers of FAP gene mutations [215]: <ol style="list-style-type: none"> Undergo colonoscopy annually from the age of 10-15. If advanced dysplasia is found in the polyps, prophylactic colorectal resection surgery may be recommended based on the number and distribution of polyps. Carriers of Lynch syndrome genetic mutations [23]: <ol style="list-style-type: none"> <i>MLH1</i> or <i>MSH2</i> mutation carriers: Undergo colonoscopy every 1-2 years from the age of 20-25; <i>MSH6</i> or <i>PMS2</i> mutation carriers: Undergo colonoscopy every 1-2 years from the age of 25-30. Undergo esophagogastroduodenoscopy every 1-2 years from the age of 30-35. For women who have given birth, prophylactic hysterectomy and bilateral salpingo-oophorectomy may be considered; those who have not undergone prophylactic surgery should undergo endometrial biopsy every 1-2 years to rule out the risk of endometrial cancer when asymptomatic, and should undergo regular vaginal ultrasound and serum CA125 testing to exclude the risk of ovarian cancer. For families with confirmed pathogenic germline mutations, carriers of mutations should follow the above scheme for follow-up, and non-carriers of mutations may undergo general population screening. For families with unclear germline gene mutations, it is recommended to discuss with the physician and decide on a recheck and follow-up strategy based on family history and clinical manifestations. 	None	None

Abbreviations: CHRPE, congenital hypertrophy of the retinal pigment epithelium; FAP, familial adenomatous polyposis; PJS, Peutz-Jeghers syndrome; *STK11*, serine/threonine kinase 11; *MSH2*, mutS homolog 2; *MLH1*, mutL homolog 1; *MSH6*, mutS homolog 6; *PMS2*, postmeiotic segregation increased 2; CA125, carbohydrate antigen 125.

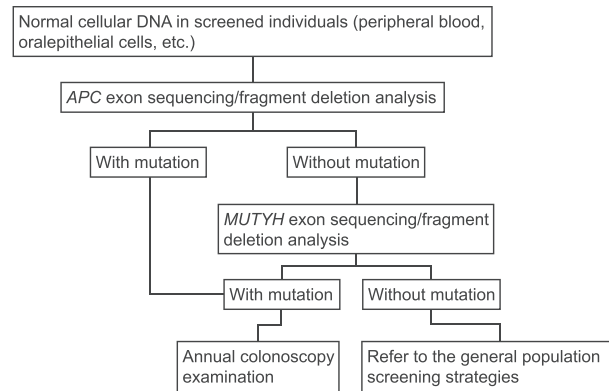


FIGURE 2 Familial adenomatous polyposis genetic testing process. Abbreviations: *APC*, adenomatous polyposis coli; *MUTYH*, mutY DNA glycosylase.

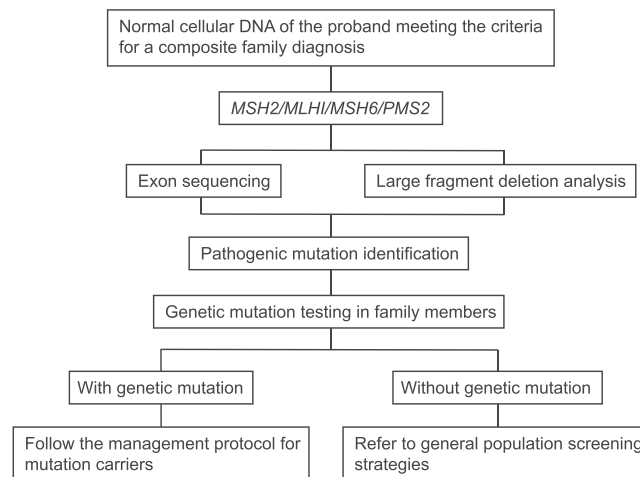


FIGURE 3 Lynch syndrome familial hereditary genetic testing scheme 1. Abbreviations: *MSH2*, mutS homolog 2; *MLH1*, mutL homolog 1; *MSH6*, mutS homolog 6; *PMS2*, postmeiotic segregation increased 2.

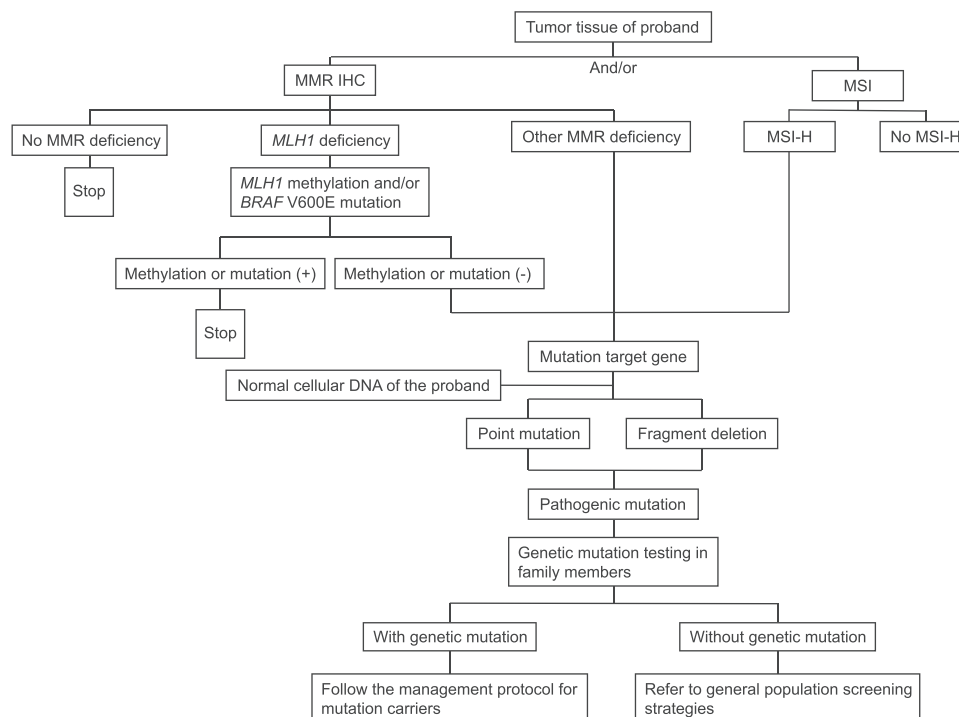


FIGURE 4 Lynch syndrome familial hereditary genetic testing scheme 2. Abbreviations: *BRAF*, v-ras murine sarcoma viral oncogene homolog B; MSI-H, microsatellite instability-high; MMR, mismatch repair; IHC, Immunohistochemistry; *MLH1*, mutL homolog 1.

DECLARATIONS

AUTHOR CONTRIBUTIONS

Conception and design of the guidelines: all authors; Final approval of manuscript: all authors.

AFFILIATIONS

¹Department of Medical Oncology, Sun Yat-sen University Cancer Center, The State Key Laboratory of Oncology in South China, Guangdong Provincial Clinical Research Center for Cancer, Research Unit of Precision Diagnosis and Treatment for Gastrointestinal Cancer, Chinese Academy of Medical Sciences, Guangzhou, Guangdong, P. R. China

²Department of Colorectal Surgery, Sun Yat-sen University Cancer Center, The State Key Laboratory of Oncology in South China, Guangdong Provincial Clinical Research Center for Cancer, Guangzhou, Guangdong, P. R. China

³Department of Radiation Oncology, Fudan University Shanghai Cancer Center, Shanghai, P. R. China

⁴Department of Medical Oncology, The Second Affiliated Hospital, Zhejiang University School of Medicine, Hangzhou, Zhejiang, P. R. China

⁵Department of Radiology, Peking University People's Hospital, Beijing, P. R. China

⁶Department of Radiation Oncology, Sun Yat-sen University Cancer Center, The State Key Laboratory of Oncology in South China, Guangzhou, Guangdong, P. R. China

⁷Department of Pathology, Fudan University Shanghai Cancer Center, Shanghai, P. R. China

⁸Department of Colorectal Surgery, Fudan University Shanghai Cancer Center, Shanghai, P. R. China

⁹Department of Oncology, Tongji Hospital, Tongji Medical College, Huazhong University of Science and Technology, Wuhan, Hubei, P. R. China

¹⁰Department of General Surgery, Zhongshan Hospital, Fudan University, Shanghai, P. R. China

¹¹Department of Medical Oncology, The First Hospital of China Medical University, Shenyang, Liaoning, P. R. China

¹²Department of Oncology, Harbin Medical University Cancer Hospital, Harbin, Heilongjiang, P. R. China

¹³Department of Oncology, Southwest Hospital, Third Military Medical University (Army Medical University), Chongqing, P. R. China

¹⁴Department of Gastrointestinal Oncology, Cancer Medical Center, Peking Union Medical College Hospital, Chinese Academy of Medical Sciences, Beijing, China

¹⁵Department of Medical Oncology, Chinese Academy of Medical Sciences and Peking Union Medical College, Beijing, P. R. China

¹⁶Department of Pathology, Chinese Academy of Medical Sciences and Peking Union Medical College, Beijing, P. R. China

¹⁷Department of Pathology, Sun Yat-sen University Cancer Center, The State Key Laboratory of Oncology in South China, Guangzhou, Guangdong, P. R. China

¹⁸Department of Gastrointestinal Surgery, Xijing Hospital, Air Force Military Medical University, Xi'an, Shaanxi, P. R. China

¹⁹Department of General Surgery, The First Affiliated Hospital of Nanchang University, Nanchang, Jiangxi, P. R. China

²⁰Department of Radiology, The First Hospital of Jilin University, Changchun, Jilin, P. R. China

²¹Department of Medical Oncology, The First Affiliated Hospital of Xi'an Jiaotong University, Xi'an, Shaanxi, P. R. China

²²Department of Radiology, Second Affiliated Hospital, Zhejiang University School of Medicine, Hangzhou, Zhejiang, P. R. China

²³Department of Colorectal Surgery, The Second Affiliated Hospital, Zhejiang University School of Medicine, Hangzhou, Zhejiang, P. R. China

²⁴Department of Medical Oncology, Shanghai GoBroad Cancer Hospital, China Pharmaceutical University, Shanghai, P. R. China

²⁵Department of Medical Oncology, Sun Yat-sen University Cancer Center, The State Key Laboratory of Oncology in South China, Guangdong Provincial Clinical Research Center for Cancer, Sun Yat-sen University, Research Unit of Precision Diagnosis and Treatment for Gastrointestinal Cancer, Chinese Academy of Medical Sciences, Guangzhou, Guangdong, P. R. China

ACKNOWLEDGMENTS

We thank Dr. Zixin Qin (ORCID: 0000-0002-4435-8106) from the Sun Yat-sen University Cancer Center for translating and revising this guideline.

CONFLICT OF INTEREST STATEMENT

The authors declare that they have no competing interests.

FUNDING INFORMATION

Not applicable.

DATA AVAILABILITY STATEMENT

Not applicable.

ETHICS APPROVAL AND CONSENT TO PARTICIPATE

Not applicable.

CONSENT FOR PUBLICATION

This paper was first published in Chinese by the Beijing: People's Medical Publishing House, entitled the "Guideline of Chinese Society of Clinical Oncology (CSCO): Colorectal Cancer. 2024" from the Committee on Guidelines of the Chinese Society of Clinical Oncology. With appropriate permission, this English version is published in *Cancer Communications*.

ORCID

Feng Wang  <https://orcid.org/0000-0001-7668-9674>

Ying Yuan  <https://orcid.org/0000-0002-3922-9553>

Zixian Wang  <https://orcid.org/0000-0002-7950-787X>

Jianmin Xu  <https://orcid.org/0000-0001-5441-8240>

Houjie Liang  <https://orcid.org/0000-0002-5924-7783>

Muyan Cai  <https://orcid.org/0000-0002-4646-4391>

Rui-Hua Xu  <https://orcid.org/0000-0001-9771-8534>

REFERENCES

1. Cai SR, Huang YQ, Zhang SZ, Li QR, Ma XY, Zheng S. Effects of subitems in the colorectal cancer screening protocol on the Chinese colorectal cancer screening program: an analysis

based on natural community screening results. *BMC Cancer*. 2019;19(1):47.

2. Chen H, Lu M, Liu C, Zou S, Du L, Liao X, et al. Comparative Evaluation of Participation and Diagnostic Yield of Colonoscopy vs Fecal Immunochemical Test vs Risk-Adapted Screening in Colorectal Cancer Screening: Interim Analysis of a Multicenter Randomized Controlled Trial (TARGET-C). *Am J Gastroenterol*. 2020;115(8):1264–74.
3. Li QL, Ma XY, Yu LL, Xue F, Ma WL, Yao KY. [Age-specific detection rates of colorectal neoplasms by colonoscopic screening in high-incidence rural area]. *Zhonghua Zhong Liu Za Zhi*. 2013;35(2):154–7.
4. Sung JJ, Ng SC, Chan FK, Chiu HM, Kim HS, Matsuda T, et al. An updated Asia Pacific Consensus Recommendations on colorectal cancer screening. *Gut*. 2015;64(1):121–32.
5. Tao S, Hoffmeister M, Brenner H. Development and validation of a scoring system to identify individuals at high risk for advanced colorectal neoplasms who should undergo colonoscopy screening. *Clin Gastroenterol Hepatol*. 2014;12(3):478–85.
6. Huang Y, Li Q, Ge W, Cai S, Zhang S, Zheng S. Predictive power of quantitative and qualitative fecal immunochemical tests for hemoglobin in population screening for colorectal neoplasm. *Eur J Cancer Prev*. 2014;23(1):27–34.
7. Lee JK, Liles EG, Bent S, Levin TR, Corley DA. Accuracy of fecal immunochemical tests for colorectal cancer: systematic review and meta-analysis. *Ann Intern Med*. 2014;160(3):171.
8. Cai SR, Zhu HH, Huang YQ, Li QL, Ma XY, Zhang SZ, et al. Cost-Effectiveness between Double and Single Fecal Immunochemical Test(s) in a Mass Colorectal Cancer Screening. *Biomed Res Int*. 2016;2016:6830713.
9. Chen WQ, Li N, Lan P, Chen HD, Du LB, Sun F, et al. China guideline for the screening, early detection and early treatment of colorectal cancer (2020, Beijing). *China Cancer*. 2021;30(01):1–28.
10. Early Diagnosis and Early Treatment Group of the Oncology Branch of the Chinese Medical Association (CMA). Expert consensus on early diagnosis and treatment of colorectal cancer in China. *Chin Med J (Engl)*. 2020;100(22):1691–8.
11. National Clinical Research Center for Digestive Diseases, National Alliance for Early Diagnosis and Treatment of Digestive Tract Cancers, Digestive Endoscopy Society of Chinese Medical Association, Health Management Society of Chinese Medical Association, Digestive Endoscopy Professional Committee of the Endoscopy Physicians Branch of Chinese Medical Doctor Association, Endoscopic Health Management and Physical Examination Professional Committee of the Endoscopy Physicians Branch of Chinese Medical Doctor Association, et al. Expert consensus opinion on early colorectal cancer screening process in China (2019, Shanghai). *Chin J Dig Endosc*. 2019;36(10):709–19.
12. Colorectal Cancer Professional Committee of the Chinese Anti-Cancer Association, Expert Committee for Consensus on Early Diagnosis and Screening for Colorectal Cancer in China. Expert consensus on early diagnosis and screening strategies for colorectal tumours in China. *Chin J Gastrointest Surg*. 2018;21(10):1081–6.
13. Chinese Society Of Gastroenterology. Consensus opinion on colorectal tumour screening, early diagnosis and treatment and

- comprehensive prevention in China. *J Gastroenterol Hepatol.* 2011;20(11):979–95.
14. Imperiale TF, Ransohoff DF, Itzkowitz SH, Levin TR, Lavin P, Lidgard GP, et al. Multitarget stool DNA testing for colorectal-cancer screening. *N Engl J Med.* 2014;370(14):1287–97.
 15. Lin JS, Piper MA, Perdue LA, Rutter CM, Webber EM, O'Connor E, et al. Screening for Colorectal Cancer: Updated Evidence Report and Systematic Review for the US Preventive Services Task Force. *JAMA.* 2016;315(23):2576–94.
 16. Gupta S, Lieberman D, Anderson JC, Burke CA, Dominitz JA, Kaltenbach T, et al. Recommendations for Follow-Up After Colonoscopy and Polypectomy: A Consensus Update by the US Multi-Society Task Force on Colorectal Cancer. *Gastroenterology.* 2020;158(4):1131–53 e5.
 17. Facciorusso A, Di Maso M, Serviddio G, Vendemiale G, Spada C, Costamagna G, et al. Factors Associated With Recurrence of Advanced Colorectal Adenoma After Endoscopic Resection. *Clin Gastroenterol Hepatol.* 2016;14(8):1148–54 e4.
 18. Cubiella J, Carballo F, Portillo I, Cruzado Quevedo J, Salas D, Binefa G, et al. Incidence of advanced neoplasia during surveillance in high- and intermediate-risk groups of the European colorectal cancer screening guidelines. *Endoscopy.* 2016;48(11):995–1002.
 19. Li J, Yuan Y, Yang F, Wang Y, Zhu X, Wang Z, et al. Expert consensus on multidisciplinary therapy of colorectal cancer with lung metastases (2019 edition). *J Hematol Oncol.* 2019;12(1):16.
 20. van 't Sant I, Engbersen MP, Bhairosing PA, Lambregts DMJ, Beets-Tan RGH, van Driel WJ, et al. Diagnostic performance of imaging for the detection of peritoneal metastases: a meta-analysis. *Eur Radiol.* 2020;30(6):3101–12.
 21. Tsili AC, Alexiou G, Naka C, Argyropoulou MI. Imaging of colorectal cancer liver metastases using contrast-enhanced US, multidetector CT, MRI, and FDG PET/CT: a meta-analysis. *Acta Radiol.* 2021;62(3):302–12.
 22. Muaddi H, Silva S, Choi WJ, Coburn N, Hallet J, Law C, et al. When is a Ghost Really Gone? A Systematic Review and Meta-analysis of the Accuracy of Imaging Modalities to Predict Complete Pathological Response of Colorectal Cancer Liver Metastases After Chemotherapy. *Ann Surg Oncol.* 2021;28(11):6805–13.
 23. Moulton C-A, Gu C-S, Law CH, Tandan VR, Hart R, Quan D, et al. Effect of PET Before Liver Resection on Surgical Management for Colorectal Adenocarcinoma Metastases: A Randomized Clinical Trial. *JAMA.* 2014;311(18):1863–9.
 24. Fernandes MC, Gollub MJ, Brown G. The importance of MRI for rectal cancer evaluation. *Surg Oncol.* 2022;43:101739.
 25. O'Connell E, Galvin R, McNamara DA, Burke JP. The utility of preoperative radiological evaluation of early rectal neoplasia: a systematic review and meta-analysis. *Colorectal Dis.* 2020;22(9):1076–84.
 26. Roodbeen SX, de Lacy FB, van Dieren S, Penna M, Ris F, Moran B, et al. Predictive Factors and Risk Model for Positive Circumferential Resection Margin Rate After Transanal Total Mesorectal Excision in 2653 Patients With Rectal Cancer. *Ann Surg.* 2019;270(5):884–91.
 27. Lambregts DMJ, Bogveradze N, Blomqvist LK, Fokas E, Garcia-Aguilar J, Glimelius B, et al. Current controversies in TNM for the radiological staging of rectal cancer and how to deal with them: results of a global online survey and multidisciplinary expert consensus. *Eur Radiol.* 2022;32(7):4991–5003.
 28. Al-Sukhni E, Milot L, Fruitman M, Beyene J, Victor JC, Schmocker S, et al. Diagnostic accuracy of MRI for assessment of T category, lymph node metastases, and circumferential resection margin involvement in patients with rectal cancer: a systematic review and meta-analysis. *Ann Surg Oncol.* 2012;19(7):2212–23.
 29. Laparoscopic Surgery Committee of the Endoscopist Branch in the Chinese Medical Doctor Association (CMDA), Laparoscopic Surgery Committee of Colorectal Cancer Committee of Chinese Medical Doctor Association (CMDA), Colorectal Surgery Group of the Surgery Branch in the Chinese Medical Association (CMA), Chinese Anti-Cancer Association Colorectal Tumor Integrated Rehabilitation Committee, China International Exchange and Promotive Association for Medical and Health Care Colorectal Disease Branch, Zhou Zongguang, et al. Chinese expert consensus on the diagnosis and treatment for lateral lymph node metastasis of rectal cancer (2024 edition). *Chin J Gastrointest Surg.* 2024;27(1):1–14.
 30. Rooney S, Meyer J, Afzal Z, Ashcroft J, Cheow H, De Paepe KN, et al. The Role of Preoperative Imaging in the Detection of Lateral Lymph Node Metastases in Rectal Cancer: A Systematic Review and Diagnostic Test Meta-analysis. *Dis Colon Rectum.* 2022;65(12):1436–46.
 31. Rouleau Fournier F, Motamedi MAK, Brown CJ, Phang T, Raval MJ, Hague CJ, et al. Oncologic Outcomes Associated With MRI-detected Extramural Venous Invasion (mrEMVI) in Rectal Cancer: A Systematic Review and Meta-analysis. *Ann Surg.* 2022;275(2):303–14.
 32. Benson AB, Venook AP, Al-Hawary MM, Cederquist L, Chen YJ, Ciombor KK, et al. Rectal Cancer, Version 2.2018, NCCN Clinical Practice Guidelines in Oncology. *J Natl Compr Canc Netw.* 2018;16(7):874–901.
 33. Hashiguchi Y, Muro K, Saito Y, Ito Y, Ajioka Y, Hamaguchi T, et al. Japanese Society for Cancer of the Colon and Rectum (JSCCR) guidelines 2019 for the treatment of colorectal cancer. *Int J Clin Oncol.* 2020;25(1):1–42.
 34. Lord AC, Corr A, Chandramohan A, Hodges N, Pring E, Airo-Farulla C, et al. Assessment of the 2020 NICE criteria for preoperative radiotherapy in patients with rectal cancer treated by surgery alone in comparison with proven MRI prognostic factors: a retrospective cohort study. *Lancet Oncol.* 2022;23(6):793–801.
 35. Battersby NJ, How P, Moran B, Stelzner S, West NP, Branagan G, et al. Prospective Validation of a Low Rectal Cancer Magnetic Resonance Imaging Staging System and Development of a Local Recurrence Risk Stratification Model: The MERCURY II Study. *Ann Surg.* 2016;263(4):751–60.
 36. Chen K, She HL, Wu T, Hu F, Li T, Luo LP. Comparison of percentage changes in quantitative diffusion parameters for assessing pathological complete response to neoadjuvant therapy in locally advanced rectal cancer: a meta-analysis. *Abdom Radiol (NY).* 2021;46(3):894–908.
 37. Feng L, Liu Z, Li C, Li Z, Lou X, Shao L, et al. Development and validation of a radiopathomics model to predict pathological complete response to neoadjuvant chemoradiotherapy in locally advanced rectal cancer: a multicentre observational study. *Lancet Digit Health.* 2022;4(1):e8–e17.

38. Du D, Su Z, Wang D, Liu W, Wei Z. Optimal Interval to Surgery After Neoadjuvant Chemoradiotherapy in Rectal Cancer: A Systematic Review and Meta-analysis. *Clin Colorectal Cancer*. 2018;17(1):13–24.
39. Bates DDB, Homsí ME, Chang KJ, Lalwani N, Horvat N, Sheedy SP. MRI for Rectal Cancer: Staging, mrCRM, EMVI, Lymph Node Staging and Post-Treatment Response. *Clin Colorectal Cancer*. 2022;21(1):10–8.
40. Chen S, Li N, Tang Y, Shi J, Zhao Y, Ma H, et al. The prognostic value of MRI-detected extramural vascular invasion (mrEMVI) for rectal cancer patients treated with neoadjuvant therapy: a meta-analysis. *Eur Radiol*. 2021;31(12):8827–37.
41. Cercek A, Lumish M, Sinopoli J, Weiss J, Shia J, Lamendola-Essel M, et al. PD-1 Blockade in Mismatch Repair-Deficient, Locally Advanced Rectal Cancer. *N Engl J Med*. 2022;386(25):2363–76.
42. Cooper HS. Pathology of the endoscopically removed malignant colorectal polyp. *Current Diagnostic Pathol*. 2007;13(6):423–37.
43. Lee VWK, Chan KF. Tumor budding and poorly-differentiated cluster in prognostication in Stage II colon cancer. *Pathol Res Pract*. 2018;214(3):402–7.
44. Romiti A, Roberto M, Marchetti P, Di Cerbo A, Falcone R, Campisi G, et al. Study of histopathologic parameters to define the prognosis of stage II colon cancer. *Int J Colorectal Dis*. 2019;34(5):905–13.
45. Costas-Chavarri A, Nandakumar G, Temin S, Lopes G, Cervantes A, Cruz Correa M, et al. Treatment of Patients With Early-Stage Colorectal Cancer: ASCO Resource-Stratified Guideline. *J Glob Oncol*. 2019;5:1–19.
46. Pai RK, Cheng YW, Jakubowski MA, Shadrach BL, Plesec TP, Pai RK. Colorectal carcinomas with submucosal invasion (pT1): analysis of histopathological and molecular factors predicting lymph node metastasis. *Mod Pathol*. 2017;30(1):113–22.
47. Lugli A, Kirsch R, Ajioka Y, Bosman F, Cathomas G, Dawson H, et al. Recommendations for reporting tumor budding in colorectal cancer based on the International Tumor Budding Consensus Conference (ITBCC) 2016. *Mod Pathol*. 2017;30(9):1299–311.
48. Benson AB, Venook AP, Al-Hawary MM, Azad N, Chen Y-J, Ciombor KK, et al. Rectal Cancer, Version 2.2022, NCCN Clinical Practice Guidelines in Oncology. *J Natl Compr Cancer Netw*. 2022;20(10):1139–67.
49. Parfitt JR, Driman DK. The total mesorectal excision specimen for rectal cancer: a review of its pathological assessment. *J Clin Pathol*. 2007;60(8):849–55.
50. WHO Classification of Tumours Editorial Board. WHO Classification of Tumours: Digestive System Tumours. 5th ed. 2019.
51. Nagtegaal ID, Marijnen CAM, Kranenbarg EK, van de Velde CJH, van Krieken JHJM, Pathology Review C, et al. Circumferential margin involvement is still an important predictor of local recurrence in rectal carcinoma: not one millimeter but two millimeters is the limit. *Am J Surg Pathol*. 2002;26(3):350–7.
52. Amin MB, Edge SB, Greene FL, Byrd DR, Brookland RK, Washington MK, et al. *AJCC Cancer Staging Manual*. 8 ed: Springer Cham; 2016;XVII:1032.
53. Sepulveda AR, Hamilton SR, Allegra CJ, Grody W, Cushman-Vokoun AM, Funkhouser WK, et al. Molecular Biomarkers for the Evaluation of Colorectal Cancer: Guideline From the American Society for Clinical Pathology, College of American Pathologists, Association for Molecular Pathology, and the American Society of Clinical Oncology. *J Clin Oncol*. 2017;35(13):1453–86.
54. Qin S, Li J, Wang L, Xu J, Cheng Y, Bai Y, et al. Efficacy and Tolerability of First-Line Cetuximab Plus Leucovorin, Fluorouracil, and Oxaliplatin (FOLFOX-4) Versus FOLFOX-4 in Patients With RAS Wild-Type Metastatic Colorectal Cancer: The Open-Label, Randomized, Phase III TAILOR Trial. *J Clin Oncol*. 2018;36(30):3031–9.
55. Kopetz S, Grothey A, Yaeger R, Cutsem EV, Desai J, Yoshino T, et al. Encorafenib, Binimetinib, and Cetuximab in BRAF V600E-Mutated Colorectal Cancer. *N Engl J Med*. 2019;381(17):1632–43.
56. Guo TA, Wu YC, Tan C, Jin YT, Sheng WQ, Cai SJ, et al. Clinicopathologic features and prognostic value of KRAS, NRAS and BRAF mutations and DNA mismatch repair status: A single-center retrospective study of 1,834 Chinese patients with Stage I-IV colorectal cancer. *Int J Cancer*. 2019;145(6):1625–34.
57. Sinicrpe FA, Shi Q, Smyrk TC, Thibodeau SN, Dienstmann R, Guinney J, et al. Molecular markers identify subtypes of stage III colon cancer associated with patient outcomes. *Gastroenterology*. 2015;148(1):88–99.
58. Gavin PG, Colangelo LH, Fumagalli D, Tanaka N, Remillard MY, Yothers G, et al. Mutation profiling and microsatellite instability in stage II and III colon cancer: an assessment of their prognostic and oxaliplatin predictive value. *Clin Cancer Res*. 2012;18(23):6531–41.
59. Benson AB, Venook AP, Al-Hawary MM, Arain MA, Chen Y-J, Ciombor KK, et al. Colon Cancer, Version 2.2021, NCCN Clinical Practice Guidelines in Oncology. *J Natl Compr Cancer Netw*. 2021;19(3):329–59.
60. Li MM, Datto M, Duncavage EJ, Kulkarni S, Lindeman NI, Roy S, et al. Standards and Guidelines for the Interpretation and Reporting of Sequence Variants in Cancer: A Joint Consensus Recommendation of the Association for Molecular Pathology, American Society of Clinical Oncology, and College of American Pathologists. *J Mol Diagn*. 2017;19(1):4–23.
61. Panel Members of Expert Consensus on Molecular Testing for Colorectal Cancer. Expert consensus on molecular testing for colorectal cancer. *Chinese Journal of Pathology*. 2018;47(4):237–40.
62. Sartore-Bianchi A, Trusolino L, Martino C, Bencardino K, Lonardi S, Bergamo F, et al. Dual-targeted therapy with trastuzumab and lapatinib in treatment-refractory, KRAS codon 12/13 wild-type, HER2-positive metastatic colorectal cancer (HERACLES): a proof-of-concept, multicentre, open-label, phase 2 trial. *Lancet Oncol*. 2016;17(6):738–46.
63. Hechtman JF, Benayed R, Hyman DM, Drilon A, Zehir A, Frosina D, et al. Pan-Trk Immunohistochemistry Is an Efficient and Reliable Screen for the Detection of NTRK Fusions. *Am J Surg Pathol*. 2017;41(11):1547–51.
64. Solomon JP, Linkov I, Rosado A, Mullaney K, Rosen EY, Frosina D, et al. NTRK fusion detection across multiple assays and 33,997 cases: diagnostic implications and pitfalls. *Mod Pathol*. 2020;33(1):38–46.
65. Forgo E, Gomez AJ, Steiner D, Zehnder J, Longacre TA. Morphological, immunophenotypical and molecular features

- of hypermutation in colorectal carcinomas with mutations in DNA polymerase epsilon (POLE). *Histopathology*. 2020;76(3):366–74.
66. Ma X, Riaz N, Samstein RM, Lee M, Makarov V, Valero C, et al. Functional landscapes of POLE and POLD1 mutations in checkpoint blockade-dependent antitumor immunity. *Nat Genet*. 2022;54(7):996–1012.
 67. Kelly RJ, Bever K, Chao J, Ciombor KK, Eng C, Fakih M, et al. Society for Immunotherapy of Cancer (SITC) clinical practice guideline on immunotherapy for the treatment of gastrointestinal cancer. *J Immunother Cancer*. 2023;11(6).
 68. Reinert T, Henriksen TV, Christensen E, Sharma S, Salari R, Sethi H, et al. Analysis of Plasma Cell-Free DNA by Ultradeep Sequencing in Patients With Stages I to III Colorectal Cancer. *JAMA Oncol*. 2019;5(8):1124–31.
 69. Chen G, Peng J, Xiao Q, Wu HX, Wu X, Wang F, et al. Postoperative circulating tumor DNA as markers of recurrence risk in stages II to III colorectal cancer. *J Hematol Oncol*. 2021;14(1):80.
 70. Henriksen TV, Tarazona N, Frydendahl A, Reinert T, Gimeno-Vallente F, Carbonell-Asins JA, et al. Circulating Tumor DNA in Stage III Colorectal Cancer, beyond Minimal Residual Disease Detection, toward Assessment of Adjuvant Therapy Efficacy and Clinical Behavior of Recurrences. *Clin Cancer Res*. 2022;28(3):507–17.
 71. Tie J, Cohen JD, Lahouel K, Lo SN, Wang Y, Kosmider S, et al. Circulating Tumor DNA Analysis Guiding Adjuvant Therapy in Stage II Colon Cancer. *N Engl J Med*. 2022;386(24):2261–72.
 72. Fujiya M, Tanaka K, Dokoshi T, Tominaga M, Ueno N, Inaba Y, et al. Efficacy and adverse events of EMR and endoscopic submucosal dissection for the treatment of colon neoplasms: a meta-analysis of studies comparing EMR and endoscopic submucosal dissection. *Gastrointest Endosc*. 2015;81(3):583–95.
 73. De Ceglie A, Hassan C, Mangiavillano B, Matsuda T, Saito Y, Ridola L, et al. Endoscopic mucosal resection and endoscopic submucosal dissection for colorectal lesions: A systematic review. *Crit Rev Oncol Hematol*. 2016;104:138–55.
 74. Ferlitsch M, Moss A, Hassan C, Bhandari P, Dumonceau JM, Paspatis G, et al. Colorectal polypectomy and endoscopic mucosal resection (EMR): European Society of Gastrointestinal Endoscopy (ESGE) Clinical Guideline. *Endoscopy*. 2017;49(3):270–97.
 75. Ribeiro MS, Wallace MB. Endoscopic Treatment of Early Cancer of the Colon. *Gastroenterol Hepatol (NY)*. 2015;11(7):445–52.
 76. Tanaka S, Kashida H, Saito Y, Yahagi N, Yamano H, Saito S, et al. JGES guidelines for colorectal endoscopic submucosal dissection/endoscopic mucosal resection. *Dig Endosc*. 2015;27(4):417–34.
 77. Watanabe T, Muro K, Ajioka Y, Hashiguchi Y, Ito Y, Saito Y, et al. Japanese Society for Cancer of the Colon and Rectum (JSCCR) guidelines 2016 for the treatment of colorectal cancer. *Int J Clin Oncol*. 2018;23(1):1–34.
 78. Cooper HS, Deppisch LM, Gourley WK, Kahn EI, Lev R, Manley PN, et al. Endoscopically removed malignant colorectal polyps: clinicopathologic correlations. *Gastroenterology*. 1995;108(6):1657–65.
 79. Markowitz AJ, Winawer SJ. Management of colorectal polyps. *CA Cancer J Clin*. 1997;47(2):93–112.
 80. Yoshii S, Nojima M, Noshio K, Omori S, Kusumi T, Okuda H, et al. Factors associated with risk for colorectal cancer recurrence after endoscopic resection of T1 tumors. *Clin Gastroenterol Hepatol*. 2014;12(2):292–302 e3.
 81. Cooper HS. Surgical pathology of endoscopically removed malignant polyps of the colon and rectum. *Am J Surg Pathol*. 1983;7(7):613–23.
 82. Hassan C, Zullo A, Risio M, Rossini FP, Morini S. Histologic risk factors and clinical outcome in colorectal malignant polyp: a pooled-data analysis. *Dis Colon Rectum*. 2005;48(8):1588–96.
 83. Seitz U, Bohnacker S, Seewald S, Thonke F, Brand B, Bräutigam T, et al. Is Endoscopic Polypectomy an Adequate Therapy for Malignant Colorectal Adenomas? Presentation of 114 Patients and Review of the Literature. *Diseases of the Colon & Rectum*. 2004;47(11):1789–97.
 84. Volk EE, Goldblum JR, Petras RE, Carey WD, Fazio VW. Management and outcome of patients with invasive carcinoma arising in colorectal polyps. *Gastroenterology*. 1995;109(6):1801–7.
 85. Cranley JP, Petras RE, Carey WD, Paradis K, Sivak MV. When is endoscopic polypectomy adequate therapy for colonic polyps containing invasive carcinoma? *Gastroenterology*. 1986;91(2):419–27.
 86. Haggitt RC, Glotzbach RE, Soffer EE, Wruble LD. Prognostic factors in colorectal carcinomas arising in adenomas: implications for lesions removed by endoscopic polypectomy. *Gastroenterology*. 1985;89(2):328–36.
 87. Hu H, Kang L, Zhang J, Wu Z, Wang H, Huang M, et al. Neoadjuvant PD-1 blockade with toripalimab, with or without celecoxib, in mismatch repair-deficient or microsatellite instability-high, locally advanced, colorectal cancer (PICC): a single-centre, parallel-group, non-comparative, randomised, phase 2 trial. *Lancet Gastroenterol Hepatol*. 2022;7(1):38–48.
 88. Chalabi M, Verschoor YL, Tan PB, Balduzzi S, Van Lent AU, Grootsholten C, et al. Neoadjuvant Immunotherapy in Locally Advanced Mismatch Repair-Deficient Colon Cancer. *N Engl J Med*. 2024;390(21):1949–58.
 89. Cohen AM. Surgical considerations in patients with cancer of the colon and rectum. *Semin Oncol*. 1991;18(4):381–7.
 90. West NP, Hohenberger W, Weber K, Perrakis A, Finan PJ, Quirke P. Complete mesocolic excision with central vascular ligation produces an oncologically superior specimen compared with standard surgery for carcinoma of the colon. *J Clin Oncol*. 2010;28(2):272–8.
 91. Berger AC, Sigurdson ER, LeVoyer T, Hanlon A, Mayer RJ, Macdonald JS, et al. Colon cancer survival is associated with decreasing ratio of metastatic to examined lymph nodes. *J Clin Oncol*. 2005;23(34):8706–12.
 92. Huang X, Lv B, Zhang S, Meng L. Preoperative colonic stents versus emergency surgery for acute left-sided malignant colonic obstruction: a meta-analysis. *J Gastrointest Surg*. 2014;18(3):584–91.
 93. Tournigand C, André T, Bonnetain F, Chibaudel B, Lledo G, Hickish T, et al. Adjuvant therapy with fluorouracil and oxaliplatin in stage II and elderly patients (between ages 70 and 75 years) with colon cancer: subgroup analyses of the Multicenter International Study of Oxaliplatin, Fluorouracil, and Leucovorin in the Adjuvant Treatment of Colon Cancer trial. *J Clin Oncol*. 2012;30(27):3353–60.
 94. Sargent DJ, Marsoni S, Monges G, Thibodeau SN, Labianca R, Hamilton SR, et al. Defective mismatch repair as a predic-

- tive marker for lack of efficacy of fluorouracil-based adjuvant therapy in colon cancer. *J Clin Oncol.* 2010;28(20):3219–26.
95. Grothey A, Sobrero AF, Shields AF, Yoshino T, Paul J, Taieb J, et al. Duration of Adjuvant Chemotherapy for Stage III Colon Cancer. *N Engl J Med.* 2018;378(13):1177–88.
 96. Iveson T, Sobrero AF, Yoshino T, Sougklakos I, Ou F-S, Meyers JP, et al. Prospective pooled analysis of four randomized trials investigating duration of adjuvant (adj) oxaliplatin-based therapy (3 vs 6 months {m}) for patients (pts) with high-risk stage II colorectal cancer (CC). *J Clin Oncol.* 2019;37(15_suppl):3501-.
 97. Chibaudel B, Tournigand C, Bonnetain F, Richa H, Benetkiewicz M, Andre T, et al. Therapeutic strategy in unresectable metastatic colorectal cancer: an updated review. *Ther Adv Med Oncol.* 2015;7(3):153–69.
 98. Saltz LB, Clarke S, Diaz-Rubio E, Scheithauer W, Figer A, Wong R, et al. Bevacizumab in combination with oxaliplatin-based chemotherapy as first-line therapy in metastatic colorectal cancer: a randomized phase III study. *J Clin Oncol.* 2008;26(12):2013–19.
 99. Loupakis F, Cremolini C, Masi G, Lonardi S, Zagonel V, Salvatore L, et al. Initial therapy with FOLFOXIRI and bevacizumab for metastatic colorectal cancer. *N Engl J Med.* 2014;371(17):1609–18.
 100. Tebbutt NC, Wilson K, GebSKI VJ, Cummins MM, Zannino D, van Hazel GA, et al. Capecitabine, bevacizumab, and mitomycin in first-line treatment of metastatic colorectal cancer: results of the Australasian Gastrointestinal Trials Group Randomized Phase III MAX Study. *J Clin Oncol.* 2010;28(19):3191–8.
 101. Kabbinavar FF, Schulz J, McCleod M, Patel T, Hamm JT, Hecht JR, et al. Addition of bevacizumab to bolus fluorouracil and leucovorin in first-line metastatic colorectal cancer: results of a randomized phase II trial. *J Clin Oncol.* 2005;23(16):3697–705.
 102. Hecht JR, Mitchell E, Chidiac T, Scroggin C, Hagenstad C, Spigel D, et al. A randomized phase IIIB trial of chemotherapy, bevacizumab, and panitumumab compared with chemotherapy and bevacizumab alone for metastatic colorectal cancer. *J Clin Oncol.* 2009;27(5):672–80.
 103. Tol J, Koopman M, Cats A, Rodenburg CJ, Creemers GJ, Schrama JG, et al. Chemotherapy, bevacizumab, and cetuximab in metastatic colorectal cancer. *N Engl J Med.* 2009;360(6):563–72.
 104. Andre T, Shiu KK, Kim TW, Jensen BV, Jensen LH, Punt C, et al. Pembrolizumab in Microsatellite-Instability-High Advanced Colorectal Cancer. *N Engl J Med.* 2020;383(23):2207–18.
 105. Yuan Y, Xiao W-W, Xie W-H, Cai P-Q, Wang Q-X, Chang H, et al. Neoadjuvant chemoradiotherapy for patients with unresectable radically locally advanced colon cancer: a potential improvement to overall survival and decrease to multivisceral resection. *BMC Cancer.* 2021;21(1):179.
 106. Lee JM, Byeon JS. Colorectal Stents: Current Status. *Clin Endosc.* 2015;48(3):194–200.
 107. Cetinkaya E, Dogrul AB, Tirnaksiz MB. Role of self expandable stents in management of colorectal cancers. *World J Gastrointest Oncol.* 2016;8(1):113–20.
 108. Hamady ZZ, Cameron IC, Wyatt J, Prasad RK, Toogood GJ, Lodge JP. Resection margin in patients undergoing hepatectomy for colorectal liver metastasis: a critical appraisal of the 1cm rule. *Eur J Surg Oncol.* 2006;32(5):557–63.
 109. Fong Y, Fortner J, Sun RL, Brennan MF, Blumgart LH. Clinical score for predicting recurrence after hepatic resection for metastatic colorectal cancer: analysis of 1001 consecutive cases. *Ann Surg.* 1999;230(3):309–18; discussion 18–21.
 110. Ayez N, van der Stok EP, Grunhagen DJ, Rothbarth J, van Meerten E, Eggermont AM, et al. The use of neo-adjuvant chemotherapy in patients with resectable colorectal liver metastases: Clinical risk score as possible discriminator. *Eur J Surg Oncol.* 2015;41(7):859–67.
 111. Liu W, Zhang W, Xu Y, Li YH, Xing BC. A Prognostic Scoring System to Predict Survival Outcome of Resectable Colorectal Liver Metastases in this Modern Era. *Ann Surg Oncol.* 2021;28(12):7709–18.
 112. Van Cutsem E, Cervantes A, Adam R, Sobrero A, Van Krieken JH, Aderka D, et al. ESMO consensus guidelines for the management of patients with metastatic colorectal cancer. *Ann Oncol.* 2016;27(8):1386–422.
 113. Wang Z-X, Yao Y-C, Mai Z-J, Lin W-H, Huang Y-S, Jin Y, et al. Temporal Change in Treatment Patterns of Metastatic Colorectal Cancer and Its Association with Patient Survival: A Retrospective Cohort Study Based on an Intelligent Big-Data Platform. *Engineering.* 2021;7(4):526–33.
 114. Tejpar S, Stintzing S, Ciardiello F, Tabernero J, Van Cutsem E, Beier F, et al. Prognostic and Predictive Relevance of Primary Tumor Location in Patients With RAS Wild-Type Metastatic Colorectal Cancer: Retrospective Analyses of the CRYSTAL and FIRE-3 Trials. *JAMA Oncol.* 2017;3(2):194–201.
 115. Wang ZX, Wu HX, He MM, Wang YN, Luo HY, Ding PR, et al. Chemotherapy With or Without Anti-EGFR Agents in Left- and Right-Sided Metastatic Colorectal Cancer: An Updated Meta-Analysis. *J Natl Compr Canc Netw.* 2019;17(7):805–11.
 116. Benson AB, Venook AP, Adam M, Chang G, Chen YJ, Ciombor KK, et al. Colon Cancer, Version 3.2024, NCCN Clinical Practice Guidelines in Oncology. *J Natl Compr Canc Netw.* 2024;22(2 d):e240029.
 117. Overman MJ, Lenz H-J, Andre T, Aglietta M, Wong MK, Luppi G, et al. Nivolumab (NIVO) ± ipilimumab (IPI) in patients (pts) with microsatellite instability-high/mismatch repair-deficient (MSI-H/dMMR) metastatic colorectal cancer (mCRC): Five-year follow-up from CheckMate 142. *J Clin Oncol.* 2022;40(16_suppl):3510-.
 118. Masi G, Salvatore L, Boni L, Loupakis F, Cremolini C, Fornaro L, et al. Continuation or reintroduction of bevacizumab beyond progression to first-line therapy in metastatic colorectal cancer: final results of the randomized BEBYP trial. *Ann Oncol.* 2015;26(4):724–30.
 119. Suenaga M, Mizunuma N, Matsusaka S, Shinozaki E, Ozaka M, Ogura M, et al. A phase I/II study of biweekly capecitabine and irinotecan plus bevacizumab as second-line chemotherapy in patients with metastatic colorectal cancer. *Drug Des Devel Ther.* 2015;9:1653–62.
 120. Xu RH, Muro K, Morita S, Iwasa S, Han SW, Wang W, et al. Modified XELIRI (capecitabine plus irinotecan) versus FOLFIRI (leucovorin, fluorouracil, and irinotecan), both either with or without bevacizumab, as second-line therapy for metastatic colorectal cancer (AXEPT): a multicentre, open-label, randomised, non-inferiority, phase 3 trial. *Lancet Oncol.* 2018;19(5):660–71.

121. Kopetz S, Guthrie KA, Morris VK, Lenz HJ, Magliocco AM, Maru D, et al. Randomized Trial of Irinotecan and Cetuximab With or Without Vemurafenib in BRAF-Mutant Metastatic Colorectal Cancer (SWOG S1406). *J Clin Oncol.* 2021;39(4):285–94.
122. Li J, Qin S, Xu R, Yau TC, Ma B, Pan H, et al. Regorafenib plus best supportive care versus placebo plus best supportive care in Asian patients with previously treated metastatic colorectal cancer (CONCUR): a randomised, double-blind, placebo-controlled, phase 3 trial. *Lancet Oncol.* 2015;16(6):619–29.
123. Bekaii-Saab TS, Ou F-S, Anderson DM, Ahn DH, Boland PM, Ciombor KK, et al. Regorafenib dose optimization study (ReDOS): Randomized phase II trial to evaluate dosing strategies for regorafenib in refractory metastatic colorectal cancer (mCRC): An ACCRU Network study. *J Clin Oncol.* 2018;36(4_suppl):611.
124. Li J, Qin S, Xu RH, Shen L, Xu J, Bai Y, et al. Effect of Fruquintinib vs Placebo on Overall Survival in Patients With Previously Treated Metastatic Colorectal Cancer: The FRESKO Randomized Clinical Trial. *JAMA.* 2018;319(24):2486–96.
125. Xu J, Kim TW, Shen L, Sriuranpong V, Pan H, Xu R, et al. Results of a Randomized, Double-Blind, Placebo-Controlled, Phase III Trial of Trifluridine/Tipiracil (TAS-102) Monotherapy in Asian Patients With Previously Treated Metastatic Colorectal Cancer: The TERRA Study. *J Clin Oncol.* 2018;36(4):350–8.
126. Prager GW, Taieb J, Fakih M, Ciardiello F, Cutsem EV, Elez E, et al. Trifluridine–Tipiracil and Bevacizumab in Refractory Metastatic Colorectal Cancer. *N Engl J Med.* 2023;388(18):1657–67.
127. Yoshino T, Di Bartolomeo M, Raghav K, Masuishi T, Loupakis F, Kawakami H, et al. Final results of DESTINY-CRC01 investigating trastuzumab deruxtecan in patients with HER2-expressing metastatic colorectal cancer. *Nat Commun.* 2023;14(1):3332.
128. Alberts SR, Horvath WL, Sternfeld WC, Goldberg RM, Mahoney MR, Dakhil SR, et al. Oxaliplatin, fluorouracil, and leucovorin for patients with unresectable liver-only metastases from colorectal cancer: a North Central Cancer Treatment Group phase II study. *J Clin Oncol.* 2005;23(36):9243–9.
129. Bond MJG, Bolhuis K, Loosveld OJL, de Groot JWB, Droogendijk H, Helgason HH, et al. First-line systemic treatment strategies in patients with initially unresectable colorectal cancer liver metastases (CAIRO5): an open-label, multicentre, randomised, controlled, phase 3 study from the Dutch Colorectal Cancer Group. *Lancet Oncol.* 2023;24(7):757–71.
130. Yalcin S, Uslu R, Dane F, Yilmaz U, Zengin N, Buyukunal E, et al. Bevacizumab + capecitabine as maintenance therapy after initial bevacizumab + XELOX treatment in previously untreated patients with metastatic colorectal cancer: phase III ‘Stop and Go’ study results—a Turkish Oncology Group Trial. *Oncology.* 2013;85(6):328–35.
131. Esin E, Yalcin S. Maintenance strategy in metastatic colorectal cancer: A systematic review. *Cancer Treat Rev.* 2016;42:82–90.
132. Tarantino I, Warschkow R, Guller U. Palliative Primary Tumor Resection in Patients With Metastatic Colorectal Cancer: For Whom and When? *Ann Surg.* 2017;265(4):e59–e60.
133. Hu CY, Bailey CE, You YN, Skibber JM, Rodriguez-Bigas MA, Feig BW, et al. Time trend analysis of primary tumor resection for stage IV colorectal cancer: less surgery, improved survival. *JAMA Surg.* 2015;150(3):245–51.
134. Moritani K, Kanemitsu Y, Shida D, Shitara K, Mizusawa J, Katayama H, et al. A randomized controlled trial comparing primary tumour resection plus chemotherapy with chemotherapy alone in incurable stage IV colorectal cancer: JCOG1007 (iPACS study). *Jpn J Clin Oncol.* 2020;50(1):89–93.
135. Fakih MG, Salvatore L, Esaki T, Modest DP, Lopez-Bravo DP, Taieb J, et al. Sotorasib plus Panitumumab in Refractory Colorectal Cancer with Mutated KRAS G12C. *N Engl J Med.* 2023;389(23):2125–39.
136. Rousseau B, Bieche I, Pasmant E, Hamzaoui N, Leulliot N, Michon L, et al. PD-1 Blockade in Solid Tumors with Defects in Polymerase Epsilon. *Cancer Discov.* 2022;12(6):1435–48.
137. Wang F, Zhao Q, Wang Y-N, Jin Y, He M-M, Liu Z-X, et al. Evaluation of POLE and POLD1 Mutations as Biomarkers for Immunotherapy Outcomes Across Multiple Cancer Types. *JAMA Oncol.* 2019;5(10):1504–6.
138. Chen YX, Wang ZX, Yuan SQ, Jiang TJ, Huang YS, Xu RH, et al. POLE/POLD1 mutation in non-exonuclease domain matters for predicting efficacy of immune-checkpoint-inhibitor therapy. *Clin Transl Med.* 2021;11(9):e524.
139. Jin Y, Huang R-J, Guan W-L, Wang Z-Q, Mai Z-J, Li Y-H, et al. A phase II clinical trial of toripalimab in advanced solid tumors with polymerase epsilon/polymerase delta (POLE/POLD1) mutation. *Signal Transduct Targ Ther.* 2024;9(1):227.
140. Fukuoka S, Hara H, Takahashi N, Kojima T, Kawazoe A, Asayama M, et al. Regorafenib Plus Nivolumab in Patients With Advanced Gastric or Colorectal Cancer: An Open-Label, Dose-Escalation, and Dose-Expansion Phase Ib Trial (REGONIVO, EPOC1603). *J Clin Oncol.* 2020;38(18):2053–61.
141. Wang F, He MM, Yao YC, Zhao X, Wang ZQ, Jin Y, et al. Regorafenib plus toripalimab in patients with metastatic colorectal cancer: a phase Ib/II clinical trial and gut microbiome analysis. *Cell Rep Med.* 2021;2(9):100383.
142. Fakih M, Raghav KPS, Chang DZ, Larson T, Cohn AL, Huyck TK, et al. Regorafenib plus nivolumab in patients with mismatch repair-proficient/microsatellite stable metastatic colorectal cancer: a single-arm, open-label, multicentre phase 2 study. *EclinicalMedicine.* 2023;58:101917.
143. Guo Y, Zhang W, Ying J, Zhang Y, Pan Y, Qiu W, et al. Phase Ib/2 trial of fruquintinib plus sintilimab in treating advanced solid tumours: The dose-escalation and metastatic colorectal cancer cohort in the dose-expansion phases. *Eur J Cancer.* 2023;181:26–37.
144. Wang F, Jin Y, Wang M, Luo HY, Fang WJ, Wang YN, et al. Combined anti-PD-1, HDAC inhibitor and anti-VEGF for MSS/pMMR colorectal cancer: a randomized phase 2 trial. *Nat Med.* 2024;30(4):1035–43.
145. Wang ZX, Peng J, Liang X, Cheng Y, Deng Y, Chen K, et al. First-line serplulimab in metastatic colorectal cancer: Phase 2 results of a randomized, double-blind, phase 2/3 trial. *Med.* 2024;5(9):1150–63.e3.
146. Fang X, Zhu N, Zhong C, Wang L, Li J, Weng S, et al. Sintilimab plus bevacizumab, oxaliplatin and capecitabine as first-line therapy in RAS-mutant, microsatellite stable, unresectable metastatic colorectal cancer: an open-label, single-arm, phase II trial. *EclinicalMedicine.* 2023;62:102123.

147. Rex DK, Kahi CJ, Levin B, Smith RA, Bond JH, Brooks D, et al. Guidelines for colonoscopy surveillance after cancer resection: a consensus update by the American Cancer Society and the US Multi-Society Task Force on Colorectal Cancer. *Gastroenterology*. 2006;130(6):1865–71.
148. Tie J, Cohen JD, Wang Y, Christie M, Simons K, Lee M, et al. Circulating Tumor DNA Analyses as Markers of Recurrence Risk and Benefit of Adjuvant Therapy for Stage III Colon Cancer. *JAMA Oncol*. 2019;5(12):1710–17.
149. Al-Najami I, Rancinger CP, Larsen MK, Thomassen N, Buch N, Baatrup G. Transanal endoscopic microsurgery for advanced polyps and early cancers in the rectum-Long-term outcome: A STROBE compliant observational study. *Medicine (Baltimore)*. 2016;95(36):e4732.
150. Heald RJ, Husband EM, Ryall RD. The mesorectum in rectal cancer surgery—the clue to pelvic recurrence? *Br J Surg*. 1982;69(10):613–6.
151. Serra-Aracil X, Pericay C, Badia-Closa J, Golda T, Biondo S, Hernandez P, et al. Short-term outcomes of chemoradiotherapy and local excision versus total mesorectal excision in T2-T3ab,N0,M0 rectal cancer: a multicentre randomised, controlled, phase III trial (the TAU-TEM study). *Ann Oncol*. 2023;34(1):78–90.
152. Gerard JP, Myint AS, Barbet N, Dejean C, Thamphya B, Gal J, et al. Targeted Radiotherapy Using Contact X-ray Brachytherapy 50 kV. *Cancers (Basel)*. 2022;14(5).
153. Jensen LH, Risum S, Nielsen JD, Mynster T, Ploeen J, Rahr HB, et al. Curative chemoradiation for low rectal cancer: Primary clinical outcomes from a multicenter phase II trial. *Am Soc Clin Oncol*. 2022:LBA3514.
154. Gerard J-P, Barbet NN, Pacé-Loscos T, Magné N, Serrand J, Mineur L, et al. Contact x-ray brachytherapy (Papillon) in addition to chemoradiotherapy to improve organ preservation in early cT2-T3 rectal adenocarcinoma: The 3-year results of OPERA randomized trial (NCT02505750). *J Clin Oncol*. 2022;40(16_suppl):3512-.
155. Chen G, Jin Y, Guan WL, Zhang RX, Xiao WW, Cai PQ, et al. Neoadjuvant PD-1 blockade with sintilimab in mismatch-repair deficient, locally advanced rectal cancer: an open-label, single-centre phase 2 study. *Lancet Gastroenterol Hepatol*. 2023;8(5):422–31.
156. Fokas E, Appelt A, Glynne-Jones R, Beets G, Perez R, Garcia-Aguilar J, et al. International consensus recommendations on key outcome measures for organ preservation after (chemo)radiotherapy in patients with rectal cancer. *Nat Rev Clin Oncol*. 2021;18(12):805–16.
157. Sauer R, Liersch T, Merkel S, Fietkau R, Hohenberger W, Hess C, et al. Preoperative Versus Postoperative Chemoradiotherapy for Locally Advanced Rectal Cancer: Results of the German CAO/ARO/AIO-94 Randomized Phase III Trial After a Median Follow-Up of 11 Years. *J Clin Oncol*. 2012;30(16):1926–33.
158. Gérard JP, Conroy T, Bonnetain F, Bouché O, Chapet O, Closon-Dejardin MT, et al. Preoperative radiotherapy with or without concurrent fluorouracil and leucovorin in T3-4 rectal cancers: results of FFCD 9203. *J Clin Oncol*. 2006;24(28):4620–5.
159. Bosset JF, Calais G, Mineur L, Maingon P, Radosevic-Jelic L, Daban A, et al. Enhanced tumorocidal effect of chemotherapy with preoperative radiotherapy for rectal cancer: preliminary results—EORTC 22921. *J Clin Oncol*. 2005;23(24):5620–7.
160. Hofheinz RD, Wenz F, Post S, Matzdorff A, Laechelt S, Hartmann JT, et al. Chemoradiotherapy with capecitabine versus fluorouracil for locally advanced rectal cancer: a randomised, multicentre, non-inferiority, phase 3 trial. *Lancet Oncol*. 2012;13(6):579–88.
161. Zhu J, Liu A, Sun X, Liu L, Zhu Y, Zhang T, et al. Multicenter, Randomized, Phase III Trial of Neoadjuvant Chemoradiation With Capecitabine and Irinotecan Guided by UGT1A1 Status in Patients With Locally Advanced Rectal Cancer. *J Clin Oncol*. 2020;38(36):4231–9.
162. Deng Y, Chi P, Lan P, Wang L, Chen W, Cui L, et al. Neoadjuvant Modified FOLFOX6 With or Without Radiation Versus Fluorouracil Plus Radiation for Locally Advanced Rectal Cancer: Final Results of the Chinese FOWARC Trial. *J Clin Oncol*. 2019;37(34):3223–33.
163. Garcia-Aguilar J, Chow OS, Smith DD, Marcet JE, Cataldo PA, Varma MG, et al. Effect of adding mFOLFOX6 after neoadjuvant chemoradiation in locally advanced rectal cancer: a multicentre, phase 2 trial. *Lancet Oncol*. 2015;16(8):957–66.
164. Cercek A, Roxburgh CSD, Strombom P, Smith JJ, Temple LKF, Nash GM, et al. Adoption of Total Neoadjuvant Therapy for Locally Advanced Rectal Cancer. *JAMA Oncol*. 2018;4(6):e180071.
165. Garcia-Aguilar J, Patil S, Gollub MJ, Kim JK, Yuval JB, Thompson HM, et al. Organ Preservation in Patients With Rectal Adenocarcinoma Treated With Total Neoadjuvant Therapy. *J Clin Oncol*. 2022;40(23):2546–56.
166. Gay HA, Barthold HJ, O’Meara E, Bosch WR, El Naqa I, Al-Lozi R, et al. Pelvic normal tissue contouring guidelines for radiation therapy: a Radiation Therapy Oncology Group consensus panel atlas. *Int J Radiat Oncol Biol Phys*. 2012;83(3):e353–62.
167. André T, Boni C, Mounedji-Boudiaf L, Navarro M, Tabernero J, Hickish T, et al. Oxaliplatin, Fluorouracil, and Leucovorin as Adjuvant Treatment for Colon Cancer. *N Engl J Med*. 2004;350(23):2343–51.
168. Hong YS, Nam BH, Kim KP, Kim JE, Park SJ, Park YS, et al. Oxaliplatin, fluorouracil, and leucovorin versus fluorouracil and leucovorin as adjuvant chemotherapy for locally advanced rectal cancer after preoperative chemoradiotherapy (ADORE): an open-label, multicentre, phase 2, randomised controlled trial. *Lancet Oncol*. 2014;15(11):1245–53.
169. Swedish Rectal Cancer T, Cedermarck B, Dahlberg M, Glimelius B, Pahlman L, Rutqvist LE, et al. Improved survival with preoperative radiotherapy in resectable rectal cancer. *N Engl J Med*. 1997;336(14):980–7.
170. van Gijn W, Marijnen CA, Nagtegaal ID, Kranenburg EM, Putter H, Wiggers T, et al. Preoperative radiotherapy combined with total mesorectal excision for resectable rectal cancer: 12-year follow-up of the multicentre, randomised controlled TME trial. *Lancet Oncol*. 2011;12(6):575–82.
171. Bujko K, Nowacki MP, Nasierowska-Guttmejer A, Michalski W, Bebenek M, Kryj M. Long-term results of a randomized trial comparing preoperative short-course radiotherapy with preoperative conventionally fractionated chemoradiation for rectal cancer. *Br J Surg*. 2006;93(10):1215–23.
172. Ngan SY, Burmeister B, Fisher RJ, Solomon M, Goldstein D, Joseph D, et al. Randomized Trial of Short-Course Radiother-

- apy Versus Long-Course Chemoradiation Comparing Rates of Local Recurrence in Patients With T3 Rectal Cancer: Trans-Tasman Radiation Oncology Group Trial 01.04. *J Clin Oncol.* 2012;30(31):3827–33.
173. Bahadoer RR, Dijkstra EA, van Etten B, Marijnen CAM, Putter H, Kranenbarg EM-K, et al. Short-course radiotherapy followed by chemotherapy before total mesorectal excision (TME) versus preoperative chemoradiotherapy, TME, and optional adjuvant chemotherapy in locally advanced rectal cancer (RAPIDO): a randomised, open-label, phase 3 trial. *Lancet Oncol.* 2021;22(1):29–42.
 174. Schrag D, Shi Q, Weiser MR, Gollub MJ, Saltz LB, Musher BL, et al. Preoperative Treatment of Locally Advanced Rectal Cancer. *N Engl J Med.* 2023;389(4):322–34.
 175. Lai LL, Fuller CD, Kachnic LA, Thomas CR, Jr. Can pelvic radiotherapy be omitted in select patients with rectal cancer? *Semin Oncol.* 2006;33(6 Suppl 11):S70–4.
 176. Gunderson LL, Sargent DJ, Tepper JE, Wolmark N, O'Connell MJ, Begovic M, et al. Impact of T and N stage and treatment on survival and relapse in adjuvant rectal cancer: a pooled analysis. *J Clin Oncol.* 2004;22(10):1785–96.
 177. Tepper JE, O'Connell M, Niedzwiecki D, Hollis DR, Benson AB, 3rd, Cummings B, et al. Adjuvant therapy in rectal cancer: analysis of stage, sex, and local control—final report of intergroup 0114. *J Clin Oncol.* 2002;20(7):1744–50.
 178. Conroy T, Bosset JF, Etienne PL, Rio E, Francois E, Mesgouez-Nebout N, et al. Neoadjuvant chemotherapy with FOLFIRINOX and preoperative chemoradiotherapy for patients with locally advanced rectal cancer (UNICANCER-PRODIGE 23): a multicentre, randomised, open-label, phase 3 trial. *Lancet Oncol.* 2021;22(5):702–15.
 179. Verheij FS, Omer DM, Williams H, Lin ST, Qin LX, Buckley JT, et al. Long-Term Results of Organ Preservation in Patients With Rectal Adenocarcinoma Treated With Total Neoadjuvant Therapy: The Randomized Phase II OPRA Trial. *J Clin Oncol.* 2024;42(5):500–6.
 180. Tambari S, Grassi E, Zingaretti C, Papiani G, Pini S, Corbelli J, et al. A phase II study of capecitabine plus concomitant radiation therapy followed by durvalumab (MEDI4736) as preoperative treatment in rectal cancer: PANDORA study final results. *J Clin Oncol.* 2022;40:LBA3513–LBA.
 181. WU A, Li Y, Ji D, Zhang L, Zhang X, Cai Y, et al. Total neoadjuvant chemoradiation combined with neoadjuvant PD-1 blockade for patients with pMMR, high-risk, and locally advanced middle to low rectal cancer. *J Clin Oncol.* 2022;40(16_suppl):3611.
 182. Salvatore L, Bensi M, Corallo S, Bergamo F, Pellegrini I, Rasola C, et al. Phase II study of preoperative (PREOP) chemoradiotherapy (CTRT) plus avelumab (AVE) in patients (PTS) with locally advanced rectal cancer (LARC): The AVANA study. *J Clin Oncol.* 2021;39(15_suppl):3511.
 183. George TJ, Yothers G, Jacobs SA, Finley GG, Wade JL, Rocha Lima CMSP, et al. Phase II study of durvalumab following neoadjuvant chemoRT in operable rectal cancer: NSABP FR-2. *J Clin Oncol.* 2022;40(4_suppl):99–9.
 184. Lin Z, Cai M, Zhang P, Li G, Liu T, Li X, et al. Phase II, single-arm trial of preoperative short-course radiotherapy followed by chemotherapy and camrelizumab in locally advanced rectal cancer. *J Immunother Cancer.* 2021;9(11).
 185. Zhang T, Tao K, Lin Z, Zhang P, Yin Y, Chi P, et al. LBA25 Neoadjuvant short-course radiotherapy followed by camrelizumab plus chemotherapy versus long-course chemoradiotherapy followed by chemotherapy in locally advanced rectal cancer: A randomized phase III trial (UNION). *Ann Oncol.* 2023;34:S1266–7.
 186. Boyle KM, Sagar PM, Chalmers AG, Sebag-Montefiore D, Cairns A, Eardley I. Surgery for locally recurrent rectal cancer. *Dis Colon Rectum.* 2005;48(5):929–37.
 187. Hahnloser D, Nelson H, Gunderson LL, Hassan I, Haddock MG, O'Connell MJ, et al. Curative potential of multimodality therapy for locally recurrent rectal cancer. *Ann Surg.* 2003;237(4):502–8.
 188. Moore HG, Shoup M, Riedel E, Minsky BD, Alektiar KM, Ercolani M, et al. Colorectal cancer pelvic recurrences: determinants of resectability. *Dis Colon Rectum.* 2004;47(10):1599–606.
 189. Heriot AG, Byrne CM, Lee P, Dobbs B, Tilney H, Solomon MJ, et al. Extended radical resection: the choice for locally recurrent rectal cancer. *Dis Colon Rectum.* 2008;51(3):284–91.
 190. Yamada K, Ishizawa T, Niwa K, Chuman Y, Aikou T. Pelvic exenteration and sacral resection for locally advanced primary and recurrent rectal cancer. *Dis Colon Rectum.* 2002;45(8):1078–84.
 191. Bouchard P, Efron J. Management of recurrent rectal cancer. *Ann Surg Oncol.* 2010;17(5):1343–56.
 192. Mirnezami AH, Sagar PM, Kavanagh D, Witherspoon P, Lee P, Winter D. Clinical algorithms for the surgical management of locally recurrent rectal cancer. *Dis Colon Rectum.* 2010;53(9):1248–57.
 193. Lynch HT, Shaw TG. Practical genetics of colorectal cancer. *Chin Clin Oncol.* 2013;2(2):12.
 194. Grover S, Kastrinos F, Steyerberg EW, Cook EF, Dewanwala A, Burbidge LA, et al. Prevalence and phenotypes of APC and MUTYH mutations in patients with multiple colorectal adenomas. *JAMA.* 2012;308(5):485–92.
 195. Yang S, Cai S, Zhang S. Clinical and genetic phenotype of familial adenomatous polyposis and its subtypes. *J Pract Oncol.* 2007;22(3):270–73.
 196. Nieuwenhuis MH, Vasen HF. Correlations between mutation site in APC and phenotype of familial adenomatous polyposis (FAP): a review of the literature. *Crit Rev Oncol Hematol.* 2007;61(2):153–61.
 197. Yan D, Yu X, Xiao-Dong X. Research on the fundus fluorescein angiography in congenital hypertrophy of the retinal pigment epithelium in patients with familial adenomatous polyposis. *International Eye Science.* 2020;10(6):1157–9.
 198. Cao HL, Wang BM, Cao XC. Clinical features of Gardner syndrome and Turcot syndrome in Chinese population: an analysis of 93 cases. *World Chinese J Digestol.* 2010;18(36):3922–5.
 199. Lou Z, Yu ED, Meng RG. Familial adenomatous polyposis-associated desmoid tumors. *Acad J Second Mil Med Univ.* 2006;27(5):541–3.
 200. Sieber OM, Lipton L, Crabtree M, Heinemann K, Fidalgo P, Phillips RK, et al. Multiple colorectal adenomas, classic adenomatous polyposis, and germ-line mutations in MYH. *N Engl J Med.* 2003;348(9):791–9.
 201. Lindor NM, Rabe K, Petersen GM, Haile R, Casey G, Baron J, et al. Lower cancer incidence in Amsterdam-I criteria families

- without mismatch repair deficiency: familial colorectal cancer type X. *JAMA*. 2005;293(16):1979–85.
202. Li XF, Yuan Y. Research progress of Lynch syndrome in China. *Chinese J Colorect Dis (Electronic Edition)*. 2015(3):21–6.
203. Moreira L, Balaguer F, Lindor N, de la Chapelle A, Hampel H, Aaltonen LA, et al. Identification of Lynch syndrome among patients with colorectal cancer. *JAMA*. 2012;308(15):1555–65.
204. National Collaborative Group on Hereditary Colorectal Cancer. Implementation of screening standards for hereditary colorectal cancer in the Chinese population. *Chinese J Oncol*. 2004;26(3):191–2.
205. Ligtenberg MJ, Kuiper RP, Chan TL, Goossens M, Hebeda KM, Voorendt M, et al. Heritable somatic methylation and inactivation of MSH2 in families with Lynch syndrome due to deletion of the 3' exons of TACSTD1. *Nat Genet*. 2009;41(1):112–7.
206. Senter L, Clendenning M, Sotamaa K, Hampel H, Green J, Potter JD, et al. The clinical phenotype of Lynch syndrome due to germ-line PMS2 mutations. *Gastroenterology*. 2008;135(2):419–28.
207. Yuan Y, Cao WM, Cai SR, Zhang SZ. Clinical phenotype of Chinese hereditary nonpolyposis colorectal cancer (HNPCC) families. *Chinese J Oncol*. 2006;28(1):36–8.
208. Hampel H, Frankel WL, Martin E, Arnold M, Khanduja K, Kuebler P, et al. Screening for the Lynch syndrome (hereditary nonpolyposis colorectal cancer). *N Engl J Med*. 2005;352(18):1851–60.
209. Wang SL, Da JP, Gu GL. Research Advance of Muir-Torre Syndrome. *Chinese J Bases & Clinics Gen Surg*. 2005;12(2):192–4.
210. Xicola RM, Llor X, Pons E, Castells A, Alenda C, Pinol V, et al. Performance of different microsatellite marker panels for detection of mismatch repair-deficient colorectal tumors. *J Natl Cancer Inst*. 2007;99(3):244–52.
211. Boland CR, Thibodeau SN, Hamilton SR, Sidransky D, Eshleman JR, Burt RW, et al. A National Cancer Institute Workshop on Microsatellite Instability for cancer detection and familial predisposition: development of international criteria for the determination of microsatellite instability in colorectal cancer. *Cancer Res*. 1998;58(22):5248–57.
212. Zhu M, Liu XR, Huang YQ, Yuan Y, Li JT, Zhang XM, et al. The analysis for identifying large DNA fragment aberrations of MSH2 and MLH1 genes from familial colorectal cancer in China. *Chinese J Med Genet*. 2005;22(6):603–6.
213. Dai YC, Xie JP, Zeng W, Fu YK, Chen ZX. Clinical meta-analysis of melanotic polyp syndrome in mainland China. *J Clin Intern Med*. 2008(08):526–7.
214. Kang LC, Zhao XR, Zhou YS, Jia YX, Kang SH, Chen Z, et al. Mutational analysis of the STK11 gene in a family line with Peutz-Jeghers syndrome. *Science Bulletin*. 2002;47(21):1639–43.
215. Genetics Group of the Colorectal Cancer Professional Committee of the Chinese Anti-Cancer Association. Consensus on clinical diagnosis, treatment and pedigree management of hereditary colorectal cancer in China. *Chinese J Oncol*. 2018;40(1):64–77.

How to cite this article: Wang F, Chen G, Zhang Z, Yuan Y, Wang Y, Gao Y-H, et al. The Chinese Society of Clinical Oncology (CSCO): Clinical guidelines for the diagnosis and treatment of colorectal cancer, 2024 update. *Cancer Commun*. 2024;1–48. <https://doi.org/10.1002/cac2.12639>

APPENDIX

CSCO categories of evidence and consensus

Evidence characteristics			
Category	Level	Source	CSCO expert consensus
1A	High	Rigorous meta-analyses, large-scale randomized controlled trials	Unanimous Consensus (Supporting Opinions $\geq 80\%$)
1B	High	Rigorous meta-analyses, large-scale randomized controlled trials	Basic Consensus (Supporting Opinions 60%-80%)
2A	Relatively low	Meta-analyses of moderate quality, small-scale randomized controlled trials, well-designed large retrospective studies, case-control studies	Unanimous Consensus (Supporting Opinions $\geq 80\%$)
2B	Relatively low	Meta-analyses of moderate quality, small-scale randomized controlled trials, well-designed large retrospective studies, case-control studies	Basic Consensus (Supporting Opinions 60%-80%)
3	Low	Non-controlled single-arm clinical studies, case reports, expert opinions	No consensus with significant controversy (supporting opinions $< 60\%$)

The recommendation grades of the CSCO Guidelines

Recommendations grade	Criteria
Grade I recommendations	Category 1A evidence and partial Category 2A evidence: CSCO Guidelines classify Category 1A evidence, as well as partial high-consensus Category 2A evidence with good accessibility in China, as Grade I recommendations. Specifically, this includes interventions with well-defined indications, good accessibility, stable value in cancer treatment, and inclusion in the “National Basic Medical Insurance, Work-related Injury Insurance, and Maternity Insurance Drug Catalogue.”
Grade II recommendations	Category 1B evidence and partial Category 2A evidence: CSCO Guidelines categorize Category 1B evidence, as well as partial Category 2A evidence with high expert consensus but limited accessibility in China, as Grade II recommendations. Specifically, this includes randomized controlled trials conducted in China and internationally, which provide high-level evidence but may have limited accessibility or cost-effectiveness. Measures that demonstrate clear clinical benefits but are expensive may also be considered Grade II recommendations, taking into account the potential benefits for patients.
Grade III recommendations	Category 2B evidence and Category 3 evidence: For certain clinical practices that are commonly used or have exploratory value, although the evidence from evidence-based medicine is relatively limited, if the expert consensus deems them acceptable, they are classified as Grade III recommendations.