



OPEN ACCESS

# ESGO/EURACAN/GCIG guidelines for the management of patients with uterine sarcomas

Isabelle Ray-Coquard <sup>1,2</sup>, Paolo Giovanni Casali,<sup>3,4</sup> Sabrina Croce,<sup>5</sup> Fiona M Fennessy,<sup>6,7</sup> Daniela Fischerova <sup>8</sup>, Robin Jones,<sup>9</sup> Roberta Sanfilippo,<sup>10</sup> Ignacio Zapardiel <sup>11</sup>, Frédéric Amant <sup>12,13</sup>, Jean-Yves Blay,<sup>1</sup> Javier Martin-Broto,<sup>14,15</sup> Antonio Casado,<sup>16</sup> Sarah Chiang <sup>17</sup>, Angelo Paolo Dei Tos,<sup>18,19</sup> Rick Haas,<sup>20,21</sup> Martee L Hensley,<sup>22,23</sup> Peter Hohenberger,<sup>24</sup> Jae-Weon Kim,<sup>25</sup> Se Ik Kim,<sup>25</sup> Mehmet Mutlu Meydanli <sup>26</sup>, Patricia Pautier,<sup>27</sup> Albiruni R Abdul Razak,<sup>28,29</sup> Jalid Sehoul <sup>30</sup>, Winan van Houdt,<sup>31</sup> François Planchamp <sup>32</sup>, Michael Friedlander<sup>33,34</sup>

► Additional supplemental material is published online only. To view, please visit the journal online (<https://doi.org/10.1136/ijgc-2024-005823>).

For numbered affiliations see end of article.

**Correspondence to**  
Professor Isabelle Ray-Coquard;  
[isabelle.ray-coquard@lyon.unicancer.fr](mailto:isabelle.ray-coquard@lyon.unicancer.fr)

Accepted 24 June 2024

A collaboration was established between the European Society of Gynaecological Oncology (ESGO), the European Reference Network on Rare Adult Solid Cancers (EURACAN), and the Gynecologic Cancer InterGroup (GCIG) with the aim of developing clinically relevant, evidence-based consensus guidelines on the management of patients with uterine sarcomas from diagnosis to relapse.

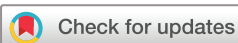ESGO/EURACAN/GCIG nominated practicing clinicians from centers of expertise in the management of patients with uterine sarcomas to serve on the expert panel (25 experts). To ensure that the statements were evidence-based, data identified from a systematic search were reviewed and critically appraised. In the absence of robust scientific evidence, clinical recommendations were based on the consensus of the international development group. Prior to publication, the guidelines were reviewed by 104 independent international clinicians with expertise in uterine sarcomas.

Attention was given to imaging, pathology, and molecular analyses in addition to clinical management. Recommendations for surgery, including specific recommendations at initial diagnosis and at relapse, were developed. Indications for radiation and systemic therapies, including chemotherapy options, endocrine therapies, and targeted therapies, were addressed for the following histological subgroups of uterine sarcomas: high-grade endometrial stromal sarcomas, undifferentiated sarcomas, low-grade endometrial stromal sarcomas, uterine leiomyosarcomas, adenosarcomas, and selected very rare entities. Recommendations for follow-up and highlighted issues and unmet needs faced by long-term survivors were also discussed.

## INTRODUCTION

Uterine sarcomas are rare uterine neoplasms that comprise a heterogeneous histological group of

tumors, including leiomyosarcoma (LMS) (the most common subtype), followed by endometrial stromal sarcoma (ESS) (including low-grade and high-grade variants), and rarer subtypes, such as adenosarcoma, undifferentiated uterine sarcomas (UUS), and tumors of uncertain malignant potential including perivascular epithelioid cell tumors (PEComa) and neurotrophic tropomyosin-receptor kinase (NTRK)-rearranged gynecological sarcomas.<sup>1 2</sup> They are diagnosed predominantly between the fourth and sixth decades of life and typically exhibit aggressive behavior including risk of distant metastases, even in early stages, and are associated with a poor prognosis in a significant proportion of patients with high-grade tumors. In 2014, the Gynecologic Cancer InterGroup (GCIG) published consensus reviews and recommendations for the management of a number of these rare uterine sarcomas.<sup>3–6</sup> Advances and new evidence have emerged over the last 10 years which have affected the management of patients with uterine sarcomas. In view of this, a collaboration was established between the European Society of Gynecological Oncology (ESGO), the European Reference Network on Rare Adult Solid Cancers (EURACAN), and GCIG with the specific objective of developing clinically relevant and evidence-based contemporary guidelines to guide the multidisciplinary approach for management of patients with uterine sarcomas from initial diagnosis to relapse. Attention was given to imaging, pathology, and molecular analyses in addition to clinical management. Guidelines for surgery, including specific recommendations at first diagnosis and at relapse for all histological subtypes of uterine sarcomas, were developed. Indications for radiation and systemic therapies, including chemotherapy options, endocrine therapies, and targeted therapies, were developed for the following histological subgroups: uterine leiomyosarcoma (uLMS),



© IGCS and ESGO 2024. Re-use permitted under CC BY-NC. No commercial re-use. Published by BMJ.

**To cite:** Ray-Coquard I, Casali PG, Croce S, *et al.* *Int J Gynecol Cancer* Published Online First: [please include Day Month Year]. doi:10.1136/ijgc-2024-005823

## Society statement

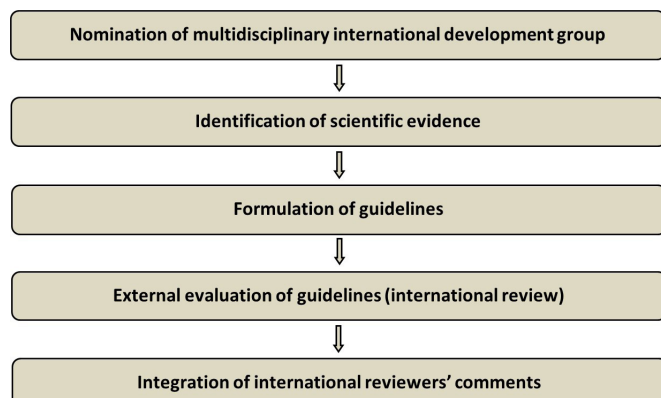
high-grade endometrial stromal sarcoma (HG-ESS), UUS, low-grade endometrial stromal sarcoma (LG-ESS), adenosarcoma, and selected very rare entities. Recommendations for follow-up after treatment are provided and specific issues faced by long-term survivors, including late effects of therapy, were discussed. These guidelines are intended for use by all health professionals involved in the management of patients with uterine sarcomas across all allied disciplines. Needs for research in the topics addressed and issues that directly affect these guidelines are also presented in this article.

## RESPONSIBILITIES

Our primary aim is to provide the highest level of evidence to support optimal management of patients with uterine sarcoma, but ESGO, EURACAN, and GCIG acknowledge that there will be broad variability in attitudes and practices worldwide, with significant differences in infrastructure, access to medical and surgical technology, and expertise, in addition to, medicolegal, financial, and cultural differences that impact the implementation of any guidelines. These guidelines are statements of available evidence and the consensus reached by the multidisciplinary development group based on their views and perspectives of currently accepted approaches to the management of patients with uterine sarcomas. Any clinician applying or consulting these guidelines is expected to use independent medical judgment in the context of individual clinical circumstances to determine optimal care and treatment for a patient. These guidelines make no representations or warranties of any kind whatsoever regarding their content, use, or application and disclaim any responsibility for their application or use in any way.

## METHODS

The guidelines were developed using a five-step process as defined by the ESGO Guideline Committee (see Figure 1). The strengths of the process include creation of a multidisciplinary international development group, use of scientific evidence and international expert consensus to support the guidelines, and use of an international external review process. This development process was chaired by Professor Isabelle Ray-Coquard (for ESGO), Professor Paolo G Casali (for EURACAN), and Professor Michael Friedlander (for GCIG). ESGO/



**Figure 1** Development process.

EURACAN/GCIG nominated practicing clinicians with recognized expertise in the management of patients with uterine sarcomas, including demonstrated leadership in clinical care and research, national and international engagement and profiles, as well as experience in the topics addressed. The objective was to assemble a multidisciplinary development group, and it was therefore essential to include clinicians from all relevant disciplines to contribute to the validity and acceptability of the guidelines. To ensure that the statements were evidence based, the current literature was reviewed and critically appraised. A systematic, unbiased literature review of relevant studies published between April 2013 and April 2023 was carried out using the Medline database (see Online Supplemental Appendix 1). The bibliography was also supplemented by additional older relevant references (if any). The literature search was limited to publications in English. Priority was given to high-quality systematic reviews, meta-analyses, and randomized controlled trials, but studies of lower levels of evidence were also evaluated. The search strategy excluded editorials, letters, and in vitro studies. The reference list of each identified article was also reviewed for other potentially relevant articles. Based on the collected evidence and clinical expertise, the international development group drafted guidelines for all the topics. The guidelines were discussed and retained if they were supported by sufficiently high-level scientific evidence and/or when a large consensus among experts was obtained. An adapted version of the 'Infectious Diseases Society of America-United States Public Health Service Grading System' was used to define the level of evidence and grade of recommendation for each of the recommendations (see Figure 2).<sup>7,8</sup> In the absence of any clear scientific evidence, judgment was based on the professional experience and consensus of the international development group.

ESGO/EURACAN/GCIG established a large multidisciplinary panel of practicing clinicians with expertise in the management of patients with uterine sarcomas to act as independent expert reviewers for the guidelines that were developed. These reviewers were selected according to their expertise and active involvement in clinical practice or research, while geographical balance ensured a global perspective. The international reviewers were asked to evaluate each guideline according to its relevance and feasibility in clinical practice, so that comprehensive quantitative and qualitative evaluations of the guidelines were completed. Evaluations of the external reviewers (n=104) were pooled and discussed by the international development group to finalize the guidelines development process. The list of the 104 external reviewers is available in Online Supplemental Appendix 2.

## GENERAL RECOMMENDATIONS

- ▶ Centralization of care in specialized centers and referral network is encouraged (IV, A).
- ▶ Treatment planning should be multidisciplinary (within a tumor board, composed according to local guidelines) and supported by all available evidence including an understanding and appreciation of prognostic and predictive factors, potential adverse effects of treatments, and quality of life (IV, A).
- ▶ Patients should be carefully counseled on the recommended management plan and potential alternatives, including risks

**LEVELS OF EVIDENCE**

<b>I</b>	Evidence from at least one large randomised, controlled trial of good methodological quality (low potential for bias) or meta-analyses of well-conducted, randomised trials without heterogeneity
<b>II</b>	Small randomised trials or large randomised trials with a suspicion of bias (lower methodological quality) or meta-analyses of such trials or of trials with demonstrated heterogeneity
<b>III</b>	Prospective cohort studies
<b>IV</b>	Retrospective cohort studies or case-control studies
<b>V</b>	Studies without control group, case reports, expert's opinions

**GRADES OF RECOMMENDATIONS**

<b>A</b>	Strong evidence for efficacy with a substantial clinical benefit, strongly recommended
<b>B</b>	Strong or moderate evidence for efficacy but with a limited clinical benefit, generally recommended
<b>C</b>	Insufficient evidence for efficacy or benefit does not outweigh the risk or the disadvantages (adverse events, costs, ...), optional
<b>D</b>	Moderate evidence against efficacy or for adverse outcome, generally not recommended
<b>E</b>	Strong evidence against efficacy or for adverse outcome, never recommended

**Figure 2** Levels of evidence and grades of recommendations.

and benefits of all options taking into full consideration their perspectives and wishes (V, A).

- ▶ Treatment should be undertaken by an experienced team in the diagnosis and management of uterine sarcomas (IV, A).
- ▶ Enrollment of patients with uterine sarcomas in clinical trials should be considered if available (IV, A).
- ▶ International collaboration and prospective registries for this rare group of disease are encouraged (V, B).

**DIAGNOSIS - PATHOLOGY**

The diagnosis of uterine sarcomas can be challenging due to their rarity and numerous subtypes and often relies on integrated histological evaluation as well as immunohistochemical and molecular analyses. Given the complexity of uterine sarcomas and pathologic evaluation, the diagnosis should be confirmed by a pathologist subspecialized in gynecologic pathology and/or with experience in diagnosing uterine mesenchymal tumors, preferably at a sarcoma reference center where molecular diagnostics are available and routinely used.<sup>9–11</sup> The diagnosis of uterine sarcomas should adhere to the guidelines outlined in the fifth edition of the WHO Classification of Female Genital Tumors and the International Collaboration on Cancer Reporting (ICCR) datasets.<sup>1 12</sup> Adherence to ICCR guidelines by meticulous macroscopic examination and extensive tumor sampling is recommended.<sup>12</sup> This is critical for the evaluation of differential diagnoses, such as sarcoma vs carcinosarcoma, LG-ESS vs HG-ESS, and smooth muscle tumor of uncertain malignant potential (STUMP) vs LMS. In vivo fragmentation (morcellation), which compromises specimen integrity and macroscopic evaluation of tumor size and the tumor to myometrium interface, should be avoided and acknowledged, if performed.<sup>13 14</sup>

Intra-operative evaluation is also discouraged; curettage and/or biopsies under ultrasound guidance with coaxial needles are reasonable alternatives.<sup>1 12</sup> Immunohistochemistry is recommended for diagnosis and to support therapeutic decision-making. A list of useful antibodies is included in

**Table 1.** In conjunction with histological evaluation and immunohistochemical studies, molecular tests are recommended to detect fusion transcripts and/or assess mutation status to refine tumor classification and/or identify therapeutic targets and can be performed on the resection or biopsy specimens, in settings where genomic analysis may be particularly informative when morphological evaluation is limited.<sup>15–17</sup> Assays that assess gene fusions include fluorescence in situ hybridization (FISH), DNA sequencing, and RNA sequencing. While each assay has advantages and disadvantages as well as variations in turnaround time, RNA sequencing is recommended for the diagnostic evaluation of uterine sarcomas given its efficiency in the comprehensive detection of known and novel fusions and isoforms (eg, *BCOR* internal tandem duplication, *JAZF1:BCOR* or *JAZF1:BCORL1* or *YWHAE* fusion transcript identification in HG-ESS).<sup>18</sup> DNA sequencing may be useful in the evaluation of (1) smooth muscle tumors to assess the mutation status of genes commonly altered in LMS and (2) LG-ESS with somatic mutations (ie, *TP53*, *RB1*, *ESR1*, *TSC2*). Genomic data obtained from array-comparative genomic hybridization (array-CGH), can also aid in the evaluation of challenging smooth muscle tumors, such as STUMP.<sup>19–21</sup> Regardless of the methods, all genomic data should be integrated in the appropriate clinicopathologic context to ensure diagnostic precision.<sup>22</sup> Pertinent pathologic features by tumor type are described below in brief.

The diagnosis of LG-ESS is based primarily on morphology and immunohistochemistry (see **Table 1**); detection of low-grade endometrial stromal tumor-associated fusions is helpful particularly in the setting of variant or high-grade features. The assessment of the interface between tumor and myometrium is critical in distinguishing between endometrial stromal nodule and LG-ESS, which share immunohistochemical profiles and fusion transcripts, and is not possible in limited tissue samples (ie, biopsy, curettage, myomectomy).<sup>1 23 24</sup>

## Society statement

**Table 1** Non-exhaustive list of diagnostic immunohistochemical markers<sup>217</sup>

Diagnosis*	Antibody
Smooth muscle tumors	Desmin, h-caldesmon, smooth muscle actin
Fumarate hydratase deficiency	FH and 2SC
STUMP	ATRX, RB, PTEN, p53, DAXX, MTAP, MDM2
Rhabdomyosarcoma	Desmin, myogenin, MyoD1, myogenin
Inflammatory myofibroblastic tumor	ALK, ROS1
Endometrial stromal tumors	CD10, IFITM1, Cyclin D1, BCOR, ER, PR
SMARC-deficient tumors	BRG1 (SMARCA4), BRM (SMARCA2), INI/BAF47(SMARCB1), MMR (MLH1, PMS2, MSH6, MSH2)
PEComa	HMB45, Melan A, Cathepsin K, TFE3
Fibrosarcoma	pan-TRK, CD34, S100
Solitary fibrous tumor	STAT6, CD34
Extraintestinal gastrointestinal stromal tumor	c-KIT, DOG1
Complex genomic sarcomas (LMS, UUS)	p53 (usually aberrant)
Simple genomic sarcomas (LG-ESS, HG-ESS, NTRK, etc)	p53 (usually wild-type)
Uterine tumor resembling ovarian sex cord tumor	Calretinin, inhibin

\*The diagnosis can be established by a combination of these antibodies and integrated into the appropriate morphological context.  
 HG-ESS, high-grade endometrial stromal sarcoma; LG-ESS, low-grade endometrial stromal sarcoma; LMS, leiomyosarcoma; NTRK, neurotrophic tyrosine receptor kinase; PEComa, perivascular epithelial cell tumor; STUMP, smooth muscle tumor of uncertain malignant potential; UUS, undifferentiated uterine sarcoma.

Identifying high-grade transformation or dedifferentiation of LG-ESS relies on increased nuclear atypia and mitotic index and/or loss or altered expression of estrogen and progesterone receptors (ER and PR). Some histologically transformed ESS harbor *ESR1* hotspot mutations that predict resistance to some endocrine therapies.<sup>25–28</sup> Tumors with overlapping histologic and immunophenotypic features of ESS and PEComa may harbor *TSC2* mutations and respond to mammalian target of rapamycin (mTOR) inhibition and endocrine therapy.<sup>26</sup> The diagnosis of HG-ESS is based on morphology and immunohistochemistry (see Table 1). Molecular analysis is strongly encouraged in the setting of LG-ESS with unusual histologic and/or immunophenotypic features, HG-ESS, and UUS to

confirm genetic alterations (ie, *BCOR*, *BCORL1*, *YWHAE*) diagnostic of HG-ESS.<sup>1 26 29–36</sup> Morphology remains the cornerstone in the diagnosis of adenosarcoma. Immunohistochemistry can confirm heterologous rhabdomyosarcomatous differentiation or assignment of high grade. Adverse prognostic factors include sarcomatous overgrowth (defined by the presence pure sarcoma occupying ≥25% of the tumor), high-grade histology, lymph vascular invasion, and myometrial infiltration (see Table 2).<sup>1 37–39</sup> Molecular tests may identify potentially targetable mutations in adenosarcomas (eg, *KRAS*, *PIK3CA* etc.).<sup>40</sup> The diagnosis of PEComa is based on morphology, and melanocytic marker expression (see Table 1).<sup>1 41–44</sup> Two molecular subtypes of PEComa have been identified: one linked to *TSC1/2* mutations and another associated with *TFE3* rearrangements (for the elements of classifications, see Table 3).<sup>45 46</sup> *TSC*-altered demonstrate immunohistochemical positivity for both melanocytic and myogenic markers, as well as cathepsin K<sup>44,47</sup>. *TFE3*-rearranged PEComas show melanocytic markers without myogenic markers. *NTRK*-rearranged uterine sarcomas are defined by fibrosarcoma-like morphology, absence of smooth muscle marker and hormonal receptor expression, and confirmation of a *NTRK* fusion. These tumors tend to occur in the uterine cervix of pre-menopausal women. Pan-Trk immunohistochemistry is a useful screening tool, but requires molecular confirmation of a *NTRK* fusion for diagnostic confirmation and eligibility for *NTRK* inhibition.<sup>15 47–52</sup>

## Recommendations

### General Diagnosis

- ▶ Pathological diagnosis should be confirmed by a pathologist with expertise and experience in the diagnosis of gynecologic mesenchymal tumors, preferably at a sarcoma reference center (IV, A).
- ▶ Molecular testing may be required to confirm pathological diagnosis and to identify therapeutic targets (IV, C).
- ▶ According to ICCR data set, there is not a minimum recommended number of blocks (V, B).
- ▶ Sampling should be based on a careful macroscopic examination and follow ICCR guidelines (V, B).
- ▶ For challenging diagnoses additional/extensive sampling is necessary (eg, differential diagnosis of sarcoma from carcinosarcoma, LG-ESS from HG-ESS, STUMP from LMS) (V, B).
- ▶ For low-grade tumors, biopsy can be used for diagnosis only in advanced stage disease. For stage I, biopsy is challenging to establish diagnosis (eg, differential diagnosis between endometrial stromal nodule and LG-ESS) (IV, B).

### Immunohistochemistry

- ▶ Immunohistochemistry is recommended to refine the diagnosis and inform therapeutic decisions, especially when molecular diagnostics are not available. However, many markers may not be specific or diagnostic alone and should be interpreted in conjunction with morphology (IV, B).
- ▶ A non-exhaustive list of diagnostic immunohistochemical markers includes (IV, B):
  - Smooth muscle tumors: desmin, h-caldesmon, smooth muscle actin

**Table 2** FIGO staging for uterine sarcomas<sup>218</sup>

Stage	Definition
Leiomyosarcomas and endometrial stromal sarcomas	
I	Tumor limited to the uterus
IA	Less than 5 cm
IB	More than 5 cm
II	Tumor extends beyond the uterus, within the pelvis
IIA	Adnexal involvement
IIB	Involvement of other pelvic tissues
III	Tumor invades abdominal tissues (not just protruding into the abdomen)
IIIA	One site
IIIB	More than one site
IIIC	Metastasis to pelvic and/or para-aortic lymph nodes
IV	IV A Tumor invades bladder and/or rectum
IVB	Distant metastasis
Adenosarcomas	
I	Tumor limited to the uterus
IA	Tumor limited to endometrium/endocervix with no myometrial invasion
IB	Less than, or equal to, half myometrial invasion
IC	More than half myometrial invasion
II	Tumor extends to the pelvis
IIA	Adnexal involvement
IIB	Tumor extends to extra-uterine pelvic tissue
III	Tumor invades abdominal tissues (not just protruding into the abdomen)
IIIA	One site
IIIB	More than one site
IIIC	Metastasis to pelvic and/or para-aortic lymph nodes
IV	IV A Tumor invades bladder and/or rectus
IVB	Distant metastasis
Carcinosarcomas	
Carcinosarcomas should be staged as carcinomas of the endometrium	
Simultaneous tumors of the uterine corpus and ovary/pelvis in association with ovarian/pelvic endometriosis should be classified as independent primary tumors.	

- Fumarate hydratase (FH) deficient smooth muscle tumors: FH and 2SC
- LMS: *ATRX*, *RB*, *PTEN*, *p53*, *DAXX*, *MTAP*, *MDM2*
- Endometrial stromal tumors: CD10, IFITM1, Cyclin D1, BCOR
- PEComa: HMB45, Melan A, TFE3
- *NTRK*-rearranged sarcomas: Pan-TRK, CD34, S100
- p53 useful in distinguishing between complex genomic sarcomas (aberrant expression in LMS, UUS) and simple

genomic sarcoma (wild-type expression fusion driven sarcomas such as LG-ESS, HG-ESS, *NTRK*-rearranged sarcoma)

- ER, PR, ALK, ROS-1, Pan-TRK

#### Ancillary techniques

- ▶ Molecular tests are recommended to confirm fusion and/or mutation status for diagnosis and/or therapeutic decision making. Suspected therapeutic targets (eg, *NTRK*, *ALK*, *ROS* fusions) require molecular confirmation. Assays may include FISH, RNA and/or DNA sequencing for fusion confirmation and DNA sequencing for mutation confirmation (IV, B).

#### uLMS

- ▶ The diagnosis is based on combination of morphology (2020 WHO and ICCR criteria) and immunohistochemistry (for smooth muscle differentiation) (IV, B).

#### HG-ESS

- ▶ The diagnosis of HG-ESS is based on morphology (atypia, mitotic count and necrosis, frequent lymphovascular invasion) and immunohistochemistry (frequent Cyclin D1 and/or BCOR overexpression and/or altered ER/PR expression). This can be associated with a low-grade component (IV, C).
- ▶ Molecular analysis is indicated and encouraged to detect *BCOR*, *YWHAE*, or *BCORL1* alterations (IV, B).

#### UUS

- ▶ Especially in UUS with uniform histology, immunohistochemistry and molecular studies (RNA sequencing) are indicated to exclude other tumor types (IV, B).

#### LG-ESS

- ▶ An endometrial stromal tumor with permeative (tongue-like) infiltration of the myometrium (>3 finger-like projections measuring >3 mm from tumor periphery) and/or lympho-vascular invasion is diagnostic of LG-ESS. Detection of LG-ESS associated fusions may be helpful (IV, C).

#### Adenosarcoma

- ▶ The diagnosis is based on morphology (IV, B).
- ▶ The following aggressive prognostic factors should be taken into account (IV, B):
  - Sarcomatous overgrowth
  - High-grade component
  - Lympho-vascular invasion
  - Myometrial infiltration

#### PEComa

- ▶ The diagnosis is made based on a combination of morphology (perivascular epithelioid cells) and melanocytic markers (HMB45, Melan A) (IV, B).

#### *NTRK*

- ▶ Confirmation of *NTRK* fusion status by molecular methods is essential given pan-Trk expression in other uterine sarcoma subtypes (HG-ESS and uLMS) (IV, B).

#### PRINCIPLES OF PRE-/POST-OPERATIVE IMAGING

The pre-operative work-up for suspicious uterine smooth muscle tumors is presented in [Figure 3](#). Based on the literature, the

## Society statement

**Table 3** Risk stratification of gynecologic PEComas<sup>1 42 43 219</sup>

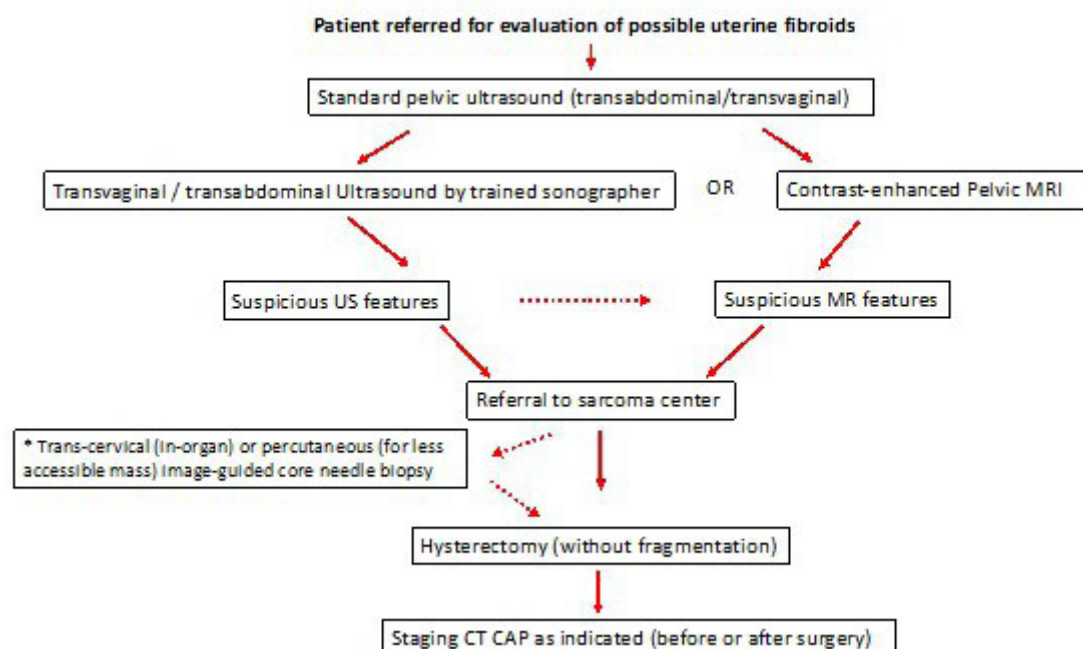
	General criteria	Modified gynecologic+specific criteria
Benign	<5 cm, non-infiltrative Non-high nuclear grade Mitotic count of $\leq 1$ mitosis/12 mm <sup>2</sup> No necrosis No vascular invasion	–
Uncertain malignant potential	Nuclear pleomorphism/multinucleated giant cells or <5 cm	Less than three of the following features: ▶ $\geq 5$ cm ▶ High nuclear grade ▶ Mitotic count of $> 1$ mitosis/12 mm <sup>2</sup> ▶ Necrosis ▶ Vascular invasion
Malignant	Two or more of the following features: ▶ $> 5$ cm ▶ Infiltrative ▶ High nuclear grade ▶ Mitotic count of $> 1$ mitosis/12 mm <sup>2</sup> ▶ Necrosis ▶ Vascular invasion	Three or more features

Mitotic count: 1 mitosis in 50 high-power fields of diameter 0.55 mm, area 0.24 mm<sup>2</sup>.

suspicious imaging findings for uterine sarcoma which should be looked for on ultrasound are in general solid masses with inhomogeneous echogenicity (the ‘cooked appearance’) with irregular tumor borders, and sometimes irregular cystic areas. Rarely seen is fan shaped shadowing or calcifications. Most are moderately or very well vascularized.<sup>53–55</sup> The ultrasound protocol is described in Box 1. If suspicious characteristics are seen on ultrasound, a pelvic MRI is suggested. Alternatively, second-opinion ultrasound could be performed at a dedicated gynecological cancer facility by an expert

in ultrasound imaging (level III, European Federation of Societies for Ultrasound in Medicine and Biology).<sup>56</sup>

On MRI, the following eight features should be looked for to determine the likelihood of a sarcoma<sup>57 58</sup>: on T2 weighted imaging (WI) heterogeneity and hyperintensity of solid enhancing component; on T1WI (pre-contrast): intra-tumoral hemorrhage; on T1WI (post-contrast): heterogeneous enhancement, enhancing finger-like projections, ill-defined borders with the myometrium, central necrosis; on diffusion -weighted imaging (DWI) restricted



**Figure 3** Pre-operative work-up in uterine smooth muscle tumors. \*Immediate hysterectomy is not accepted by patient (fertility desire, etc). CT CAP, CT scan of chest, abdomen, and pelvis. Dashed line indicates possible additional steps.

### Box 1 Ultrasound protocol for uterine mass characterization.

#### EXAMINATION OF THE UTERINE MASS

High-resolution gray-scale and color Doppler transvaginal scan is preferred generally, allowing for detailed assessment of the endometrium and myometrium. Transabdominal scan may be necessary for imaging beyond the small pelvis.

Examination by transvaginal approach commences with a dynamic two-dimensional scan of the uterus in two perpendicular planes.

Three-dimensional ultrasonography enables the offline examination and manipulation of ultrasound images. In difficult cases this may facilitate access to a second opinion from an expert examiner. Coronal sections of the uterus provide information on the external uterine contour and cavity shape.

Myometrial pathology should be described using standardized MUSA (Morphological Uterus Sonographic Assessment) terms.

diffusion (apparent diffusion coefficient value  $<0.9$ ). Having more than four features raises suspicion. The MRI protocol is described in Table 4.

For indeterminate masses, positron emission tomography with 2-deoxy-2-(fluorine-18) fluoro-D-glucose integrated with computed tomography (18F-FDG PET/CT) can be considered as a second-line of imaging evaluation. While the mean standardized uptake value of uterine sarcomas has in general been shown to be higher than that of uterine leiomyomas, false positives can occur with cellular or very vascular leiomyomas.<sup>59</sup>

Only in cases with suspicious imaging features but where immediate hysterectomy is not an option, should pre-operative ultrasound guided transuterine cavity (in-organ) or percutaneous (for less accessible mass) core needle biopsy ( $\geq 14$ – $16G$ ) of the most suspicious lesion be performed, with expert pathologic review using microscopic and genomic analysis.<sup>21 60–63</sup>

**Table 4** MRI protocol for uterine mass characterization for 1.5T and 3.0T<sup>58</sup>

Sequence	Comment
Sagittal T2WI without fat saturation	Slice thickness $\leq 4$ mm
Axial T2WI without fat saturation	Slice thickness $\leq 3$ mm
Axial in-and-out of phase T1WI	Slice thickness $\leq 4$ mm
Axial DWI	Same location as T2WI; slice thickness $\leq 4$ mm ; <i>b</i> value 0–50 and $1000 \text{ s/mm}^2$ or greater
Pre- and post-contrast 3D T1WI with fat saturation	Pre-contrast followed by post-contrast phases performed 30–40 s after contrast injection; delayed images taken with up to 3 min delay; slice thickness $\leq 3$ mm
DWI, diffusion-weighted imaging; T2WI, T2 weighted imaging.	

### Recommendations

#### General Recommendations

- ▶ In cases with atypical uterine fibroid findings on baseline pelvic ultrasound scans, the patient should be referred to MRI or specialized ultrasound (V, B).
- ▶ The interpretation should be performed by subspecialist radiologists evaluating specific MRI features (V, A).
- ▶ Specialized ultrasound examination should preferably be performed in a specialized cancer center by an experienced sonographer fully dedicated to the imaging of gynecological cancers (V, A).

#### Tailoring Surgery in Patients with Symptoms, High-risk Factors, Fertility Needs, Suspicion on Ultrasound or Pelvic MRI

- ▶ Pre-operative pelvic MRI (preferably), or transvaginal/transabdominal ultrasound performed only by an expert sonographer at a highly specialized site to assess the mass and to determine if features associated with a higher likelihood of sarcoma are present, is recommended (IV, B).
- ▶ In patients with suspicious imaging features in whom hysterectomy is not immediately feasible, pre-operative image-guided biopsy is an option in a specialized cancer center by an experienced sonographer or interventional radiologist, while also making the patient aware that false negatives may exist with this pathway (IV, B).
- ▶ Pre-operative ultrasound guided transuterine cavity (in-organ) core-needle biopsy ( $\geq 14$ – $16G$ ) of the most suspicious lesion should be performed with expert pathologic review using microscopic and molecular analysis as needed (IV, B).
- ▶ Percutaneous biopsy using coaxial needle (for less accessible masses) may be an option but should be used with caution in a specialized center (IV, C).

#### Patients Incompletely Resected with Malignant Uterine Smooth Muscle Tumors and Patients with Incidental Findings of Malignant Uterine Smooth Muscle Tumors after Hysterectomy

- ▶ Chest/abdomen/pelvis contrast-enhanced CT scan or abdominal/pelvic MRI plus chest CT scan are recommended for evaluation of locoregional tumor extension and distant metastases (IV, B).
- ▶ 18F-FDG PET/CT in the specific case of indeterminate lesions can be considered (IV, B).

### PRINCIPLES OF SURGERY

Minimally invasive techniques may cause rupture of the uterus with the possible dissemination of the sarcoma within the abdominal cavity. This could happen even during a simple hysterectomy in 0.27% of cases.<sup>64</sup> In addition, laparoscopic or robotic surgery is associated with the use of morcellation of the specimen, which might lead to a higher risk of recurrence and reduced survival if a uterine sarcoma is diagnosed.<sup>65</sup> Only in cases when integrity of the uterus can be assured, should minimally invasive techniques be considered.<sup>66</sup> There are no consistent data available on the impact of hysteroscopic surgery on the prognosis of uterine sarcomas (ESS mainly).<sup>67</sup> As intraperitoneal fragmentation or morcellation worsens the prognosis, such procedures should be discouraged.<sup>68–70</sup> Morcellation is reported with varying frequency in the available literature. According to an analysis of the German prospective

## Society statement

sarcoma registry, morcellation was performed in 11.4% of patients with sarcoma who underwent hysterectomy.<sup>71</sup> As shown in different studies morcellation of occult sarcoma is associated with a worse prognosis and higher mortality.<sup>72–74</sup> There are no high-quality data regarding electromechanical morcellation containment systems in gynecology.<sup>14</sup> The largest study to evaluate this was a multicenter prospective study of 76 patients who underwent contained electromechanical morcellation for hysterectomy or myomectomy.<sup>75</sup> Spillage of tissue or dye was assessed by gross visualization and was found in 9.2% of cases, although containment bags were intact.

No imaging method has been able to rule out sarcoma pre-operatively with certainty and no pre-operative scoring system is applicable to routine clinical practice to date.<sup>76</sup> If risk factors are identified, morcellation should be strictly avoided. The following are considered risk factors for occult sarcoma of the uterus: peri- or post-menopausal age, fast growing or new myoma, recent onset of symptoms such as abdominal pain or vaginal bleeding, and tamoxifen exposure.<sup>77</sup> Anemia and an increase of serum lactate dehydrogenase levels may provide additional information, but sensitivity is very low.<sup>78</sup> In the event of morcellation of occult sarcoma, further investigations are recommended, including clinical assessment, a whole-body CT scan followed by surgery (eg, resection of cervical remnants) based on the standard approach for uterine sarcoma surgery, although this has not as yet been shown to have an effect on overall survival. In situations where there is evidence of macroscopic residual disease following morcellation, neoadjuvant chemotherapy should be discussed and considered in high-risk cases with high-grade sarcomas.

### Early Stage (FIGO I and II)

Surgery is the mainstay of management for early-stage uterine sarcoma. Pre-operative imaging and biopsy may help diagnose early-stage uterine sarcomas. In uterine sarcomas confined to the uterus, complete removal of the uterus (total hysterectomy) is the gold standard.<sup>5 79</sup> Bilateral salpingo-oophorectomy is usually performed in post-menopausal women, whereas it may be individualized in pre-menopausal women. Patients with LG-ESS or estrogen receptor positive uterine sarcomas had an increased recurrence rate when the ovaries were left in situ, but with no impact on overall survival.<sup>53 80–83</sup> Therefore, the benefits of ovarian preservation in young patients should be carefully weighed against the higher risk of disease recurrence. Pelvic and/or para-aortic lymph node metastases are unfavorable prognostic factors, but are uncommon in uterine sarcomas confined to the uterus.<sup>84 85</sup> Furthermore, there is no evidence that systematic pelvic and para-aortic lymphadenectomy improves survival outcomes.<sup>5 79 86</sup> Therefore, systematic pelvic and para-aortic lymphadenectomy is not recommended for patients with uterine sarcoma confined to the uterus.<sup>5 79 87 88</sup> However, lymph nodes that are suspicious for metastasis should be removed at surgery. Lymphadenectomy has little prognostic or therapeutic benefit in patients with uterine sarcoma.<sup>89–91</sup>

### Advanced Stage (FIGO III and IV)

The standard treatment of stage III uterine sarcoma of all histological subtypes is complete surgical resection of all macroscopic tumor similar to the approach used in ovarian cancer surgery, given one of the most important prognostic factors is the volume of

residual tumor following initial surgery.<sup>92 93</sup> This could include total hysterectomy, bilateral salpingo-oophorectomy, debulking of peritoneal lesions (peritonectomy), removal of bulky/suspicious nodes, organ or partial organ resection including partial small or large bowel resection, or splenectomy.<sup>82</sup> Guckenberger et al recently proposed a novel dynamic model of oligometastatic disease to aid decisions regarding radical local treatment for patients with oligometastases. The model is based on a number of binary disease characteristics including de novo oligometastatic disease; synchronous oligometastatic disease; metachronous oligorecurrence or induced oligometastatic disease following systemic therapy for polymetastatic disease. Surgery should be discussed and considered in patients with oligometastatic uterine sarcomas. Alternative local treatments can be considered if not resectable, with acceptable morbidity.<sup>94 95</sup> Stereotactic ablative radiotherapy could be an option as well as other ablative techniques.<sup>96</sup> Patients with extra-uterine disease have a higher rate of lymph node metastases than those with disease confined to the uterus.<sup>97 98</sup> Lymphadenectomy should be undertaken only if the lymph nodes are grossly enlarged intra-operatively.<sup>85</sup> A systematic review on the use of intraperitoneal hyperthermic chemotherapy did not demonstrate efficacy and yielded a mortality rate of 4%.<sup>99</sup> In patients with LG-ESS where complete tumor resection is not expected, endocrine treatment may be an effective option prior to surgery.<sup>100</sup> Reassessment of response performed after 3 months to identify good responders who could potentially benefit from surgical resection is an option.<sup>82</sup>

### Recurrent Disease

There is no established relapse-free interval threshold to support decisions about further surgery, but all cases should be evaluated by a multidisciplinary team. About half of patients with recurrent uterine sarcoma present with abdominal/pelvic disease alone and half with lung metastases only, with a median interval of 18 months to recurrence after complete removal of the primary tumor. In abdominal recurrences, it is important to have all the details of the previous surgery available, particularly the operation record and pathology report with a description of the resected specimen, which might provide information about contributing factors to recurrent disease. Histological subtype is crucial, and, when in doubt, reference pathologists must be involved. The German prospective sarcoma registry data show that LMS contributes to 60% to 70% of patients with recurrent disease.<sup>71</sup> In LG-ESS, cytoreduction can potentially improve outcomes when combined with endocrine treatment.<sup>101–103</sup> Relapsed adenocarcinoma without sarcomatous overgrowth, LG-ESS, and estrogen receptor positive tumors could be treated with endocrine therapy alone, or surgery followed by endocrine therapy, similar to the approach in recurrent LG-ESS.

A local recurrence after incomplete resection is located typically in the region of the lateral pelvic uterine vessels. Given the challenge in obtaining clear margins, for some histological subtypes chemotherapy and/or radiation therapy can be offered prior to surgical resection.<sup>104</sup> In cases of disseminated recurrence, the tumor type is most commonly a high-grade sarcoma. Surgery usually cannot control abdominal spread without effective systemic treatment. Depending on the systemic therapy regimen used, 2–4 cycles should be administered prior to considering surgery in carefully selected cases who have a good response to treatment. Surgery should be considered if complete resection can be



achieved. Debulking should be as radical as possible, although post-operative quality of life must be taken into account. Post-operative systemic therapy should be discussed depending on the result of surgery and the histological subtype. The extent of surgical resection is a highly significant predictor of survival. Patients with no gross residual disease have better survival than those whose disease was not amenable to complete resection.<sup>105</sup> In the scenario of abdominal or distant recurrence after prior complete surgery, the time interval to recurrence as well as the number and location of metastases are critical for making decisions about further surgery. If the Guckenberger et al criteria for oligometastatic disease are fulfilled, surgery is indicated as an initial approach.<sup>94</sup> Resection of lung or liver metastases can potentially be performed with low morbidity in the relapsed disease setting.<sup>104 106</sup>

### Special Situations

#### Initial Surgery with Residual Disease

In the setting of an incidental diagnosis of uterine sarcoma after total hysterectomy or supracervical (subtotal) hysterectomy, expert pathologic review and imaging studies are warranted. Pelvic MRI is beneficial to evaluate local tumor extension.<sup>107</sup> If the tumor was initially morcellated or the cervix was left, re-exploration of the abdominopelvic cavity with resection of residual disease and/or the cervix should be considered.<sup>108</sup> For incidental diagnosis of uterine sarcoma after myomectomy, expert pathologic review and imaging studies are also warranted. If the tumor is confined to the uterus, a total hysterectomy is recommended. If extra-uterine disease is suspected and surgically resectable, resection of metastatic disease is recommended along with a total hysterectomy.<sup>108</sup> If bilateral salpingo-oophorectomy was not conducted initially, it should be considered in post-menopausal women.

#### Ovarian Preservation

Large population-based studies in pre-menopausal patients show that retention of ovaries during primary surgery is not associated with inferior overall survival.<sup>53 68 83 109 110</sup> This is particularly important in young women, owing to the impact of surgical castration on quality of life. Furthermore, there is an option for ovarian preservation in selected patients since gametes are available for surrogacy. In the absence of any survival benefit, there is no indication to perform bilateral salpingo-oophorectomy in cases of pre-menopausal uterine sarcoma, unless the ovaries are involved.<sup>111</sup> This applies to all subtypes of uterine sarcoma.

In recurrent adenosarcoma without sarcomatous overgrowth and LG-ESS in pre-menopausal women with ovaries in situ, bilateral oophorectomy or ovarian suppression with gonadotropin-releasing hormone (GnRH) analogs should be considered to decrease the estrogen levels.

#### Uterine Preservation

Preservation of the uterus in the majority of young women is not recommended, since most uterine sarcomas invade into the corpus uteri and there is a high chance of recurrent disease, even in early-stage sarcomas. There is some evidence to support the potential for fertility preservation and subsequent pregnancy in carefully selected patients.<sup>112–115</sup> However, there are a number of concerns associated with conservative surgery and leaving the uterus in situ. First, there is an increased risk of local recurrence due to presence

of residual sarcoma, which can result in a fatal outcome. Second, sarcoma cells might spread to the peritoneal cavity during hysteroscopic resection and reduce survival. Finally, surgically induced myometrial damage might complicate future pregnancies. In a recent systematic review of the literature, a fatality rate of 57% (4/7) was reported for LMS managed conservatively.<sup>112</sup> Although the recurrence rate for LG-ESS was 54% (34/63), the fatality rate was only 2% (1/63). Figures were best for adenosarcoma where in 19 cases, there were no recurrences in patients managed conservatively.<sup>112</sup> The duration of follow-up was variable but generally less than 5 years. In cases where LG-ESS can be completely removed (ie, confined to a polyp), uterine conservation may be considered in highly motivated and adequately informed patients, or in patients with low-grade adenosarcoma without sarcomatous overgrowth.<sup>112</sup> Given the low numbers, further safety assessment is warranted. The fatality rate for high-grade uterine sarcomas is too high and fertility preservation should not be considered. Thus, tumor biology, resection margins, and wish of the patient are crucial factors that need to be taken into consideration when a fertility-sparing option is discussed. Hysterectomy can be considered after the completion of pregnancy and delivery.<sup>82</sup>

### Recommendations

#### General Recommendations

- ▶ An open approach should be the preferred route of surgery in most cases (IV, B).
- ▶ Only in cases when integrity of the uterus can be assured, minimally invasive techniques may be considered (IV, C).
- ▶ Morcellation should always be avoided in cases with pre-operative suspicion of uterine sarcoma—for example, rapid growing mass or suspicious appearances on MRI (II, A). Patients undergoing morcellation for an apparently benign condition must be counseled on the low risk of unsuspected sarcoma even in an apparently benign lesion (V, A).

#### Early Stage (FIGO I and II)

- ▶ Complete removal of the intact uterus is the gold standard of surgical management (III, A).
- ▶ Bilateral salpingo-oophorectomy is the standard of care in post-menopausal women (III, A).
- ▶ In pre-menopausal women with stage I disease, ovarian preservation with bilateral salpingectomy could be considered in selected cases regardless of the histological subtype to avoid the need for post-menopausal endocrine therapy (IV, C).
- ▶ Routine systematic lymphadenectomy should not be performed (III, D).
- ▶ Suspicious nodes or peritoneal lesions should be removed as well (IV, B).

#### Advanced Stage (FIGO III and IV)

- ▶ For stage III, complete surgical removal of disease is the gold standard, including total hysterectomy and bilateral salpingo-oophorectomy and resection of any other suspicious lesions including peritoneal disease and/or bulky/suspicious nodes (IV, A).
- ▶ For stage IV, the option for primary resection depends on the number and location(s) of metastases as well as the biology and histological subtype. Surgery should be considered in primary

## Society statement

oligometastatic disease together with complete surgical resection of primary tumor if it is deemed feasible with acceptable morbidity (IV, A).

- ▶ Lymphadenectomy should be undertaken only if the lymph nodes are grossly enlarged intra-operatively or suspicious for metastases on pre-operative diagnostic work-up (IV, B). There is no indication for routine systematic lymph node dissection (IV, D).
- ▶ In cases of initially unresectable uterine sarcoma, primary systemic treatment is an option followed by re-evaluation for surgery depending on response (IV, B).

### Recurrent Disease

- ▶ All cases should be evaluated by a multidisciplinary team to determine if surgery is a reasonable and feasible option for all types of uterine sarcomas, with the primary goal of complete resection (V, A).
- ▶ Selection of the best candidates for surgery should be based on the following criteria (V, B):
  - Tumor biology and histology;
  - Localization of relapse, number of lesions, and tumor burden;
  - Recurrence-free interval (although there is no validated cut-off point);
  - Performance status;
  - Severity of co-morbidities;
  - Patient perspectives;
  - Potential complications;
  - Prior treatment.
- ▶ In particular, bilateral salpingo-oophorectomy should be considered in pre-menopausal patient subgroups with low-grade uterine sarcoma (including LG-ESS and adenosarcoma without sarcomatous overgrowth) when the ovaries are in situ, to decrease endocrine stimulation (IV, B).
- ▶ In indolent uterine sarcomas (ie, LG-ESS, low-grade adenosarcoma without sarcomatous overgrowth, and selected low grade LMS), surgical resection might be a reasonable option in cases with second or third recurrences (IV, C).
- ▶ Re-laparotomy for recurrence in high-grade uterine sarcoma and adenosarcoma with sarcomatous overgrowth might be a valid option if disseminated disease is not present (IV, C).

### Special Situations

- ▶ In cases of unexpected diagnosis of sarcoma after myomectomy, a hysterectomy should be performed. If extra-uterine disease or residual disease is suspected and surgically resectable, complete resection is recommended along with the total hysterectomy (IV, B).
- ▶ Resection of a uterine sarcoma with preservation of the uterus is a non-standard approach and could only be considered in referral centers for highly-selected cases of LG-ESS and low-grade adenosarcoma without sarcomatous overgrowth with informed consent (V, C).
- ▶ Ovarian preservation should be considered in stage I sarcomas where hormonal and gametes preservation is desired (IV, B).

## UTERINE LEIOMYOSARCOMA

uLMS are the main subgroup of uterine sarcomas. According to data from European cancer registries, their incidence is in the range of 0.5/100 000/year, although this may be an underestimation due to difficulties in pathologic diagnosis on a population basis. Nonetheless, they fall within the category of rare cancers.<sup>116</sup> Their peak incidence is in the sixth decade. The main differential diagnosis is leiomyomas, which are very common.

In localized, stage I disease, total hysterectomy is the standard treatment. Post-operative radiation therapy is not indicated, based on the results of a negative randomized clinical trial.<sup>117</sup> Likewise, adjuvant chemotherapy is not standard due to the lack of evidence to indicate a survival benefit.<sup>118</sup> However, it is felt by many that this issue has not been resolved and remains an open question due to limitations with earlier trials. The available randomized evidence includes obsolete regimens in relatively small numbers of patients or is inconclusive.<sup>119–121</sup> Uncontrolled and observational retrospective evidence suggested that there might be benefit, but cannot support a firm recommendation as results are conflicting.<sup>122–125</sup> There is indirect evidence from two randomized trials of neoadjuvant or adjuvant chemotherapy in non-uterine soft tissue sarcomas, including LMS.<sup>126–127</sup> Thus, the inclusion of patients in new clinical trials is recommended. Some institutions do offer adjuvant chemotherapy to selected patients after discussing the uncertainty of available evidence and share the decision-making with individual patients.

In patients with locally advanced, stage II–III, disease, chemotherapy is commonly recommended following surgery, particularly in patients with more advanced disease (although an alternative option is delaying chemotherapy until progression, given that the aim of treatment is palliation, not cure). When surgery is not feasible, or considered unreasonable given the extent of disease, chemotherapy is an option, incorporating the most active regimens such as doxorubicin+trabectedin. This combination, which was more effective than doxorubicin alone in a randomized trial, or doxorubicin+dacarbazine, which combines two active drugs in LMS.<sup>128–130</sup> Depending on the symptoms and presentation, primary pelvic radiation therapy may also be an option. Pelvic radiation may be used as an adjuvant to surgery when the cervix and/or parametria are involved, given the high risk of pelvic relapse.

In pelvic/abdominal relapses, pre-operative or post-operative chemotherapy may be considered, following the same principles as for stage II–III disease.

If distant metastases are present, chemotherapy is the standard treatment, but surgery, or ablative procedures, can be used in selected patients based on the presence of more favorable prognostic factors. When prognostic factors are unfavorable, but the disease is considered resectable, chemotherapy may be used either pre- or post-operatively. The prognostic factors to consider include the site and the number of metastases and the disease-free interval as well as symptoms and performance status.<sup>131</sup> The role of surgery for metastases, particularly lung metastases, is supported by its extensive use in sarcomas and a large body of uncontrolled evidence.<sup>132–134</sup>

With respect to the regimens used in first-line systemic therapy of uLMS, there is randomized evidence that a multiagent chemotherapy regimen with doxorubicin and trabectedin improves

progression-free and overall survival.<sup>129 130</sup> Other active multi-agent combinations are doxorubicin+dacarbazine and gemcitabine+docetaxel.<sup>128 135</sup> Alternative options include single-agent doxorubicin, or single-agent gemcitabine, or liposomal doxorubicin, factoring in their lower toxicity in a palliative setting.<sup>136–138</sup> The choice of treatment is based on multiple factors, including age, symptoms, co-morbidities, site of metastases, site of progression, and patient preferences.

With respect to second-line systemic therapy in uLMS, the same regimens as used in the first-line setting can be considered, taking into account a number of factors, including response to first-line therapy, duration of response, adverse effects of treatment, as well as the cumulative dose of anthracyclines. The most commonly used single-agent therapies include trabectedin, gemcitabine, pazopanib, dacarbazine, although multiagent chemotherapy regimens including gemcitabine+dacarbazine or gemcitabine+docetaxel are also options. All these treatments are supported by prospective phase III or phase II trials with demonstration of improvement in progression-free survival.<sup>135 139–141</sup> The stepwise use of all these therapies may translate into medium-term disease control in patients with responsive disease.

There is a small subgroup of patients with uLMS that are often diagnosed as STUMP (smooth muscle tumor of uncertain malignant potential) and behave as low-grade malignancies with a lower risk of recurrence than the much more common high-grade uLMS. They can present with late recurrences in the abdomen or lung, and the course of disease is commonly indolent even in the advanced setting. Importantly, they can respond to endocrine therapy (with aromatase inhibitors or progestins).<sup>142</sup>

## Recommendations

### Localized Disease (FIGO Stage I) - Post-Operative Systemic Therapy

- ▶ Standard approach for uterine confined (non-morcellated) FIGO stage I is surveillance following surgery (II, B).
- ▶ Due to conflicting data on the benefit of post-operative chemotherapy and the high risk of relapse, inclusion of patients in randomized controlled trials is recommended (IV, B).
- ▶ Post-operative chemotherapy is not a standard treatment and may be discussed with a patient within a shared decision-making process due to the uncertainty of benefit (IV, C).

### Localized Disease (FIGO Stage I) - Role of Radiotherapy

- ▶ Post-operative radiotherapy is not the standard of care after hysterectomy (I, D).

### Locally Advanced Disease (FIGO Stages II–III) - Role of Chemotherapy

- ▶ Post-operative chemotherapy can be considered (V, B).
- ▶ Available medical regimens include doxorubicin-based regimens or gemcitabine+docetaxel for patients not able to receive doxorubicin (V, C).
- ▶ Pre-operative chemotherapy for stage III disease with doxorubicin+trabectedin (I, B) or doxorubicin+dacarbazine is recommended in an effort to improve surgical resectability (IV, B).

### Locally Advanced Disease (FIGO stages II–III) - role of radiotherapy

- ▶ Pelvic radiotherapy may be an alternative option as definitive treatment if surgery is not feasible or after incomplete pelvic surgery (R1/R2) (IV, C).
- ▶ Post-operative radiotherapy can be considered in high-grade LMS with involvement of cervix/parametria and/or positive margins (IV, C).

### Metastatic Disease - Role of Chemotherapy

- ▶ Systemic therapy is the standard treatment in the metastatic setting (I, A).
- ▶ Pre- or post-operative chemotherapy can be considered prior to, or after, local treatment with surgery/radiation dependent on prognostic factors—for example, extent and number and site of metastases and previous disease-free interval (IV, B).
- ▶ For first-line therapy, available regimens include:
  - Doxorubicin-based in combination with
    - Trabectedin (I, B)
    - Dacarbazine (IV, C)
  - Gemcitabine+docetaxel (II, C)
  - Doxorubicin or gemcitabine or liposomal doxorubicin as single agents based on clinical judgment—for example, when multi-agent chemotherapy is not feasible, etc (V, B).
- ▶ For second-line therapy and more, available regimens include:
  - The same regimen as above if not used as first-line therapy or if associated with previous response
  - Trabectedin (I, B)
  - Gemcitabine±dacarbazine (II, B)
  - Pazopanib (I, B)
  - Dacarbazine (I, B)

### Low-grade Metastatic Disease (Hormonal Receptor Positive) - Role of Endocrine Therapy

- ▶ In indolent disease, active surveillance can be offered as initial management (IV, B).
- ▶ In cases of progressive disease, endocrine therapy is recommended as the first-line treatment (IV, B).
- ▶ Available agents include:
  - Aromatase inhibitors or progestins for post-menopausal patients (IV, B).
  - Luteinizing hormone-releasing hormone agonists±aromatase inhibitors, provided that there is no evidence of transformation to a high-grade LMS, for pre-menopausal patients (IV, B).

### Relapse/Metastatic Setting - Role of Radiotherapy

- ▶ Radiotherapy could be considered as an alternative to surgery or as a pre- or post-operative therapy (III, C).
- ▶ Radiotherapy can be used for recurrent or metastatic LMS when symptoms of local disease impact quality of life (III, C).

## HIGH-GRADE ENDOMETRIAL STROMAL SARCOMA AND UNDIFFERENTIATED SARCOMA

HG-ESS and UUS collectively represent about 5% of uterine sarcomas. They are typically diagnosed around in 55–60 year olds, although cases have been reported in patients as young as 14 and as old as 75 years. There are no clear risk factors.<sup>131 143 144</sup> Unlike LG-ESS, which often have a favorable prognosis and a relatively indolent clinical course, HG-ESS and UUS are characterized by

## Society statement

aggressive behavior and poor prognosis.<sup>35 145</sup> At diagnosis, most patients present with advanced disease, with approximately 70% of them being FIGO stage III–IV (over 50% being stage IV).<sup>146</sup> Common sites of metastases include the peritoneal cavity, lungs, intra-abdominal lymph nodes, and bone.

For stage I disease, total hysterectomy is the standard treatment. Although post-operative radiotherapy is not routinely recommended, considering the high rate of local relapses, adjuvant radiotherapy may be considered on a case-by-case basis. Similarly, adjuvant chemotherapy is not standard practice due to the lack of evidence. However, several institutions do offer it as an option within a shared decision-making process considering the high risk of relapse following the approach to management of patients with high-risk somatic high-grade soft tissue sarcomas.

In locally advanced stage II and III disease, as well as in cases of morcellation, chemotherapy following complete surgery should be considered. In the relapsed disease setting, systemic treatment options should be discussed with patients, including pre-operative chemotherapy for pelvic/abdominal relapse. In cases of distant metastases, chemotherapy remains the cornerstone of treatment. First-line options include doxorubicin in combination with ifosfamide, or as a single agent, and gemcitabine with docetaxel for those not considered suitable for doxorubicin.<sup>126 130 138 147–149</sup> Subsequent lines of therapy may include high-dose ifosfamide, gemcitabine, and docetaxel, pazopanib, or trabectedin.<sup>141 149</sup>

For oligometastatic disease suitable for surgery, pre- or post-operative chemotherapy may be considered based on individual prognostic factors (eg, number and site of metastases, short previous relapse-free interval). Radiotherapy can be offered for recurrent or metastatic HG-ESS or UUS to alleviate local symptoms impacting quality of life or as an alternative to surgery for oligometastatic disease.<sup>117 150</sup> Submitting tumor tissue for next-generation sequencing analysis may help to identify potential candidates for clinical trials involving novel therapies.

### Recommendations

#### Early/Advanced Disease (FIGO Stages I–III) - Systemic Therapy

- ▶ Adjuvant chemotherapy is not the standard of care for stage I disease (IV, D).
- ▶ Adjuvant/post-operative chemotherapy could be considered in patients at a high risk of relapse after informed discussion and shared decision-making (IV, C).
- ▶ In cases of morcellation of a HG-ESS or an undifferentiated sarcoma, post-operative chemotherapy should be considered due to the high risk of relapse (IV, B).

#### Early/Advanced Disease (FIGO Stages I–III) - Radiotherapy

- ▶ Adjuvant radiotherapy is not standard after hysterectomy for localized disease (IV, D).
- ▶ Post-operative radiotherapy could be considered based on risks of local recurrence (IV, C).

#### Relapse/Metastatic Setting - First-line Systemic Treatment Options

- ▶ First-line systemic therapy options include doxorubicin (if not used in adjuvant setting) combined with ifosfamide or as a single agent (III, B); or gemcitabine with docetaxel for a patient not able to receive doxorubicin (IV, C).

- ▶ In patients with oligometastatic disease undergoing surgery, pre- or post-operative chemotherapy can be considered in individual patients on the basis of adverse prognostic factors—for example, number and site of metastases, short previous relapse-free interval (IV, B).

#### Relapse/Metastatic Setting - Systemic Options for Second-line Systemic Therapy

- ▶ Systemic therapy options include continuous infusion of high-dose ifosfamide; or gemcitabine and docetaxel; pazopanib or trabectedin as single agent. The choice depends on the agent used in first-line setting (IV, B).

#### Relapse and Palliative Setting - Role of Radiotherapy

- ▶ Radiotherapy could be considered as an alternative to surgery or as a pre- or post-operative therapy (IV, C).
- ▶ Radiotherapy can be used for recurrent or metastatic HG-ESS when symptoms of local disease impact quality of life (IV, C).

### LOW-GRADE ENDOMETRIAL STROMAL SARCOMA

LG-ESS account for approximately 20% of all uterine sarcomas, and are diagnosed at a mean age of around 50 years.<sup>53 151–153</sup> Obesity, diabetes, young age at menarche, and tamoxifen have been associated with increased risk of LG-ESS, although the molecular mechanisms involved are yet to be elucidated.<sup>143 154</sup> The majority (60%) of cases present with FIGO stage I disease, with only 20% presenting with stage IV metastatic disease (see Table 2).<sup>155</sup> The natural history is one of a slowly growing indolent tumor, and this is reflected by good outcomes. However, late relapses are relatively common, requiring long follow-up.

Hysterectomy, either open or by a minimally invasive technique, is the cornerstone of treatment for localized LG-ESS.<sup>156</sup> The incidence of lymph node metastases is low (less than 8%).<sup>83 156</sup> Traditionally, ovaries were removed at initial surgery as LG-ESS typically express hormones receptors, and a higher relapse rate might be expected if the ovaries are retained. Although this has less importance in post-menopausal women, the question regarding bilateral oophorectomy deserves particular consideration in young premenopausal women, as it appears from recent series that leaving the ovaries in situ does not worsen survival.<sup>86 152 157–161</sup> Oncological outcomes aside, maintenance of quality of life is important, and management of menopausal symptoms may be challenging in young women after oophorectomy. This is particularly the case as hormone replacement therapy has been associated with higher relapse rates in one small series with five patients and it is generally contraindicated in patients with ESS.<sup>162</sup> Uterus-sparing procedures remain an experimental procedure to be considered in highly selected cases in expert centers.<sup>82 113</sup> Given the very high rate of hormone receptor positivity in ESS, up to 100% in some series and evidence of objective responses in approximately 30% of patients with metastatic ESS including a high percentage with stable disease, adjuvant endocrine therapies have been considered in higher-risk patients following surgery.<sup>151 152</sup> The use of adjuvant endocrine therapy has been reported in several small retrospective studies, but the benefit for overall survival remains unknown, also given the long-term benefit with endocrine therapies on relapse.<sup>79</sup>

Several questions remain, such as the optimal dose of progestins, choice of endocrine therapy (progestins or aromatase inhibitors),

and duration of therapy. Although some consider a 2-year duration of endocrine treatment sufficient, in the absence of solid data, others believe that the treatment should be life-long. The benefit of cytoreductive surgery in locally advanced ESS is controversial; however, based on the tumor biology and natural history (indolent disease with primarily transperitoneal spread), cytoreductive surgery might be beneficial because of the 'low-grade' nature of the disease and the efficacy of additional endocrine therapy.<sup>79 82 113 162</sup>

Adjuvant pelvic radiotherapy does not influence overall survival since LG-ESS typically recurs distantly. Although a modest benefit in locoregional control can be achieved by post-operative radiotherapy, overall survival is not improved.<sup>163 164</sup> Palliative radiotherapy can be used for recurrent or metastatic LG-ESS, when symptoms of local disease reduce quality of life.

Recurrences of ESS are common even in early-stage disease, with a predilection for lungs and abdomen. Relapse can occur in 36–56% of patients with early-stage disease, with a median time to recurrence of 9 and 65 months for stages III–IV and I, respectively.<sup>159 162 165–167</sup> Although supportive data are lacking, repeat surgery for a disease that is indolent and hormone-sensitive is considered an acceptable approach. If the ovaries were previously retained in situ, bilateral salpingo-oophorectomy is advised when recurrence is diagnosed in pre-menopausal women.<sup>168</sup>

Endocrine therapies can be effective for metastatic disease and can be administered for long periods, as they are typically well tolerated in most patients; the optimal duration remains uncertain—that is, whether until progression or for a shorter period.<sup>159 165–171</sup>

De novo *ESR1* hotspot mutations may occur in LG-ESS following histologic high-grade transformation and/or altered estrogen receptor expression is associated with resistance to endocrine treatment with aromatase inhibitors. Larger series are required to further investigate the frequency of *ESR1* mutations and their role in endocrine treatment resistance. Recent findings suggest that genetic analyses may be performed in recurrent LG-ESS following endocrine therapy, development of high-grade morphology, and/or altered/diminished estrogen receptor expression.<sup>27</sup> Studies in breast cancer have shown that the mechanism of resistance to selective estrogen receptor modulators/aromatase inhibitors is distinct from that of selective estrogen receptor degraders.<sup>172</sup> Further studies are warranted to assess whether patients with *ESR1*-mutant ESS might benefit from estrogen receptor degraders rather than from other therapies. It is encouraged to submit recent tumor tissue for next-generation sequencing. An acquired *ESR1* mutation would support treatment with estrogen receptor degraders, such as fulvestrant or new-generation estrogen receptor degraders, rather than a switch to chemotherapy.

Tamoxifen is contraindicated in women with ESS due to the proliferative effect on the endometrial stroma and potential agonistic effect on estrogen receptor positive ESS.

Data on response of ESS to chemotherapy are scarce, since the literature dates back to the era where HG-ESS and LG-ESS were pooled and analyzed as a single disease entity. Thus, response rates to chemotherapy appear to be low, so that it should only be considered and prescribed after resistance to endocrine therapies or evidence of high-grade transformation.<sup>173</sup> Clinical trials with innovative therapies, in particular new endocrine therapies or a combination of endocrine therapies and CDK4-6 inhibitors or PI3KCA inhibitors, are of special interest.

## Recommendations

### Early/Advanced Disease - Role of Adjuvant Systemic Therapy

- ▶ Adjuvant endocrine therapy is not recommended for stage I uterine LG-ESS (IV, D).
- ▶ Post-operative endocrine therapy can be considered in patients with stage II, III–IV completely resected estrogen receptor/progesterone receptor positive uterine LG-ESS (IV, C).
- ▶ In cases of morcellation of uterine LG-ESS, consideration could be given to post-operative endocrine therapy due to greater risk of dissemination and recurrence (V, C).
- ▶ Endocrine therapy recommended regimens (IV, C):
  - Progestins (megestrol acetate, medroxyprogesterone acetate)
  - Aromatase inhibitors (anastrozole, letrozole, exemestane)
- ▶ Tamoxifen is contraindicated (V, D).

### Localized Disease - Role of Radiotherapy

- ▶ Adjuvant radiotherapy is not recommended (I, D).

### Relapse/Metastatic Setting - First-line Systemic Treatment Options

- ▶ Endocrine therapy is recommended for unresectable recurrent tumors (V, C).
- ▶ Reassessment after at least 3 months of neoadjuvant endocrine therapy may identify a subset of patients with sufficient tumor response to consider debulking surgery (V, C).
- ▶ Endocrine therapy recommended regimens (V, C):
  - Progestins (megestrol acetate, medroxyprogesterone acetate)
  - Aromatase inhibitors (anastrozole, letrozole, exemestane)
  - Luteinizing hormone-releasing hormone agonists±aromatase inhibitors for pre-menopausal patients with ovarian function
  - Leuprolide
- ▶ Tamoxifen is contraindicated, owing to potential agonistic effect on estrogen receptor positive ESS (V, D).

### Relapse/Metastatic Setting - Systemic Treatment Options for Second-line Therapy

- ▶ Second-line endocrine therapy with an aromatase inhibitor/progestin/GnRH analogs or an estrogen receptor antagonist such as fulvestrant should be offered to patients with recurrent/metastatic LG-ESS with disease progression after first-line endocrine therapy (V, B).
- ▶ Following disease progression and/or high-grade transformation on endocrine therapy (including several lines), chemotherapy regimens as per high-grade tumors could be considered in selected cases (V, C).

### Relapse/Metastatic Setting - Role of Radiotherapy

- ▶ Radiotherapy can be used for recurrent or metastatic LG-ESS for palliation (IV, B).

## ADENOSARCOMA AND MISCELLANEOUS

### Müllerian Adenosarcoma of the Female Genital Tract

Adenosarcomas are rare and account for 5–9% of uterine sarcomas. Approximately 20–30% arise from extra-uterine sites.<sup>144 174</sup> They usually occur in post-menopausal women, but 10% are diagnosed in adolescents and young women.<sup>144 174–176</sup> Pathologically, adenosarcomas are characterized by a benign epithelial component and

## Society statement

a malignant mesenchymal component which commonly resembles LG-ESS, although in 10–25% of cases the mesenchymal component is a high-grade sarcoma.<sup>144 174–176</sup> Adenosarcomas with >25% pure sarcoma are classified as adenosarcomas with sarcomatous overgrowth, which is associated with an adverse prognosis.<sup>174 177–179</sup> Uterine adenosarcomas are commonly stage I at presentation and have a relatively good prognosis.<sup>174 177–179</sup> Risk factors for recurrence include deep myometrial invasion, lymphovascular space invasion, sarcomatous overgrowth, spread beyond the uterus, morcellation, and extra-uterine origin.<sup>174 176–179</sup> The staging system for uterine adenosarcoma is the same as LG-ESS, described above. Most are stage I disease at diagnosis with 10–15% stages III or IV. The recommended treatment for uterine adenosarcomas is a total hysterectomy and bilateral salpingo-oophorectomy, as the majority of patients are peri-/post-menopausal.<sup>6 174 180</sup> The incidence of lymph node involvement is very low (3%) and routine lymphadenectomy is not recommended.<sup>181</sup> There is no evidence that bilateral oophorectomy in pre-menopausal patients with stage I low-grade uterine adenosarcomas impacts survival. There may be a role for fertility preservation in highly selected young women with stage IA low-grade uterine adenosarcomas without sarcomatous overgrowth.<sup>112 182 183</sup>

Post-operative/adjuvant radiotherapy should be individualized after taking into account risk factors associated with an increased risk of local recurrence (adjuvant refers to patients with stage I to II completely resected tumors no evidence of metastatic disease, while post-operative refers to patients with resected stage III or IV disease with high probability of residual disease).<sup>150</sup> Management of patients with low-grade uterine adenosarcoma is similar to that of patients with LG-ESS, while the management of patients with adenosarcomas with sarcomatous overgrowth is similar to that of patients with high-grade uterine sarcomas such as HG-ESS. Adjuvant endocrine therapy is not indicated in stage I uterine adenosarcoma with LG-ESS, but post-operative endocrine therapy can be considered in patients with stages II–IV following surgery, owing to the likely presence of residual disease.

The optimal duration of therapy is not known and is dependent on tolerance and assessment of clinical benefit. Post-operative chemotherapy can be considered as an option in patients with stages II to IV completely resected uterine adenosarcoma with a high-grade sarcomatous component due to the poor prognosis with supportive evidence from registry studies, although there is no strong evidence of a survival benefit.<sup>101 152 183–185</sup> In patients with advanced/metastatic adenosarcoma at diagnosis, management is based on tumor grade. Low-grade adenosarcoma should be managed similarly to patients with LG-ESS, with endocrine therapy until disease progression unless associated with unacceptable adverse effects. High-grade sarcomas should be managed with chemotherapy, similar to the approach in other high-grade uterine sarcomas due to similar efficacy with options including doxorubicin as a single agent or combined with ifosfamide.<sup>6 101 112 152 171 174 180–183 186–189</sup>

Second-line therapy depends on multiple factors, including the age of the patient and co-morbidities, prior therapy, sites of recurrence, time to recurrence, the number of metastases, as well as the sarcomatous subtype. In adenosarcoma with LG-ESS, second-line treatment should be similar to that for metastatic LG-ESS with endocrine therapy such as progestogens, aromatase inhibitors, GnRH analogs or fulvestrant, depending on what was used

in first-line therapy.<sup>190</sup> If possible, referral to clinical trials should be advised. Second-line chemotherapy in high-grade metastatic adenosarcomas follows management of patients with metastatic high-grade sarcomas arising in other sites, and clinical trials should be considered.<sup>191–193</sup>

### NTRK Fusion Gynecological Sarcomas

NTRK fusion-positive gynecological sarcomas are rare spindle cell tumors resembling fibrosarcomas. They were described as a specific entity in 2018 and typically involve the cervix or, less commonly, the uterine corpus with the potential for aggressive behaviour.<sup>47</sup> By immunohistochemistry, they are positive for pan-TRK and S100 with variable CD34 expression.<sup>47 52</sup> It is important to note that pan-TRK staining can be seen in other spindle cell gynecological sarcomas, and sequencing or FISH to confirm an NTRK fusion is advised.<sup>49 52</sup> Although rare, with fewer than 60 cases reported, establishing the correct diagnosis is important, as treatment with NTRK inhibitors is an option. *NTRK-1* fusions occur in 75% and *NTRK3* in 25% of cases with multiple possible fusion partners.<sup>52</sup> In the largest series of 35 cases, the majority were confined to the uterus/cervix and stage I. The prognosis for stage IA is very good, without recurrence reported following surgery, but there is a 40% risk of recurrence in stage IB.<sup>52</sup> Risk factors for recurrence include lymphovascular invasion and *NTRK3* fusions.<sup>52</sup> The mainstay of treatment is primary surgery, with a hysterectomy with ovarian preservation in pre-menopausal women. There are isolated case reports with fertility preservation as well as neoadjuvant NTRK inhibitors.<sup>194 195</sup> There are no data to support adjuvant chemotherapy or radiotherapy following surgery. There is a paucity of data on response to chemotherapy and the highest responses are reported with NTRK inhibitors. Most of the data to guide therapy are based on treatment of patients with non-gynecological NTRK fusion sarcomas, where durable response rates of 50–70% with entrectinib and larotrectinib have been reported. These should be offered depending on access and regulatory approval, including meeting criteria for use.<sup>196 197</sup> Next-generation TRK inhibitors to overcome resistance are being tested in clinical trials. Patients should be considered for clinical trials when available.

### PEComa of the Female Genital Tract

PEComas are rare mesenchymal tumors that can occur in multiple sites, with gynecological PEComas making up 25%.<sup>198</sup> They mainly involve the uterine corpus (70%) and less commonly the cervix (10%), vagina, adnexa, broad ligament, and vulva.<sup>198 199</sup> They can occur in patients with TSC with germline inactivation of TSC1/2, but are more commonly sporadic with evidence of loss of function of TSC1/2 in the majority of cases, leading to mTOR pathway activation.<sup>199 200</sup> A minority have rearrangements in *TFE3* with various fusion partners, which activates MET signaling and is associated with more aggressive biology and lower response to mTOR inhibitors.<sup>44</sup> PEComas are most commonly benign, but a proportion are of uncertain malignant potential or malignant, with a risk of local recurrence or metastases, most commonly to the lung. Malignant PEComas are characterized by a tumor size >5 cm, a high mitotic rate (>1/50 high-power field) necrosis, vascular invasion, and an infiltrative pattern.<sup>198 199</sup> Complete surgical resection with clear margins (R0), where possible, is

considered optimal treatment. Patients managed at specialized sarcoma surgery centers have better outcomes.<sup>201</sup> There are no data to support adjuvant radiation or chemotherapy and they are not recommended.<sup>202</sup> The reported response rates to chemotherapy are low and the median progression-free survival is short.<sup>203 204</sup> mTOR inhibitors, such as everolimus, sirolimus, and temsorolimus, have all been reported to have activity, with overall response rate of up to 40%.<sup>203–205</sup> More recently, the AMPECT trial of nab-sirolimus reported an overall response rate of 39% and led to US Food and Drug Administration (FDA) approval.<sup>205 206</sup> There was particularly high activity (overall response rate: 80%) in patients with *TSC2* mutations and no prior therapy, but responses are also observed in patients with *TSC1* mutations or no *TSC1/2* mutations, and FDA approval and National Comprehensive Cancer Network guidelines are not linked to mutation status.<sup>205</sup> Responses are durable and toxicities manageable. There are case reports of reversal of resistance with addition of an aromatase inhibitor, and responses reported to vascular endothelial growth factor tyrosine kinase inhibitors, such as pazopanib or apatinib, following progression.<sup>204 207 208</sup> The majority of PEComas arising in the gynecological tract are estrogen receptor/progesterone receptor positive.<sup>198</sup> There are isolated case reports of response to aromatase inhibitors as well as a report of reversal of resistance to sirolimus by the addition of letrozole with a partial response in three of six female patients with malignant PEComas.<sup>207 209</sup> These reports highlight the need for additional studies of endocrine therapy in PEComas.

## Recommendations

### Early/Advanced Disease - Systemic Therapy - Low-grade Adenosarcoma

- ▶ Adjuvant endocrine therapy is not recommended for stage I uterine adenosarcoma (IV, D).
- ▶ Post-operative endocrine therapy can be considered in patients with stage II, III–IV completely resected estrogen/progesterone receptor positive uterine adenosarcoma (IV, C).
- ▶ In the case of morcellation of uterine adenosarcoma with a low-grade sarcomatous component such as LG-ESS, adjuvant endocrine therapy could be considered owing to the high risk of dissemination and recurrence (V, C).

### Early/Advanced Disease - Systemic Therapy - High-grade Adenosarcoma or Sarcomatous Overgrowth

- ▶ Post-operative chemotherapy is not the standard of care for stage I disease (V, D).
- ▶ Adjuvant chemotherapy can be considered as an option in patients with stage II, III–IV completely resected uterine adenosarcoma due to the poor prognosis (IV, C).
- ▶ In the case of morcellation of a uterine adenosarcoma with a high-grade component/sarcomatous overgrowth, post-operative chemotherapy could be considered (V, C).

### Localized Disease - Radiotherapy

- ▶ Adjuvant radiotherapy is not recommended for stage I uterine adenosarcoma (IV, D).

- ▶ Post-operative radiotherapy could be considered in stage II–IV uterine adenosarcoma for local control, although there is no evidence to support a survival benefit (IV, C).

### Relapse/Metastatic Setting - First-line Systemic Treatment Options - Low-grade Adenosarcoma

- ▶ Endocrine therapy with an aromatase inhibitor, progestogen, or GnRH analogs should be offered to patients with recurrent/metastatic estrogen/progesterone receptor positive low-grade uterine adenosarcoma (IV, C).
- ▶ Tamoxifen should not be administered owing to potential agonistic effect on estrogen receptor positive adenosarcomas (V, E).

### Relapse/Metastatic Setting - First-line Systemic Treatment Options - High-grade Adenosarcoma with Sarcomatous Overgrowth

- ▶ Systemic therapy options include doxorubicin as a single agent or combined with ifosfamide (II, B); or gemcitabine in combination with docetaxel for patients who cannot receive doxorubicin (III, C).

### Relapse/Metastatic Setting - Systemic Treatment Options for Second-line Therapy - Low-grade Adenosarcoma

- ▶ Second-line endocrine therapy with an aromatase inhibitor/progestogen/GnRH analogs/fulvestrant could be considered, with the choice depending on the agent used in the first-line setting. Referral to clinical trials should be considered, if available (IV, C).

### Relapse/Metastatic Setting - Systemic Treatment Options for Second-line Therapy - High-grade Adenosarcoma with Sarcomatous Overgrowth

- ▶ Systemic therapy options include doxorubicin (II, B) or gemcitabine as a single agent or in combination with docetaxel (III, B); high dose ifosfamide (continuous infusion), trabectedin, or pazopanib as single agents (IV, C). The choice depends on the agent used in the first-line setting.

### Relapse/Metastatic Setting - Role of Radiotherapy

- ▶ Radiotherapy could be considered in stage IV uterine adenosarcoma for local control or palliation (IV, C).

### Special Considerations - Extra-uterine Adenosarcoma

- ▶ Extra-uterine adenosarcomas are very rare and potentially more aggressive and a similar approach to management of patients with uterine adenosarcoma is recommended (V, B).

### NTRK Gynecological Sarcomas

- ▶ The primary treatment of NTRK-fusion sarcomas arising in the genital tract is complete surgical resection for localized disease (V, B).
- ▶ The efficacy of radiotherapy and chemotherapy is unknown in the neoadjuvant/adjuvant setting. The role of NTRK inhibitors following surgery for localized disease is unclear and investigational and thus they are not recommended (IV, D).
- ▶ In patients with locally advanced disease, systemic treatment or radiotherapy can be considered to enable a subsequent resection with a curative intent. In this situation, the best response rates reported are with NTRK inhibitors (V, C).

## Society statement

- ▶ NTRK inhibitors should be offered to patients with recurrence after primary treatment (III, B).

### Miscellaneous, PEComas

- ▶ The primary treatment of perivascular epithelioid cell tumor arising in the genital tract is complete surgical resection for localized disease (V, B).
- ▶ There are no data to support adjuvant chemotherapy or radiotherapy (V, C).
- ▶ For locally advanced disease, mTOR inhibitors can be considered to avoid surgery with the potential for significant morbidity (IV, B).
- ▶ For metastatic disease, mTOR inhibitors are recommended as first-line treatment (IV, B); hormone blockade treatment for selected patients with estrogen/progesterone receptor positive tumors could be considered (IV, C).

## FOLLOW-UP & SURVIVORSHIP

The goal of follow-up after the initial therapy is to diagnose relapse and address potential long-term toxicities and complications of treatment. There are few published data to indicate the optimal follow-up policy of surgically treated patients with localized disease. A holistic approach should be adopted for the long-term follow-up and care of women treated for uterine sarcomas, including monitoring for bone density, chronic post-treatment toxicity, and secondary malignancies. Particular attention should be given to cardiac monitoring for patients treated with anthracycline-based chemotherapy, as per international guidelines.<sup>210</sup>

The tumor grade affects the likelihood of relapses and the interval at which they might occur. Risk assessment based on histological type, tumor grade, size, and site help in choosing a routine follow-up policy. High-risk patients generally relapse within 2–3 years, whereas low-risk patients may relapse much later. Relapses most often occur in the lungs. The use of MRI to detect pelvic local relapse and CT for visceral metastases is likely to pick up recurrences earlier than other assessment/imaging modalities. In addition, for women treated with radiation therapy, consideration should be given to the development of secondary malignancies and other long-term complications of radiation. Due to the limited available evidence for survivorship care in uterine sarcomas, extrapolation from published guidelines for gynecological carcinomas could be considered, with follow-up tailored to the particular needs of an individual patient based on the treatment received.<sup>211</sup>

Young women with retained hormonal function should have long-term follow-up due to the risk of recurrent disease. Alternatives to hormone replacement therapy are available and these could be considered for treating patients with LMS with menopausal symptoms. Prospective studies are needed, but a reasonable approach for patients for whom we anticipate feasible treatment could be as follows: imaging surveillance tailored according to the risk of systemic metastases if high grade. Systematic imaging surveillance can be discontinued after 10 years.

## Recommendations

### Follow-up

- ▶ There is a lack of evidence to guide a precise follow-up protocol but due to the possibility of developing asymptomatic/oligo-metastatic disease, regular follow-up is advised (IV, B).

- ▶ Patients should be informed about symptoms that could suggest recurrence and the importance of seeking prompt medical attention (V, B).
- ▶ A reasonable approach for patient for whom we anticipate feasible treatment could be as follows:
  - History+physical examination (V, B)
    - Every 3–4 months for the first 3 years; every 6–12 months thereafter;
    - Patients with low-grade sarcoma are usually followed up for local relapse every 4–6 months for the first 3–5 years, then yearly.
  - 18F-FDG PET/CT is not recommended but may add information in clinically inconclusive situations (IV, C).
  - Imaging surveillance: tailored according to the risk of systemic high-grade metastases (IV, B). Systematic imaging surveillance can be discontinued after 10 years (V, B).
    - CT chest/abdominal/pelvis:
      - High grade: every 3–4 months at least in the first 3 years, then every 4–6 months, and then from the fifth year annually;
      - Low grade: every 4–6 months in the first 3 years, then annually.
    - MRI abdominal/pelvis+CT chest as an alternative
- ▶ Long-term follow-up is advised as late and distant relapses are not uncommon, particularly for low-grade tumors (IV, C).

### Survivorship

- ▶ Long-term follow-up/survivorship should be tailored to the treatment received (IV, B).
- ▶ New imaging abnormality identified on follow-up imaging should not be automatically assumed to be a recurrence of gynecological sarcoma (IV, D). Biopsy should be performed (IV, B).

### Hormone Replacement Therapy

- ▶ LG-ESS:
  - Hormone replacement therapy is contraindicated owing to the potential risk of recurrent disease (IV, B).
  - Hormone replacement therapy could be considered in selected symptomatic cases in whom menopausal symptoms cannot be controlled and there is a significant impact on quality of life (IV, C).
  - Close collaboration with gynecological/endocrine team is recommended (V, B).
- ▶ HG-ESS+uterine sarcoma:
  - Hormone replacement therapy could be considered following discussion with individual patients (IV, C).
- ▶ LMS:
  - Estrogen/progesterone receptor negative expression: hormone replacement therapy could be considered (IV, C).
  - Given heterogeneity of clinical disease for estrogen/progesterone receptor positive LMS, hormone replacement therapy could be considered on a case-by-case basis (IV, C).

## RESEARCH QUESTIONS AND PERSPECTIVES

The international development group has identified a need for research in some areas of the diagnosis and therapy of uterine sarcomas. Listed here are those issues that directly affect the



guideline itself or topics discussed in the guidelines. Research support could be generated when addressing such questions to answer by (randomized) clinical trials or well-planned registry data:

1. The guideline group strongly advocates studies to pre-operatively separate LMS from fibroids. Imaging methods (ultrasound, pelvic MRI, Ki-based tissue characterization) must be prospectively evaluated. Given the fact that fibroid is a mass disease in women, MRI sequences should be developed that could be disseminated widely to radiologists and not kept at highly specialized centers. The diagnostic accuracy of in-organ or transcuteaneous or transuterine biopsies in cases with suspicious imaging features should also be evaluated, including the inherent risks of complications and tumor cell dissemination.
2. In stage I LMS, adjuvant chemotherapy is not a standard of care due to the lack of evidence to indicate a survival benefit. However, this issue remains an open question due to limitations with previous trials. Thus, the initiation of new studies and recruitment of patients is absolutely recommended. At clinicaltrials.gov (search as of May 18, 2024) there is just one trial open (phase II Cytoreductive Surgery and Hyperthermic Intraperitoneal Chemotherapy With Gemcitabine Followed by Systemic Adjuvant Chemotherapy With Dacarbazine for Locally Recurrent Uterine Leiomyosarcoma, NCT04727242).
3. In the case of morcellation of uterine LG-ESS, it remains unclear whether it is advantageous to start endocrine therapy immediately after surgery (not really 'adjuvant') or delay treatment until detection and proof of recurrence (potentially palliative). There are also no data providing evidence on how long adjuvant treatment should continue. The BFR-ESS study (NCT03624244) evaluates the impact of interruption versus maintenance of aromatase inhibitors in patients with advanced or metastatic LG-ESS after at least 3 years of therapy.<sup>212</sup> Further studies on these questions are warranted.
4. The approach to systemic treatment after morcellation must be seen differently for the sarcoma subtypes. In adenosarcoma, the decisive question is whether there is a low-grade sarcomatous component or a high-grade component with sarcomatous overgrowth. It is of major impact on potential treatment (endocrine vs chemotherapy) and a reference pathology approach with recording of the cases is crucial for therapeutic progress.
5. In pre-menopausal women with hormone-sensitive sarcoma (mainly LG-ESS), the question regarding bilateral oophorectomy deserves to be addressed. A prospective documentation of oncological outcome and maintenance of quality of life (including aspects of fear of recurrence vs hormonal comfort) should include aspects of shared decision-making, patient's choice, ethnical and cultural issues.
6. As the international development group realizes that conventional chemotherapy is not working so well in uterine sarcoma, exploring the field of targetable therapies and molecular drivers is encouraged. HG-ESS harboring *BCOR* or *YWHAE-NUTM2* gene fusions resulting in recurrent *CDKN2A* alterations could be explored for a potential therapeutic use.<sup>213</sup>
7. There is a need for a long-term follow-up in women after pelvic radiation therapy to monitor the development of complications of radiation to the small bowel, bladder mucosa, rectum; neurotoxicity; and bone demineralization. In contrast to radiation-

- associated angiosarcomas after breast cancer, the latency period for secondary malignancies here is often more than 10 years.
8. In the absence of trials, the use of data from prospective registries is encouraged to obtain better knowledge, particularly of rare uterine sarcoma subentities. Such registries need to define endpoints at their start and could provide an alternative to randomization (eg, propensity score matching) including the consideration of possible confounders. They need to make sure that observations start at comparable time (intention-to-treat-principle to avoid immortal bias).<sup>214</sup>
  9. Real-world evidence (RWE) should not be categorically disregarded, but the international development group needs to acknowledge that there are actionable RWE and erroneous RWE.<sup>215</sup> Studies based on routine practice data must not be the 'light' variant of high-quality clinical trials standards, and standards of governance are more often met than those relating to data quality.<sup>216</sup>

#### Author affiliations

<sup>1</sup>Department of Medical Oncology, Centre Leon Berard, Lyon, France

<sup>2</sup>Hesper Laboratory, Université Claude Bernard Lyon 1, Villeurbanne, France

<sup>3</sup>Medical Oncology Unit 2, Fondazione IRCCS Istituto Nazionale dei Tumori, Milano, Italy

<sup>4</sup>Department of Oncology and Hemato-oncology, University of Milan, Milan, Italy

<sup>5</sup>Department of Biopathology, Institut Bergonié, Bordeaux, France

<sup>6</sup>Department of Radiology, Brigham and Women's Hospital, Boston, Massachusetts, USA

<sup>7</sup>Harvard Medical School, Boston, Massachusetts, USA

<sup>8</sup>Department of Gynecology, Obstetrics and Neonatology, First Faculty of Medicine, Charles University and General University Hospital in Prague, Prague 2, Czech Republic

<sup>9</sup>Royal Marsden Hospital NHS Trust, London, UK

<sup>10</sup>Department of Medical Oncology, Fondazione IRCCS Istituto Nazionale dei Tumori, Milan, Italy

<sup>11</sup>Gynecologic Oncology Unit, La Paz University Hospital, Madrid, Spain

<sup>12</sup>Department of Oncology, KU Leuven, Leuven, Flanders, Belgium

<sup>13</sup>Department of Gynecology, Antoni van Leeuwenhoek Nederlands Kanker Instituut afdeling Gynaecologie, Amsterdam, Netherlands

<sup>14</sup>Department of Medical Oncology, Fundación Jimenez Diaz University Hospital, Madrid, Spain

<sup>15</sup>University Hospital General de Villalba, Madrid, Spain

<sup>16</sup>Department of Medical Oncology, University Hospital San Carlos, Madrid, Spain

<sup>17</sup>Department of Pathology and Laboratory Medicine, Memorial Sloan Kettering Cancer Center, New York, New York, USA

<sup>18</sup>Department of Integrated Diagnostics, Azienda Ospedale-Università Padova, Padua, Italy

<sup>19</sup>Department of Medicine, University of Padua, Padua, Italy

<sup>20</sup>Department of Radiotherapy, Netherlands Cancer Institute, Amsterdam, Netherlands

<sup>21</sup>Department of Radiotherapy, Leiden University Medical Center, Leiden, Netherlands

<sup>22</sup>Department of Medicine, Memorial Sloan Kettering Cancer Center, New York, New York, USA

<sup>23</sup>Department of Medicine, Weill Cornell Medical College, New York, New York, USA

<sup>24</sup>Division of Surgical Oncology and Thoracic Surgery, Mannheim University Medical Centre, University of Heidelberg, Mannheim, Germany

<sup>25</sup>Department of Obstetrics and Gynecology, Seoul National University College of Medicine, Seoul, Korea (the Republic of)

<sup>26</sup>Department of Gynecological Oncology, Medical Point Hospital, Gaziantep, Turkey

<sup>27</sup>Department of Medical Oncology, Institut Gustave-Roussy, Villejuif, Île-de-France, France

<sup>28</sup>Division of Medical Oncology and Hematology, Princess Margaret Hospital Cancer Centre Gynecologic Site Group, Toronto, Ontario, Canada

<sup>29</sup>Department of Medicine, University of Toronto, Toronto, Ontario, Canada

<sup>30</sup>Department of Gynecology with Center for Oncological Surgery, Charité Universitätsmedizin Berlin, Berlin, Germany

## Society statement

<sup>31</sup>Department of Surgery, Netherlands Cancer Institute, Amsterdam, Netherlands

<sup>32</sup>Institut Bergonié, Bordeaux, France

<sup>33</sup>Department of Medical Oncology, School of Clinical Medicine, Faculty of Medicine and Health, Sydney, New South Wales, Australia

<sup>34</sup>Department of Medical Oncology, Prince of Wales and Royal Hospital for Women, Randwick, New South Wales, Australia

**Acknowledgements** The authors thank ESGO, EURACAN, and GCIG for their support. The authors also thank the 104 international reviewers (see Appendix 2) for their valuable comments and suggestions. ESGO office, especially Kamila Macku, provided invaluable logistical and administrative support throughout the process.

**Contributors** The development group (including all authors) is collectively responsible for the decision to submit for publication. Isabelle Ray-Coquard (chair), Paolo Casali (chair), Michael Friedlander (chair) and François Planchamp (methodologist) have written the first draft of the manuscript. All other contributors have actively given personal input, reviewed the manuscript, and have given final approval before submission.

**Funding** All costs relating to the development process were covered from ESGO, EURACAN, and GCIG funds. There was no external funding of the development process or manuscript production.

**Competing interests** IR-C has reported advisory boards for Abbvie, Aenus, Advaxis, Blueprint, BMS, ESAI, Daiichi Sankyo, PharmaMar, Genmab, Pfizer, AstraZeneca, Roche/Genentech, GSK, MSD, Deciphera, Mersana, Merck Sereno, Macrogenics, Novartis, Amgen, Tesaro and Clovis, and grants for traveling from Roche, MSD, AstraZeneca, Chugai and GSK; PG-C has reported Institution research grants from Advenchen Laboratories, Amgen Dompé, AROG Pharmaceuticals, Bayer, Blueprint Medicines, Boehringer Ingelheim, Daiichi Sankyo, Deciphera, Eisai, Eli Lilly, Epizyme Inc, Foghorn Ther Inc, Glaxo, Hutchinson MediPharm Lt, Inhibrx Inc, Karyopharm Pharmaceuticals, PTC Ther, Novartis, Pfizer, PharmaMar, Rain Oncology, and SpringWorks Ther; RJ has reported advisory boards for Adaptimmune, Astex, Athenex, Bayer, Borhringer Ingelheim, Blueprint, Clinigen, Eisai, Epizyme, Daiichi, Deciphera, Immunodesign, Immunicum, Karma Oncology, Lilly, Merck, Mundipharma, PharmaMar, Springworks, SynOx, Tracon, and UpTo Date; RS has reported grants for traveling from ParmaMar; FA has reported advisory boards for MiMark; J-YB has reported advisory boards for Deciphera, Bayer and Roche, and grants for traveling from OSE Pharma (unrelated); JM-B has reported advisory boards for Asofarma, Tecnofarma, FarmaMar, GSK, Novartis, Amgen, Bayer, Roche, Lilly and Boehringer Ingelheim, and grants for traveling from PharmaMar; AC has reported advisory boards for AstraZeneca and Eisai, and grants for traveling from PharmaMar, Merck and AstraZeneca; APDT has reported advisory boards for GSK, Boehringer and Novartis Oncology, and grants for traveling from PharmaMar; MLH has reported advisory boards for Aadi; PH has reported advisory boards for Boehringer Ingelheim and PharmaMar, and grants for traveling from Boehringer Ingelheim, PharmaMar, and Lighthouse PTC; PP has reported advisory boards for PharmaMar and MSD, and grants for traveling from Amgen, PharmaMar, AstraZeneca, and MSD; ARAR has reported research support (institutional) from 23&Me, Abbisko, AbbVie, Adaptimmune, Amgen, AstraZeneca, Bayer, Biontech, Blueprint Medicine, Boehringer Ingelheim, Bristol Myers Squibb, Cogent Biosciences, Daiichi Sankyo, Deciphera, Frontier Biopharma, Gilead, GSK, Iterion Therapeutics, Karyopharm Therapeutics, MedImmune, Medison, Merck, Neoleukin, Novartis, Pfizer, Polaris, Roche/Genentech, Rain Therapeutics, and Symphogen, expert testimony/advisory boards for Boehringer Ingelheim and Medison, DSMB (self) for Inhibrx, and honorarium (self) from *Journal of Clinical Oncology*, Medison and UpToDate; JS has reported advisory boards for AstraZeneca, Eisai, MSD, GSK, Novocure, Intuitive Surgical Deutschland GmbH, Seagan, Bayer Vital, GmbH, Mundipharma GmbH, PharmaMar, Sanofi-Aventis Deutschland GmbH, Immunogen, Tubulis GmbH, and Daiichi Sankyo, and grants for traveling from AstraZeneca, Eisai, MSD, GSK, Novocure, Intuitive Surgical Deutschland GmbH, Seagan, Bayer Vital, GmbH, Mundipharma GmbH; PharmaMar, Sanofi-Aventis Deutschland GmbH, Immunogen, Tubulis GmbH, Daiichi Sankyo; WvH has reported advisory boards for Sanofi, Belpharma, Boehringer Ingelheim, MSD, and Novartis, and grants for traveling from Sanofi; MF has reported consulting fees from AstraZeneca, Novartis, GSK, and Incyclix, payment for honoraria for lectures, presentations, speakers bureaus, manuscript writing or educational events from AstraZeneca, GSK, MSD, and Limbic, participation on a data safety monitoring board or advisory board for AGITG IDSMB, and ENDO-3, and research grants (institution) from AstraZeneca, Beigene and Novartis; SCr, FMF, DF, IZ, Sch, RH, J-WK, SIK, MMM, and FP have reported no conflicts of interest.

**Patient consent for publication** Not applicable.

**Ethics approval** Not applicable.

**Provenance and peer review** Not commissioned; internally peer reviewed.

**Supplemental material** This content has been supplied by the author(s). It has not been vetted by BMJ Publishing Group Limited (BMJ) and may not have been peer-reviewed. Any opinions or recommendations discussed are solely those of the author(s) and are not endorsed by BMJ. BMJ disclaims all liability and responsibility arising from any reliance placed on the content. Where the content includes any translated material, BMJ does not warrant the accuracy and reliability of the translations (including but not limited to local regulations, clinical guidelines, terminology, drug names and drug dosages), and is not responsible for any error and/or omissions arising from translation and adaptation or otherwise.

**Open access** This is an open access article distributed in accordance with the Creative Commons Attribution Non Commercial (CC BY-NC 4.0) license, which permits others to distribute, remix, adapt, build upon this work non-commercially, and license their derivative works on different terms, provided the original work is properly cited, an indication of whether changes were made, and the use is non-commercial. See: <http://creativecommons.org/licenses/by-nc/4.0/>.

### ORCID iDs

Isabelle Ray-Coquard <http://orcid.org/0000-0003-2472-8306>

Daniela Fischerova <http://orcid.org/0000-0002-7224-3218>

Ignacio Zapardiel <http://orcid.org/0000-0002-9175-7767>

Frédéric Amant <http://orcid.org/0000-0002-5452-4905>

Sarah Chiang <http://orcid.org/0000-0001-9698-0936>

Mehmet Mutlu Meydanli <http://orcid.org/0000-0001-6763-9720>

Jalid Sehoul <http://orcid.org/0000-0002-5963-6623>

François Planchamp <http://orcid.org/0000-0002-8709-0410>

### REFERENCES

- 1 world health organization. *WHO Classification of Tumours, Female Genital Tumours*. 5th edn. 4. Lyon: Internal Agency for Research on Cancer (IARC), 2020.
- 2 He X, Dong Q, Weng C, *et al*. Trends in incidence, survival and initial treatments of gynecological sarcoma: a retrospective analysis of the United States subpopulation. *BMC Womens Health* 2023;23:10.
- 3 Hensley ML, Barrette BA, Baumann K, *et al*. Gynecologic Cancer InterGroup (GCIG) consensus review: uterine and ovarian leiomyosarcomas. *Int J Gynecol Cancer* 2014;24:S61–6.
- 4 Amant F, Floquet A, Friedlander M, *et al*. Gynecologic Cancer InterGroup (GCIG) consensus review for endometrial stromal sarcoma. *Int J Gynecol Cancer* 2014;24:S67–72.
- 5 Pautier P, Nam EJ, Provencher DM, *et al*. Gynecologic Cancer InterGroup (GCIG) consensus review for high-grade undifferentiated sarcomas of the uterus. *Int J Gynecol Cancer* 2014;24:S73–7.
- 6 Friedlander ML, Covens A, Glasspool RM, *et al*. Gynecologic Cancer InterGroup (GCIG) consensus review for Mullerian adenosarcoma of the female genital tract. *Int J Gynecol Cancer* 2014;24:S78–82.
- 7 Dykewicz CA, Centers for Disease Control and Prevention (U.S.), Infectious Diseases Society of America, *et al*. Summary of the guidelines for preventing opportunistic infections among hematopoietic stem cell transplant recipients. *Clin Infect Dis* 2001;33:139–44.
- 8 Gross PA, Barrett TL, Dellinger EP, *et al*. Purpose of quality standards for infectious diseases. Infectious Diseases Society of America. *Clin Infect Dis* 1994;18:421.
- 9 Thway K, Fisher C. Histopathological diagnostic discrepancies in soft tissue tumours referred to a specialist centre. *Sarcoma* 2009;2009:741975.
- 10 Ray-Coquard I, Montesco MC, Coindre JM, *et al*. Sarcoma: concordance between initial diagnosis and centralized expert review in a population-based study within three European regions. *Ann Oncol* 2012;23:2442–9.
- 11 Rupani A, Hallin M, Jones RL, *et al*. Diagnostic differences in expert second-opinion consultation cases at a tertiary sarcoma center. *Sarcoma* 2020;2020:9810170.
- 12 Nucci MR, Webster F, Croce S, *et al*. Data set for reporting of uterine malignant and potentially malignant mesenchymal tumors: recommendations from the International Collaboration on Cancer Reporting (ICCR). *Int J Gynecol Pathol* 2022;41:S44–63.
- 13 George S, Barysaukas C, Serrano C, *et al*. Retrospective cohort study evaluating the impact of intraperitoneal morcellation on outcomes of localized uterine leiomyosarcoma. *Cancer* 2014;120:3154–8.

- 14 Halaska MJ, Haidopoulos D, Guyon F, *et al.* European Society of Gynecological Oncology statement on fibroid and uterine morcellation. *Int J Gynecol Cancer* 2017;27:189–92.
- 15 Demetri GD, Antonescu CR, Bjerkehaugen B, *et al.* Diagnosis and management of tropomyosin receptor kinase (TRK) fusion sarcomas: expert recommendations from the World Sarcoma Network. *Ann Oncol* 2020;31:1506–17.
- 16 Butrynski JE, D'Adamo DR, Hornick JL, *et al.* Crizotinib in ALK-rearranged inflammatory myofibroblastic tumor. *N Engl J Med* 2010;363:1727–33.
- 17 Villaruz LC, Socinski MA, Weiss J. Guidance for clinicians and patients with non-small cell lung cancer in the time of precision medicine. *Front Oncol* 2023;13:1124167.
- 18 Selenica P, Conlon N, Gonzalez C, *et al.* Genomic profiling aids classification of diagnostically challenging uterine mesenchymal tumors with myxoid differentiation. *Am J Surg Pathol* 2021;45:77–92.
- 19 Croce S, Chibon F. Molecular prognostication of uterine smooth muscle neoplasms: from CGH array to CINSARC signature and beyond. *Genes Chromosomes Cancer* 2021;60:129–37.
- 20 Croce S, Ducoulombier A, Ribeiro A, *et al.* Genome profiling is an efficient tool to avoid the STUMP classification of uterine smooth muscle lesions: a comprehensive array-genomic hybridization analysis of 77 tumors. *Mod Pathol* 2018;31:816–28.
- 21 Smadja J, El Zein S, Pierron G, *et al.* Percutaneous uterine needle biopsy with microscopic and array-CGH analyses for preoperative sarcoma diagnosis in patients with suspicious myometrial tumors on MRI: a prospective pilot study (SARCGYN). *Ann Surg Oncol* 2023;30:943–53.
- 22 Fontanges Q, Dubos P, Lesluyes T, *et al.* Genomic profile analysis of leiomyomas with bizarre nuclei and fumarate hydratase deficient leiomyomas: strengths, weaknesses, and limitations of array-CGH interpretation. *Genes Chromosomes Cancer* 2024;63:e23229.
- 23 Nomura Y, Tamura D, Horie M, *et al.* Detection of MEAF6-PHF1 translocation in an endometrial stromal nodule. *Genes Chromosomes Cancer* 2020.
- 24 Kertowidjojo EC, Bennett JA. Update on uterine mesenchymal neoplasms. *Surg Pathol Clin* 2022;15:315–40.
- 25 Zou Y, Turashvili G, Soslow RA, *et al.* High-grade transformation of low-grade endometrial stromal sarcomas lacking YWHAE and BCOR genetic abnormalities. *Mod Pathol* 2020;33:1861–70.
- 26 Chiang S, Vasudevaraja V, Serrano J, *et al.* TSC2-mutant uterine sarcomas with JAZF1-SUZ12 fusions demonstrate hybrid features of endometrial stromal sarcoma and PEComa and are responsive to mTOR inhibition. *Mod Pathol* 2022;35:117–27.
- 27 Dessources K, Miller KM, Kertowidjojo E, *et al.* ESR1 hotspot mutations in endometrial stromal sarcoma with high-grade transformation and endocrine treatment. *Mod Pathol* 2022;35:972–8.
- 28 Devins KM, Attygalle AD, Croce S, *et al.* Uterine endometrial stromal tumors with pure low-grade morphology harboring YWHAE::NUTM2 fusions: report of a case series emphasizing potential for high-grade transformation and aggressive behavior. *Am J Surg Pathol* 2023;47:717–24.
- 29 Lewis N, Soslow RA, Delair DF, *et al.* ZC3H7B-BCOR high-grade endometrial stromal sarcomas: a report of 17 cases of a newly defined entity. *Mod Pathol* 2018;31:674–84.
- 30 Lee C-H, Ou W-B, Mariño-Enriquez A, *et al.* 14-3-3 fusion oncogenes in high-grade endometrial stromal sarcoma. *Proc Natl Acad Sci U S A* 2012;109:929–34.
- 31 Lee C-H, Mariño-Enriquez A, Ou W, *et al.* The clinicopathologic features of YWHAE-FAM22 endometrial stromal sarcomas: a histologically high-grade and clinically aggressive tumor. *Am J Surg Pathol* 2012;36:641–53.
- 32 Lin DI, Huang RSP, Mata DA, *et al.* Clinicopathological and genomic characterization of BCORL1-driven high-grade endometrial stromal sarcomas. *Mod Pathol* 2021;34:2200–10.
- 33 Mariño-Enriquez A, Lauria A, Przybyl J, *et al.* BCOR internal tandem duplication in high-grade uterine sarcomas. *Am J Surg Pathol* 2018;42:335–41.
- 34 Kurihara S, Oda Y, Ohishi Y, *et al.* Endometrial stromal sarcomas and related high-grade sarcomas: immunohistochemical and molecular genetic study of 31 cases. *Am J Surg Pathol* 2008;32:1228–38.
- 35 Cotzia P, Benayed R, Mullaney K, *et al.* Undifferentiated uterine sarcomas represent under-recognized high-grade endometrial stromal sarcomas. *Am J Surg Pathol* 2019;43:662–9.
- 36 Momeni-Boroujeni A, Mohammad N, Wolber R, *et al.* Targeted RNA expression profiling identifies high-grade endometrial stromal sarcoma as a clinically relevant molecular subtype of uterine sarcoma. *Mod Pathol* 2021;34:1008–16.
- 37 Parra-Herran C, Howitt BE. Uterine mesenchymal tumors: update on classification, staging, and molecular features. *Surg Pathol Clin* 2019;12:363–96.
- 38 Hasegawa C, Washimi K, Hiroshima Y, *et al.* Differential diagnosis of uterine adenosarcoma: identification of JAZF1-BCORL1 rearrangement by comprehensive cancer genomic profiling. *Diagn Pathol* 2023;18:5.
- 39 Howitt BE, Sholl LM, Dal Cin P, *et al.* Targeted genomic analysis of Müllerian adenosarcoma. *J Pathol* 2015;235:37–49.
- 40 Nacev BA, Sanchez-Vega F, Smith SA, *et al.* Clinical sequencing of soft tissue and bone sarcomas delineates diverse genomic landscapes and potential therapeutic targets. *Nat Commun* 2022;13:3405.
- 41 Bennett JA, Ordulu Z, Pinto A, *et al.* Uterine PEComas: correlation between melanocytic marker expression and TSC alterations/TFE3 fusions. *Mod Pathol* 2022;35:515–23.
- 42 Bennett JA, Braga AC, Pinto A, *et al.* Uterine PEComas: a morphologic, immunohistochemical, and molecular analysis of 32 tumors. *Am J Surg Pathol* 2018;42:1370–83.
- 43 Schoolmeester JK, Howitt BE, Hirsch MS, *et al.* Perivascular epithelioid cell neoplasm (PEComa) of the gynecologic tract: clinicopathologic and immunohistochemical characterization of 16 cases. *Am J Surg Pathol* 2014;38:176–88.
- 44 Schoolmeester JK, Dao LN, Sukov WR, *et al.* TFE3 translocation-associated perivascular epithelioid cell neoplasm (PEComa) of the gynecologic tract: morphology, immunophenotype, differential diagnosis. *Am J Surg Pathol* 2015;39:394–404.
- 45 Argani P, Aulmann S, Illei PB, *et al.* A distinctive subset of PEComas harbors TFE3 gene fusions. *Am J Surg Pathol* 2010;34:1395–406.
- 46 Agaram NP, Sung Y-S, Zhang L, *et al.* Dichotomy of genetic abnormalities in PEComas with therapeutic implications. *Am J Surg Pathol* 2015;39:813–25.
- 47 Chiang S, Cotzia P, Hyman DM, *et al.* NTRK fusions define a novel uterine sarcoma subtype with features of fibrosarcoma. *Am J Surg Pathol* 2018;42:791–8.
- 48 Chiang S. S100 and Pan-Trk staining to report NTRK fusion-positive uterine sarcoma: proceedings of the ISGYP Companion Society Session at the 2020 USCAP Annual Meeting. *Int J Gynecol Pathol* 2021;40:24–7.
- 49 Moura MS, Costa J, Velasco V, *et al.* Pan-TRK immunohistochemistry in gynaecological mesenchymal tumours: diagnostic implications and pitfalls. *Histopathology* 2024;84:451–62.
- 50 Croce S, Hostein I, Longacre TA, *et al.* Uterine and vaginal sarcomas resembling fibrosarcoma: a clinicopathological and molecular analysis of 13 cases showing common NTRK-rearrangements and the description of a COL1A1-PDGFβ fusion novel to uterine neoplasms. *Mod Pathol* 2019;32:1008–22.
- 51 Croce S, Hostein I, McCluggage WG. NTRK and other recently described kinase fusion positive uterine sarcomas: a review of a group of rare neoplasms. *Genes Chromosomes Cancer* 2021;60:147–59.
- 52 Costigan DC, Nucci MR, Dickson BC, *et al.* NTRK-rearranged uterine sarcomas: clinicopathologic features of 15 cases, literature review, and risk stratification. *Am J Surg Pathol* 2022;46:1415–29.
- 53 Chan JK, Kawar NM, Shin JY, *et al.* Endometrial stromal sarcoma: a population-based analysis. *Br J Cancer* 2008;99:1210–5.
- 54 Ludovisi M, Moro F, Pasciuto T, *et al.* Imaging in gynecological disease (15): clinical and ultrasound characteristics of uterine sarcoma. *Ultrasound Obstet Gynecol* 2019;54:676–87.
- 55 Ciccarone F, Pasciuto T, Robba E. EP34.20: Diagnostic algorithm for uterine sarcoma identification: a one-year interim analysis of a monocentric prospective, observational cohort study abstract of the 29th World Congress on Ultrasound in Obstetrics and Gynecology, 12–16 October 2019, Berlin, Germany. *Ultrasound Obstet Gynecol* 2019;54:446.
- 56 Minimum training recommendations for the practice of medical ultrasound. *Ultraschall Med* 2006;27:79–105.
- 57 Jagannathan JP, Steiner A, Bay C, *et al.* Differentiating leiomyosarcoma from leiomyoma: in support of an MR imaging predictive scoring system. *Abdom Radiol* 2021;46:4927–35.
- 58 Hindman N, Kang S, Fournier L, *et al.* MRI evaluation of uterine masses for risk of leiomyosarcoma: a consensus statement. *Radiology* 2023;306:e211658.
- 59 Sun S, Bonaffini PA, Nougaret S, *et al.* How to differentiate uterine leiomyosarcoma from leiomyoma with imaging. *Diagn Interv Imaging* 2019;100:619–34.
- 60 Stukan M, Rutkowski P, Smadja J, *et al.* Ultrasound-guided trans-uterine cavity core needle biopsy of uterine myometrial tumors to differentiate sarcoma from a benign lesion—description of the method and review of the literature. *Diagn (Basel)* 2022;12:1348.

## Society statement

- 61 Tamura R, Kashima K, Asatani M, *et al.* Preoperative ultrasound-guided needle biopsy of 63 uterine tumors having high signal intensity upon T2-weighted magnetic resonance imaging. *Int J Gynecol Cancer* 2014;24:1042–7.
- 62 Cancer Genome Atlas Research Network. Electronic address, e.d.s.c. & Cancer Genome Atlas Research, N. Comprehensive and integrated genomic characterization of adult soft tissue sarcomas. *Cell* 2017;171:e928:950–65.
- 63 Berger-Richardson D, Swallow CJ. Needle tract seeding after percutaneous biopsy of sarcoma: risk/benefit considerations. *Cancer* 2017;123:560–7.
- 64 Cui RR, Wright JD, Hou JY. Uterine leiomyosarcoma: a review of recent advances in molecular biology, clinical management and outcome. *BJOG* 2017;124:1028–37.
- 65 Bretthauer M, Goderstad JM, Løberg M, *et al.* Uterine morcellation and survival in uterine sarcoma. *Eur J Cancer* 2018;101:62–8.
- 66 Pritts EA, Parker WH, Brown J, *et al.* Outcome of occult uterine leiomyosarcoma after surgery for presumed uterine fibroids: a systematic review. *J Minim Invasive Gynecol* 2015;22:26–33.
- 67 Tamura D, Maeda D, Enomoto K, *et al.* Severe abdominal recurrence of low-grade endometrial stromal sarcoma after hysteroscopic surgery. *Anticancer Res* 2021;41:4013–6.
- 68 Kapp DS, Shin JY, Chan JK. Prognostic factors and survival in 1396 patients with uterine leiomyosarcomas: emphasis on impact of lymphadenectomy and oophorectomy. *Cancer* 2008;112:820–30.
- 69 Perri T, Korach J, Sadetzki S, *et al.* Uterine leiomyosarcoma: does the primary surgical procedure matter? *Int J Gynecol Cancer* 2009;19:257–60.
- 70 Park J-Y, Park S-K, Kim D-Y, *et al.* The impact of tumor morcellation during surgery on the prognosis of patients with apparently early uterine leiomyosarcoma. *Gynecol Oncol* 2011;122:255–9.
- 71 Roser E, Harter P, Zocholl D, *et al.* Treatment strategies in patients with gynecological sarcoma: results of the prospective intergroup real-world registry for gynecological sarcoma in Germany (REGSA-NOGGO RU1). *Int J Gynecol Cancer* 2023;33:223–30.
- 72 Bogani G, Chiappa V, Ditto A, *et al.* Morcellation of undiagnosed uterine sarcoma: a critical review. *Crit Rev Oncol Hematol* 2016;98:302–8.
- 73 Cao H, Li L, Yang B, *et al.* Unexpected uterine sarcomas after hysterectomy and myomectomy for presumed leiomyoma: a retrospective study of 26,643 patients. *Cancer Manag Res* 2019;11:7007–14.
- 74 Ebner F, Wiedenmann S, Bekes I, *et al.* Results of an internal audit on the survival of patients with uterine sarcoma. *J Turk Ger Gynecol Assoc* 2019;20:15–22.
- 75 Cohen SL, Hariton E, Afshar Y, *et al.* Updates in uterine fibroid tissue extraction. *Curr Opin Obstet Gynecol* 2016;28:277–82.
- 76 Condic M, Egger EK, Hohenberger P, *et al.* Clinical value of pre-operative scoring systems to predict leiomyosarcoma: results of a validation study in 177 patients from the NOGGO-REGSA Registry. *Int J Gynecol Cancer* 2022;32:619–25.
- 77 Wysowski DK, Honig SF, Beitz J. Uterine sarcoma associated with tamoxifen use. *N Engl J Med* 2002;346:1832–3.
- 78 Seki K, Hoshihara T, Nagata I. Leiomyosarcoma of the uterus: ultrasonography and serum lactate dehydrogenase level. *Gynecol Obstet Invest* 1992;33:114–8.
- 79 Amant F, Coosemans A, Debiec-Rychter M, *et al.* Clinical management of uterine sarcomas. *Lancet Oncol* 2009;10:1188–98.
- 80 Garg G, Shah JP, Liu JR, *et al.* Validation of tumor size as staging variable in the revised International Federation of Gynecology and Obstetrics stage I leiomyosarcoma: a population-based study. *Int J Gynecol Cancer* 2010;20:1201–6.
- 81 Beck TL, Singhal PK, Ehrenberg HM, *et al.* Endometrial stromal sarcoma: analysis of recurrence following adjuvant treatment. *Gynecol Oncol* 2012;125:141–4.
- 82 Bai H, Yang J, Cao D, *et al.* Ovary and uterus-sparing procedures for low-grade endometrial stromal sarcoma: a retrospective study of 153 cases. *Gynecol Oncol* 2014;132:654–60.
- 83 Shah JP, Bryant CS, Kumar S, *et al.* Lymphadenectomy and ovarian preservation in low-grade endometrial stromal sarcoma. *Obstet Gynecol* 2008;112:1102–8.
- 84 Yoon A, Park J-Y, Park J-Y, *et al.* Prognostic factors and outcomes in endometrial stromal sarcoma with the 2009 FIGO staging system: a multicenter review of 114 cases. *Gynecol Oncol* 2014;132:70–5.
- 85 Leitao MM, Sonoda Y, Brennan MF, *et al.* Incidence of lymph node and ovarian metastases in leiomyosarcoma of the uterus. *Gynecol Oncol* 2003;91:209–12.
- 86 Barney B, Tward JD, Skidmore T, *et al.* Does radiotherapy or lymphadenectomy improve survival in endometrial stromal sarcoma? *Int J Gynecol Cancer* 2009;19:1232–8.
- 87 Nasioudis D, Mastroyannis SA, Latif NA, *et al.* Role of lymphadenectomy for apparent early stage uterine sarcoma; a comprehensive analysis of the National Cancer Database. *Surg Oncol* 2021;38:101589.
- 88 Zhang Y, Li N, Wang W, *et al.* Long-term impact of lymphadenectomies in patients with low-grade, early-stage uterine endometrial stroma sarcoma. *J Obstet Gynaecol Res* 2020;46:654–62.
- 89 Si M, Jia L, Song K, *et al.* Role of lymphadenectomy for uterine sarcoma: a meta-analysis. *Int J Gynecol Cancer* 2017;27:109–16.
- 90 Dafopoulos A, Tsikouras P, Dimitraki M, *et al.* The role of lymphadenectomy in uterine leiomyosarcoma: review of the literature and recommendations for the standard surgical procedure. *Arch Gynecol Obstet* 2010;282:293–300.
- 91 Coronado PJ, Alonso-Espias M, Yildirim Y, *et al.* Lymph node dissection in uterine leiomyosarcomas: a matched-pair study. *Gynecol Oncol* 2023;174:28–33.
- 92 Zapardiel I, Morrow CP. New terminology for cytoreduction in advanced ovarian cancer. *Lancet Oncol* 2011;12:214.
- 93 Zapardiel I, Gracia Segovia M, Macuks R, *et al.* Prognostic factors in patients with uterine sarcoma: the SARCUT study. *Int J Gynecol Cancer* 2023;33:897–904.
- 94 Guckenberger M, Lievens Y, Bouma AB, *et al.* Characterisation and classification of oligometastatic disease: a European Society for Radiotherapy and Oncology and European Organisation for Research and Treatment of Cancer consensus recommendation. *Lancet Oncol* 2020;21:e18–28.
- 95 Collineau B, Genestie C, Croce S, *et al.* Léiomyosarcomes utérins–Référentiel de prise en charge du GSF-GETO/NETSARC+ et du groupe TMRG. *Bull Cancer* 2023;110:440–9.
- 96 Palma DA, Olson R, Harrow S, *et al.* Stereotactic ablative radiotherapy for the comprehensive treatment of oligometastatic cancers: long-term results of the SABR-COMET phase II randomized trial. *J Clin Oncol* 2020;38:2830–8.
- 97 Matsuzaki S, Matsuzaki S, Chang EJ, *et al.* Surgical and oncologic outcomes of hyperthermic intraperitoneal chemotherapy for uterine leiomyosarcoma: a systematic review of literature. *Gynecol Oncol* 2021;161:70–7.
- 98 Goff BA, Rice LW, Fleischhacker D, *et al.* Uterine leiomyosarcoma and endometrial stromal sarcoma: lymph node metastases and sites of recurrence. *Gynecol Oncol* 1993;50:105–9.
- 99 Tasci T, Karalok A, Taskin S, *et al.* Does lymphadenectomy improve survival in uterine leiomyosarcoma? *Int J Gynecol Cancer* 2015;25:1031–6.
- 100 Yamazaki H, Todo Y, Mitsube K, *et al.* Long-term survival of patients with recurrent endometrial stromal sarcoma: a multicenter, observational study. *J Gynecol Oncol* 2015;26:214–21.
- 101 Gadducci A, Multinu F, De Vitis LA, *et al.* Endometrial stromal tumors of the uterus: epidemiology, pathological and biological features, treatment options and clinical outcomes. *Gynecol Oncol* 2023;171:95–105.
- 102 Ayhan A, Toptas T, Oz M, *et al.* Low-grade endometrial stromal sarcoma: a Turkish uterine sarcoma group study analyzing prognostic factors and disease outcomes. *Gynecol Oncol* 2021;160:674–80.
- 103 Rauh-Hain JA, del Carmen MG. Endometrial stromal sarcoma: a systematic review. *Obstet Gynecol* 2013;122:676–83.
- 104 Olivier T, Pop D, Chouiter Djebaili A, *et al.* Treating metastatic sarcomas locally: a paradox, a rationale, an evidence? *Crit Rev Oncol Hematol* 2015;95:62–77.
- 105 Cybulska P, Sioulas V, Orfanelli T, *et al.* Secondary surgical resection for patients with recurrent uterine leiomyosarcoma. *Gynecol Oncol* 2019;154:333–7.
- 106 Stamenovic D, Hohenberger P, Roessner E. Pulmonary metastasectomy in soft tissue sarcomas: a systematic review. *J Thorac Dis* 2021;13:2649–60.
- 107 Santos P, Cunha TM. Uterine sarcomas: clinical presentation and MRI features. *Diagn Interv Radiol* 2015;21:4–9.
- 108 Einstein MH, Barakat RR, Chi DS, *et al.* Management of uterine malignancy found incidentally after supracervical hysterectomy or uterine morcellation for presumed benign disease. *Int J Gynecol Cancer* 2008;18:1065–70.
- 109 Seagle B-LL, Sobocki-Rausch J, Strohl AE, *et al.* Prognosis and treatment of uterine leiomyosarcoma: a National Cancer Database study. *Gynecol Oncol* 2017;145:61–70.
- 110 Ronsini C, Foresta A, Giudice M, *et al.* Is adnexectomy mandatory at the time of hysterectomy for uterine sarcomas? A systematic review and meta-analysis. *Medicina (Kaunas)* 2022;58:1140.

- 111 Nasioudis D, Chapman-Davis E, Frey M, *et al.* Safety of ovarian preservation in premenopausal women with stage I uterine sarcoma. *J Gynecol Oncol* 2017;28:e46.
- 112 Dondi G, Porcu E, De Palma A, *et al.* Uterine preservation treatments in sarcomas: oncological problems and reproductive results: a systematic review. *Cancers (Basel)* 2021;13:5808.
- 113 Laurelli G, Falcone F, Scaffa C, *et al.* Fertility-sparing management of low-grade endometrial stromal sarcoma: analysis of an institutional series and review of the literature. *Eur J Obstet Gynecol Reprod Biol* 2015;195:61–6.
- 114 Lissoni A, Cormio G, Bonazzi C, *et al.* Fertility-sparing surgery in uterine leiomyosarcoma. *Gynecol Oncol* 1998;70:348–50.
- 115 Piątek S, Szymusik I, Dańska-Bidzińska A, *et al.* Fertility-sparing management may be considered in young women with uterine sarcoma. *J Clin Med* 2022;11:4761.
- 116 Gatta G, van der Zwan JM, Casali PG, *et al.* Rare cancers are not so rare: the rare cancer burden in Europe. *Eur J Cancer* 2011;47:2493–511.
- 117 Reed NS, Mangioni C, Malmström H, *et al.* Phase III randomised study to evaluate the role of adjuvant pelvic radiotherapy in the treatment of uterine sarcomas stages I and II: an European Organisation for Research and Treatment of Cancer Gynaecological Cancer Group Study (protocol 55874). *Eur J Cancer* 2008;44:808–18.
- 118 George S, Serrano C, Hensley ML, *et al.* Soft tissue and uterine leiomyosarcoma. *J Clin Oncol* 2018;36:144–50.
- 119 Hensley ML, Enserro D, Hatcher H, *et al.* Adjuvant gemcitabine plus docetaxel followed by doxorubicin versus observation for high-grade uterine leiomyosarcoma: a phase III NRG Oncology/Gynecologic Oncology Group Study. *J Clin Oncol* 2018;36.
- 120 Omura GA, Blessing JA, Major F, *et al.* A randomized clinical trial of adjuvant adriamycin in uterine sarcomas: a Gynecologic Oncology Group Study. *JCO* 1985;3:1240–5.
- 121 Pautier P, Floquet A, Gladieff L, *et al.* A randomized clinical trial of adjuvant chemotherapy with doxorubicin, ifosfamide, and cisplatin followed by radiotherapy versus radiotherapy alone in patients with localized uterine sarcomas (SARCGYN study). A study of the French Sarcoma Group. *Ann Oncol* 2013;24:1099–104.
- 122 Hensley ML, Ishill N, Soslow R, *et al.* Adjuvant gemcitabine plus docetaxel for completely resected stages I-IV high grade uterine leiomyosarcoma: results of a prospective study. *Gynecol Oncol* 2009;112:563–7.
- 123 Hensley ML, Wathen JK, Maki RG, *et al.* Adjuvant therapy for high-grade, uterus-limited leiomyosarcoma: results of a phase 2 trial (SARC 005). *Cancer* 2013;119:1555–61.
- 124 Littell RD, Tucker L-Y, Raine-Bennett T, *et al.* Adjuvant gemcitabine-docetaxel chemotherapy for stage I uterine leiomyosarcoma: trends and survival outcomes. *Gynecol Oncol* 2017;147:11–7.
- 125 Ricci S, Giuntoli RL, Eisenhauer E, *et al.* Does adjuvant chemotherapy improve survival for women with early-stage uterine leiomyosarcoma? *Gynecol Oncol* 2013;131:629–33.
- 126 Gronchi A, Palmerini E, Quagliuolo V, *et al.* Neoadjuvant chemotherapy in high-risk soft tissue sarcomas: final results of a randomized trial from Italian (ISG), Spanish (GEIS), French (FSG), and Polish (PSG) sarcoma groups. *J Clin Oncol* 2020;38:2178–86.
- 127 Pasquali S, Pizzamiglio S, Touati N, *et al.* The impact of chemotherapy on survival of patients with extremity and trunk wall soft tissue sarcoma: revisiting the results of the EORTC-STBSG 62931 randomised trial. *Eur J Cancer* 2019;109:51–60.
- 128 D'Ambrosio L, Touati N, Blay J-Y, *et al.* Doxorubicin plus dacarbazine, doxorubicin plus ifosfamide, or doxorubicin alone as a first-line treatment for advanced leiomyosarcoma: a propensity score matching analysis from the European Organization for Research and Treatment of Cancer Soft Tissue and Bone Sarcoma Group. *Cancer* 2020;126:2637–47.
- 129 Pautier P, Italiano A, Piperno-Neumann S, *et al.* Doxorubicin alone versus doxorubicin with trabectedin followed by trabectedin alone as first-line therapy for metastatic or unresectable leiomyosarcoma (LMS-04): a randomised, multicentre, open-label phase 3 trial. *Lancet Oncol* 2022;23:1044–54.
- 130 Pautier P, Italiano A, Piperno-Neumann S, *et al.* 19130 A randomised, multicenter phase-III study comparing doxorubicin (dox) alone versus dox with trabectedin (trab) followed by trab in non-progressive patients (pts) as first-line therapy, in pts with metastatic or unresectable leiomyosarcoma (LMS): final results of the LMS-04 study. *Ann Oncol* 2023;34.
- 131 Putnam JB, Roth JA, Wesley MN, *et al.* Analysis of prognostic factors in patients undergoing resection of pulmonary metastases from soft tissue sarcomas. *J Thorac Cardiovasc Surg* 1984;87:260–8.
- 132 Burt BM, Ocejo S, Mery CM, *et al.* Repeated and aggressive pulmonary resections for leiomyosarcoma metastases extends survival. *Ann Thorac Surg* 2011;92:1202–7.
- 133 Giuntoli RL, Garrett-Mayer E, Bristow RE, *et al.* Secondary cytoreduction in the management of recurrent uterine leiomyosarcoma. *Gynecol Oncol* 2007;106:82–8.
- 134 van Geel AN, Pastorino U, Jauch KW. Surgical treatment of lung metastases: the European Organization for Research and Treatment of Cancer-Soft Tissue and Bone Sarcoma Group study of 255 patients. *Cancer* 1996;77:675–82.
- 135 Hensley ML, Blessing JA, Degeest K, *et al.* Fixed-dose rate gemcitabine plus docetaxel as second-line therapy for metastatic uterine leiomyosarcoma: a Gynecologic Oncology Group phase II study. *Gynecol Oncol* 2008;109:323–8.
- 136 Judson I, Radford JA, Harris M, *et al.* Randomised phase II trial of pegylated liposomal doxorubicin (DOXIL/CAELYX) versus doxorubicin in the treatment of advanced or metastatic soft tissue sarcoma: a study by the EORTC Soft Tissue and Bone Sarcoma Group. *Eur J Cancer* 2001;37:870–7.
- 137 Pautier P, Floquet A, Penel N, *et al.* Randomized multicenter and stratified phase II study of gemcitabine alone versus gemcitabine and docetaxel in patients with metastatic or relapsed leiomyosarcomas: a Federation Nationale des Centres de Lutte Contre le Cancer (FNCLCC) French Sarcoma Group Study (TAXOGEM study). *Oncologist* 2012;17:1213–20.
- 138 Seddon B, Strauss SJ, Whelan J, *et al.* Gemcitabine and docetaxel versus doxorubicin as first-line treatment in previously untreated advanced unresectable or metastatic soft-tissue sarcomas (GeDDis): a randomised controlled phase 3 trial. *Lancet Oncol* 2017;18:1397–410.
- 139 Demetri GD, von Mehren M, Jones RL, *et al.* Efficacy and safety of trabectedin or dacarbazine for metastatic liposarcoma or leiomyosarcoma after failure of conventional chemotherapy: results of a phase III randomized multicenter clinical trial. *J Clin Oncol* 2016;34:786–93.
- 140 Losa R, Fra J, López-Pousa A, *et al.* Phase II study with the combination of gemcitabine and DTIC in patients with advanced soft tissue sarcomas. *Cancer Chemother Pharmacol* 2007;59:251–9.
- 141 van der Graaf WTA, Blay J-Y, Chawla SP, *et al.* Pazopanib for metastatic soft-tissue sarcoma (PALETTE): a randomised, double-blind, placebo-controlled phase 3 trial. *Lancet* 2012;379:1879–86.
- 142 Sanfilippo R, Sbaraglia M, Fabbroni C, *et al.* Low-grade uterine leiomyosarcoma is highly sensitive to hormonal treatment. *Clin Cancer Res* 2023;29:4679–84.
- 143 Felix AS, Cook LS, Gaudet MM, *et al.* The etiology of uterine sarcomas: a pooled analysis of the epidemiology of endometrial cancer consortium. *Br J Cancer* 2013;108:727–34.
- 144 D'Angelo E, Prat J. Uterine sarcomas: a review. *Gynecol Oncol* 2010;116:131–9.
- 145 Ferreira J, Félix A, Lennerz JK, *et al.* Recent advances in the histological and molecular classification of endometrial stromal neoplasms. *Virchows Arch* 2018;473:665–78.
- 146 Malouf GG, Lhommé C, Duvillard P, *et al.* Prognostic factors and outcome of undifferentiated endometrial sarcoma treated by multimodal therapy. *Int J Gynaecol Obstet* 2013;122:57–61.
- 147 Judson I, Verweij J, Gelderblom H, *et al.* Doxorubicin alone versus intensified doxorubicin plus ifosfamide for first-line treatment of advanced or metastatic soft-tissue sarcoma: a randomised controlled phase 3 trial. *Lancet Oncol* 2014;15:415–23.
- 148 Le Cesne A, Judson I, Crowther D, *et al.* Randomized phase III study comparing conventional-dose doxorubicin plus ifosfamide versus high-dose doxorubicin plus ifosfamide plus recombinant human granulocyte-macrophage colony-stimulating factor in advanced soft tissue sarcomas: a trial of the European Organization for Research and Treatment of Cancer/Soft Tissue and Bone Sarcoma Group. *J Clin Oncol* 2000;18:2676–84.
- 149 Tanner EJ, Garg K, Leitao MM, *et al.* High grade undifferentiated uterine sarcoma: surgery, treatment, and survival outcomes. *Gynecol Oncol* 2012;127:27–31.
- 150 Hao Z, Yang S. The role of postoperative radiotherapy in patients with uterine sarcomas: a PSM-IPTW analysis based on SEER database. *Front Surg* 2022;9:985654.
- 151 Abeler VM, Royne O, Thoresen S, *et al.* Uterine sarcomas in Norway. A histopathological and prognostic survey of a total population from 1970 to 2000 including 419 patients. *Histopathology* 2009;54:355–64.
- 152 Seagle B-LL, Shilpi A, Buchanan S, *et al.* Low-grade and high-grade endometrial stromal sarcoma: a National Cancer Database study. *Gynecol Oncol* 2017;146:254–62.

## Society statement

- 153 Koivisto-Korander R, Martinsen JI, Weiderpass E, *et al.* Incidence of uterine leiomyosarcoma and endometrial stromal sarcoma in Nordic countries: results from NORDCAN and NOCCA databases. *Maturitas* 2012;72:56–60.
- 154 Kennedy MM, Baigrie CF, Manek S. Tamoxifen and the endometrium: review of 102 cases and comparison with HRT-related and non-HRT-related endometrial pathology. *Int J Gynecol Pathol* 1999;18:130–7.
- 155 Prat J. FIGO staging for uterine sarcomas. *Int J Gynaecol Obstet* 2009;104:177–8.
- 156 Park J-Y, Kim D-Y, Kim J-H, *et al.* The impact of tumor morcellation during surgery on the outcomes of patients with apparently early low-grade endometrial stromal sarcoma of the uterus. *Ann Surg Oncol* 2011;18:3453–61.
- 157 Amant F, De Knijf A, Van Calster B, *et al.* Clinical study investigating the role of lymphadenectomy, surgical castration and adjuvant hormonal treatment in endometrial stromal sarcoma. *Br J Cancer* 2007;97:1194–9.
- 158 Li AJ, Giuntoli RL, Drake R, *et al.* Ovarian preservation in stage I low-grade endometrial stromal sarcomas. *Obstet Gynecol* 2005;106:1304–8.
- 159 Leath CA, Huh WK, Hyde J, *et al.* A multi-institutional review of outcomes of endometrial stromal sarcoma. *Gynecol Oncol* 2007;105:630–4.
- 160 Stewart LE, Beck TL, Giannakopoulos NV, *et al.* Impact of oophorectomy and hormone suppression in low grade endometrial stromal sarcoma: a multicenter review. *Gynecol Oncol* 2018;149:297–300.
- 161 Nasioudis D, Ko EM, Kolovos G, *et al.* Ovarian preservation for low-grade endometrial stromal sarcoma: a systematic review of the literature and meta-analysis. *Int J Gynecol Cancer* 2019;29:126–32.
- 162 Chu MC, Mor G, Lim C, *et al.* Low-grade endometrial stromal sarcoma: hormonal aspects. *Gynecol Oncol* 2003;90:170–6.
- 163 Sampath S, Gaffney DK. Role of radiotherapy treatment of uterine sarcoma. *Best Pract Res Clin Obstet Gynaecol* 2011;25:761–72.
- 164 Malouf GG, Duclos J, Rey A, *et al.* Impact of adjuvant treatment modalities on the management of patients with stages I-II endometrial stromal sarcoma. *Ann Oncol* 2010;21:2102–6.
- 165 Thomas MB, Keeney GL, Podratz KC, *et al.* Endometrial stromal sarcoma: treatment and patterns of recurrence. *Int J Gynecol Cancer* 2009;19:253–6.
- 166 Altman AD, Nelson GS, Chu P, *et al.* Uterine sarcoma and aromatase inhibitors: tom Baker Cancer Centre experience and review of the literature. *Int J Gynecol Cancer* 2012;22:1006–12.
- 167 Cheng X, Yang G, Schmeler KM, *et al.* Recurrence patterns and prognosis of endometrial stromal sarcoma and the potential of tyrosine kinase-inhibiting therapy. *Gynecol Oncol* 2011;121:323–7.
- 168 Tzakas E, Liu S, Todd RW, *et al.* Hormonal therapy with letrozole prior to surgical management of recurrent metastatic low-grade endometrial stromal sarcoma (LGESS). *J Obstet Gynaecol* 2009;29:778–9.
- 169 Burke C, Hickey K. Treatment of endometrial stromal sarcoma with a gonadotropin-releasing hormone analogue. *Obstet Gynecol* 2004;104:1182–4.
- 170 Spano J-P, Soria J-C, Kambouchner M, *et al.* Long-term survival of patients given hormonal therapy for metastatic endometrial stromal sarcoma. *Med Oncol* 2003;20:87–93.
- 171 Friedlander M, Benson C, O'Connell RL, *et al.* Phase 2 study of anastrozole in patients with estrogen receptor/progesterone receptor positive recurrent low-grade endometrial stromal sarcomas: the PARAGON trial (ANZGOG 0903). *Gynecol Oncol* 2021;161:160–5.
- 172 Ingle JN, Suman VJ, Rowland KM, *et al.* Fulvestrant in women with advanced breast cancer after progression on prior aromatase inhibitor therapy: North Central Cancer Treatment Group Trial N0032. *J Clin Oncol* 2006;24:1052–6.
- 173 Omura GA, Major FJ, Blessing JA, *et al.* A randomized study of adriamycin with and without dimethyl triazenoimidazole carboxamide in advanced uterine sarcomas. *Cancer* 1983;52:626–32.
- 174 Nathenson MJ, Ravi V, Fleming N, *et al.* Uterine adenocarcinoma: a review. *Curr Oncol Rep* 2016;18:68.
- 175 McCluggage WG. Mullerian adenocarcinoma of the female genital tract. *Adv Anat Pathol* 2010;17:122–9.
- 176 Clement PB, Scully RE. Mullerian adenocarcinoma of the uterus: a clinicopathologic analysis of 100 cases with a review of the literature. *Hum Pathol* 1990;21:363–81.
- 177 McCluggage WG. A practical approach to the diagnosis of mixed epithelial and mesenchymal tumours of the uterus. *Mod Pathol* 2016;29:S78–91.
- 178 Patrelli TS, Gizzo S, Di Gangi S, *et al.* Cervical Mullerian adenocarcinoma with heterologous sarcomatous overgrowth: a fourth case and review of literature. *BMC Cancer* 2011;11:236.
- 179 Seagle B-L, Kanis M, Strohl AE, *et al.* Survival of women with Mullerian adenocarcinoma: a National Cancer Data Base study. *Gynecol Oncol* 2016;143:636–41.
- 180 Nigro MC, Nannini M, Rizzo A, *et al.* Current status on treatment of uterine adenocarcinoma: updated literature review. *Gynecol Pelvic Med* 2021;4:15.
- 181 Machida H, Nathenson MJ, Takiuchi T, *et al.* Significance of lymph node metastasis on survival of women with uterine adenocarcinoma. *Gynecol Oncol* 2017;144:524–30.
- 182 Yuan Z, Cao D, Yu M, *et al.* Uterine and cervical adenocarcinoma: a retrospective study of overall outcomes and fertility preservation in early-stage disease. *Oncologist* 2019;24:e870–9.
- 183 L'Heveder A, Jones BP, Saso S, *et al.* Conservative management of uterine adenocarcinoma: lessons learned from 20 years of follow-up. *Arch Gynecol Obstet* 2019;300:1383–9.
- 184 Rizzo A, Pantaleo MA, Saponara M, *et al.* Current status of the adjuvant therapy in uterine sarcoma: a literature review. *World J Clin Cases* 2019;7:1753–63.
- 185 Hodgson A, Amemiya Y, Seth A, *et al.* High-grade Müllerian adenocarcinoma: genomic and clinicopathologic characterization of a distinct neoplasm with prevalent TP53 pathway alterations and aggressive behavior. *Am J Surg Pathol* 2017;41:1513–22.
- 186 Nathenson MJ, Conley AP, Lin H, *et al.* Treatment of recurrent or metastatic uterine adenocarcinoma. *Sarcoma* 2017;2017:4680273.
- 187 Zizolfi B, Foreste V, Di Spiezio Sardo A, *et al.* Fertility sparing management of uterine adenocarcinoma: case report and literature review. *Facts Views Vis Obgyn* 2021;12:315–8.
- 188 Ozmen B, Uzum N, Unlu C, *et al.* Surgical conservation of both ovaries in an adolescent with uterine müllerian adenocarcinoma: a case report. *J Minim Invasive Gynecol* 2007;14:375–8.
- 189 Denschlag D, *et al.* Sarcoma of the uterus. Guideline of the DGGG, OEGGG and SGGG(S2k-Level, AWMF Registry no.015/074, April 2021). *Geburtshilfe Frauenheilkd* 2022;82:1337–67.
- 190 Maccaroni E, Lunerti V, Agostinelli V, *et al.* New insights into hormonal therapies in uterine sarcomas. *Cancers (Basel)* 2022;14:921.
- 191 Desai IME, Ottevanger PB, Benson C, *et al.* Systemic treatment in adult uterine sarcomas. *Crit Rev Oncol Hematol* 2018;122:10–20.
- 192 Maeda M, Mabuchi S, Matsumoto Y, *et al.* Activity of pegylated liposomal doxorubicin for extragenital müllerian adenocarcinoma with sarcomatous overgrowth: a case report and a review of the literature. *Eur J Gynaecol Oncol* 2011;32:542–6.
- 193 Schroeder BA, Rodler ET, Loggers ET, *et al.* Clinical benefit of trabectedin in uterine adenocarcinoma. *Med Oncol* 2013;30:501.
- 194 Goulding EA, Morreau P, De Silva M, *et al.* Case report: *NTRK1*-rearranged cervical sarcoma with fibrosarcoma like morphology presenting in a 13-year-old managed with a neo-adjuvant TRK-inhibitor and surgical excision. *Gynecol Oncol Rep* 2021;37:100845.
- 195 Bühler MM, Honcharova-Biletska H, Pauli C, *et al.* Conservative surgical treatment with fertility preservation in a young adult with *NTRK* rearranged spindle cell neoplasm of the uterine cervix. *Gynecol Oncol Rep* 2023;48:101233.
- 196 Doebele RC, Drilon A, Paz-Ares L, *et al.* Entrectinib in patients with advanced or metastatic *NTRK* fusion-positive solid tumours: integrated analysis of three phase 1-2 trials. *Lancet Oncol* 2020;21:271–82.
- 197 Kummur S, Shen L, Hong DS, *et al.* Larotrectinib efficacy and safety in adult patients with tropomyosin receptor kinase fusion sarcomas. *Cancer* 2023;129:3772–82.
- 198 Conlon N, Soslow RA, Murali R. Perivascular epithelioid tumours (PEComas) of the gynaecological tract. *J Clin Pathol* 2015;68:418–26.
- 199 Gadducci A, Zannoni GF. Perivascular epithelioid cell tumors (PEComa) of the female genital tract: a challenging question for gynaecologic oncologist and pathologist. *Gynecol Oncol Rep* 2020;33:100603.
- 200 Kwiatkowski DJ. Tuberous sclerosis: from tubers to mTOR. *Ann Hum Genet* 2003;67:87–96.
- 201 Sobiborowicz A, Świtaj T, Teterycz P, *et al.* Feasibility and long-term efficacy of PEComa treatment-20 years of experience. *J Clin Med* 2021;10:2200.
- 202 Bleeker JS, Quevedo JF, Folpe AL. “Malignant” perivascular epithelioid cell neoplasm: risk stratification and treatment strategies. *Sarcoma* 2012;2012:541626.
- 203 Bourgmayer A, Nannini S, Bonjean P, *et al.* Natural history and treatment strategies of advanced PEComas: a systematic review. *Cancers (Basel)* 2021;13:5227.

- 204 Sanfilippo R, Jones RL, Blay J-Y, *et al.* Role of chemotherapy, VEGFR inhibitors, and mTOR inhibitors in advanced perivascular epithelioid cell tumors (PEComas). *Clin Cancer Res* 2019;25:5295–300.
- 205 Fabbroni C, Sbaraglia M, Sanfilippo R. Medical treatment of advanced malignant perivascular epithelioid cell tumors. *Curr Opin Oncol* 2020;32:301–6.
- 206 Wagner AJ, Ravi V, Riedel RF, *et al.* nab-Sirolimus for patients with malignant perivascular epithelioid cell tumors. *J Clin Oncol* 2021;39:3660–70.
- 207 Sanfilippo R, Fabbroni C, Fucà G, *et al.* Addition of antiestrogen treatment in patients with malignant PEComa progressing to mTOR inhibitors. *Clin Cancer Res* 2020;26:5534–8.
- 208 Liapi A, Mathevet P, Herrera FG, *et al.* VEGFR inhibitors for uterine metastatic perivascular epithelioid tumors (PEComa) resistant to mTOR inhibitors. A case report and review of literature. *Front Oncol* 2021;11:641376.
- 209 Le P, Garg A, Brandao G, *et al.* Hormonal manipulation with letrozole in the treatment of metastatic malignant pecoma. *Curr Oncol* 2014;21:e518–20.
- 210 Lyon AR, López-Fernández T, Couch LS, *et al.* 2022 ESC Guidelines on cardio-oncology developed in collaboration with the European Hematology Association (EHA), the European Society for Therapeutic Radiology and Oncology (ESTRO) and the International Cardio-Oncology Society (IC-OS). *Eur Heart J* 2022;43:4229–361.
- 211 Woopen H, Sehouli J, Davis A, *et al.* GCIg-consensus guideline for long-term survivorship in gynecologic cancer: a position paper from the Gynecologic Cancer InterGroup (GCIg) symptom benefit committee. *Cancer Treat Rev* 2022;107:102396.
- 212 Ray-Coquard IL, Bompas E, Cropet C, *et al.* 822TIP BFR ESS: a randomized phase II trial from the GSF/GETO French group evaluating the impact of interruption versus maintenance of aromatase inhibitors in patients with advanced or metastatic low grade endometrial stromal sarcoma after at least 3 years of therapy. *Ann Oncol* 2021;32.
- 213 Komross FKF, Mar L-M, Howitt BE, *et al.* High-grade endometrial stromal sarcomas with YWHAE:NUTM2 gene fusion exhibit recurrent CDKN2A alterations and absence of p16 staining is a poor prognostic marker. *Mod Pathol* 2023;36:100044.
- 214 Hernán MA, Robins JM. Using big data to emulate a target trial when a randomized trial is not available. *Am J Epidemiol* 2016;183:758–64.
- 215 Schneeweiss S. Real-world evidence of treatment effects: the useful and the misleading. *Clin Pharma Ther* 2019;106:43–4.
- 216 Mandeville KL, Patrick H, McKenna T, *et al.* Assessing the quality of health technology registers for national guidance development. *Eur J Public Health* 2018;28:220–3.
- 217 Momeni-Boroujeni A, Yousefi E, Balakrishnan R, *et al.* Molecular-based immunohistochemical algorithm for uterine leiomyosarcoma diagnosis. *Mod Pathol* 2023;36:100084.
- 218 Prat J, Mbatani N, Nomonde. Uterine sarcomas. *Int J Gynaecol Obstet* 2015;131:S105–110.
- 219 Folpe AL, Mentzel T, Lehr H-A, *et al.* Perivascular epithelioid cell neoplasms of soft tissue and gynecologic origin: a clinicopathologic study of 26 cases and review of the literature. *Am J Surg Pathol* 2005;29:1558–75.
- 220 Van den Bosch T, Dueholm M, Leone FPG, *et al.* Terms, definitions and measurements to describe sonographic features of myometrium and uterine masses: a consensus opinion from the Morphological Uterus Sonographic Assessment (MUSA) group. *Ultrasound Obstet Gynecol* 2015;46:284–98.