


Contents lists available at [ScienceDirect](https://www.sciencedirect.com)

## Cancer Treatment Reviews

journal homepage: [www.elsevier.com/locate/ctrv](http://www.elsevier.com/locate/ctrv)

## REVIEW



## Clinical recommendations for treatment of localized angiosarcoma: A consensus paper by the Italian Sarcoma Group

Elena Palassini<sup>a,\*</sup>, Giacomo Giulio Baldi<sup>b</sup>, Sara Sulfaro<sup>c</sup>, Marta Barisella<sup>d</sup>, Giuseppe Bianchi<sup>e</sup>, Domenico Campanacci<sup>f</sup>, Marco Fiore<sup>g</sup>, Marco Gambarotti<sup>h</sup>, Massimiliano Gennaro<sup>i</sup>, Carlo Morosi<sup>j</sup>, Federico Navarra<sup>k</sup>, Emanuela Palmerini<sup>l</sup>, Claudia Sangalli<sup>m</sup>, Marta Sbaraglia<sup>n</sup>, Annalisa Trama<sup>o</sup>, Sebastian Asaftei<sup>p</sup>, Giuseppe Badalamenti<sup>q</sup>, Rossella Bertulli<sup>a</sup>, Alexia Francesca Bertuzzi<sup>r</sup>, Roberto Biagini<sup>s</sup>, Angela Bonadonna<sup>t</sup>, Antonella Brunello<sup>u</sup>, Dario Callegaro<sup>g</sup>, Ferdinando Cananzi<sup>v,w</sup>, Marco Cianchetti<sup>x</sup>, Paola Collini<sup>y</sup>, Danila Comandini<sup>z</sup>, Annalisa Curcio<sup>aa</sup>, Lorenzo D'Ambrosio<sup>bb</sup>, Tommaso De Pas<sup>cc</sup>, Angelo Paolo Dei Tos<sup>n</sup>, Virginia Ferraresi<sup>dd</sup>, Andrea Ferrari<sup>ee</sup>, Alessandro Franchi<sup>ff</sup>, Anna Maria Frezza<sup>a</sup>, Elena Fumagalli<sup>a</sup>, Matteo Ghilli<sup>gg</sup>, Daniela Greto<sup>hh</sup>, Giovanni Grignani<sup>ii</sup>, Michele Guida<sup>jj</sup>, Toni Ibrahim<sup>l</sup>, Marco Krenqli<sup>kk</sup>, Roberto Luksch<sup>ee</sup>, Andrea Marrari<sup>l</sup>, Marinella Mastore<sup>ll</sup>, Alessandra Merlini<sup>bb</sup>, Giuseppe Maria Milano<sup>mm</sup>, Piera Navarra<sup>nn</sup>, Maria Abbondanza Pantaleo<sup>oo</sup>, Antonina Parafioriti<sup>pp</sup>, Iliara Pellegrini<sup>a</sup>, Elisabetta Pennacchioli<sup>qq</sup>, Marco Rastrelli<sup>rr,ss</sup>, Elisabetta Setola<sup>tt</sup>, Salvatore Tafuto<sup>uu</sup>, Salvatore Turano<sup>vv</sup>, Sergio Valeri<sup>ww</sup>, Bruno Vincenzi<sup>xx</sup>, Viviana Vitolo<sup>yy</sup>, Andrei Ivanescu<sup>zz</sup>, Fiammetta Paloschi<sup>aaa</sup>, Paolo Giovanni Casali<sup>a</sup>, Alessandro Gronchi<sup>g</sup>, Silvia Stacchiotti<sup>a</sup>

<sup>a</sup> Medical Oncology Unit 2, Fondazione IRCCS Istituto Nazionale dei Tumori, Milano, Italy

<sup>b</sup> Department of Medical Oncology, Ospedale Santo Stefano, Prato, Italy

<sup>c</sup> 'Sofia nel Cuore' Onlus

<sup>d</sup> Department of Pathology, ASST Fatebenefratelli Sacco, Milano, Italy

<sup>e</sup> Department of Surgery, Istituto Ortopedico Rizzoli, Bologna, Italy

<sup>f</sup> Department of Surgery, Azienda Ospedaliera Universitaria Careggi, Firenze, Italy

<sup>g</sup> Department of Surgery, Sarcoma Unit, Fondazione IRCCS Istituto Nazionale dei Tumori, Milano, Italy

<sup>h</sup> Department of Pathology, Istituto Ortopedico Rizzoli, Bologna, Italy

<sup>i</sup> Department of Surgery, Breast Unit, Fondazione IRCCS Istituto Nazionale dei Tumori, Milano, Italy

<sup>j</sup> Department of Radiology, Fondazione IRCCS Istituto Nazionale dei Tumori, Milano, Italy

<sup>k</sup> Department of Radiation Oncology, IRCCS Centro di Riferimento Oncologico di Aviano, Aviano, Pordenone, Italy

<sup>l</sup> Department of Medical Oncology, Istituto Ortopedico Rizzoli, Bologna, Italy

<sup>m</sup> Department of Radiation Therapy, Fondazione IRCCS Istituto Nazionale dei Tumori, Milano, Italy

<sup>n</sup> Department of Pathology, Università di Padova, Padova, Italy

<sup>o</sup> Department of Epidemiology, Fondazione IRCCS Istituto Nazionale dei Tumori, Milano, Italy

<sup>p</sup> Department of Pediatric Oncology, Ospedale Infantile Regina Margherita, Torino

<sup>q</sup> Department of Medical Oncology, Azienda Universitaria Policlinico Giaccone, Palermo, Italy

<sup>r</sup> Department of Medical Oncology, Humanitas Cancer Center, IRCCS Humanitas Research Hospital, Rozzano, Milano, Italy

<sup>s</sup> Department of Oncological Orthopedics, IRCCS Istituto Nazionale Tumori Regina Elena - Istituti Fisioterapici Ospitalieri, Roma, Italy

<sup>t</sup> Department of Medical Oncology, IRCCS Centro di Riferimento Oncologico di Aviano, Aviano, Pordenone, Italy

<sup>u</sup> Department of Medical Oncology, Istituto Oncologico Veneto IOV IRCCS, Padova, Italy

<sup>v</sup> Department of Biomedical Sciences, Humanitas University, Pieve Emanuele, Milano, Italy

<sup>w</sup> Sarcoma, Melanoma and Rare Tumors Surgery Unit, Humanitas Cancer Center, Department of Surgery, IRCCS Humanitas Research Hospital, Rozzano, Milano, Italy

<sup>x</sup> Centre of Proton Therapy, ASL Trento, Trento, Italy

<sup>y</sup> Department of Pathology, Fondazione IRCCS Istituto Nazionale dei Tumori, Milano, Italy

<sup>z</sup> Department of Medical Oncology, IRCCS Ospedale Policlinico San Martino, Genova, Italy

<sup>aa</sup> Department of Surgery, Ospedale Morgagni e Pierantoni, Forlì, Italy

<sup>bb</sup> Department of Medical Oncology, Ospedale S. Luigi, Orbassano, Torino, Italy

\* Corresponding author at: Department of Medical Oncology, Fondazione IRCCS Istituto Nazionale dei Tumori, via G. Venezian 1, 20133 Milan, Italy.

E-mail address: [elena.palassini@istitutotumori.mi.it](mailto:elena.palassini@istitutotumori.mi.it) (E. Palassini).

<https://doi.org/10.1016/j.ctrv.2024.102722>

Received 22 February 2024; Received in revised form 17 March 2024; Accepted 26 March 2024

Available online 30 March 2024

0305-7372/© 2024 The Authors. Published by Elsevier Ltd. This is an open access article under the CC BY-NC license (<http://creativecommons.org/licenses/by-nc/4.0/>).

- <sup>cc</sup> Department of Medical Oncology, Humanitas Gavazzeni, Bergamo, Italy
- <sup>dd</sup> Sarcomas and Rare Tumors Departmental Unit, IRCCS Istituto Nazionale Tumori Regina Elena - Istituti Fisioterapici Ospitalieri, Roma, Italy
- <sup>ee</sup> Department of Pediatric Oncology, Fondazione IRCCS Istituto Nazionale dei Tumori, Milano, Italy
- <sup>ff</sup> Department of Pathology, Azienda Ospedaliera Universitaria Pisana, Pisa, Italy
- <sup>gg</sup> Breast Centre, Department of Oncology, Azienda Ospedaliera Universitaria Pisana, Pisa, Italy
- <sup>hh</sup> Department of Radiation Therapy, Azienda Ospedaliera Universitaria Careggi, Firenze, Italy
- <sup>ii</sup> Department of Medical Oncology, Azienda Ospedaliera Universitaria Città della Salute e della Scienza, Torino, Italy
- <sup>jj</sup> Department of Medical Oncology, IRCCS Istituto Tumori di Bari Giovanni Paolo II, Bari, Italy
- <sup>kk</sup> Department of Radiation Therapy, Istituto Oncologico Veneto IOV IRCCS, Padova, Italy
- <sup>ll</sup> Department of Medical Oncology, IRCCS San Gerardo, Monza, Italy
- <sup>mmm</sup> Department of Pediatric Oncology, Ospedale Pediatrico Bambin Gesù, Roma, Italy
- <sup>nn</sup> Department of Radiation Therapy, IRCCS Humanitas Research Hospital, Rozzano, Milano, Italy
- <sup>oo</sup> Department of Medical Oncology, IRCCS Azienda Ospedaliero-Universitaria di Bologna, University of Bologna, Bologna, Italy
- <sup>pp</sup> Department of Pathology, Istituto G. Pini, Milano, Italy
- <sup>qq</sup> Department of Surgery, Istituto Europeo Oncologia, Milano, Italy
- <sup>rr</sup> Department of Surgical Oncology, Istituto Oncologico Veneto IOV IRCCS, Padova, Italy
- <sup>ss</sup> Department of Surgery, Oncology and Gastroenterology (DISCOG), Università di Padova, Padova, Italy
- <sup>tt</sup> Department of Medical Oncology, Istituto Europeo Oncologia, Milano, Italy
- <sup>uu</sup> Department of Medical Oncology, Fondazione IRCCS Istituto Nazionale Tumori G. Pascale, Napoli, Italy
- <sup>vv</sup> Department of Medical Oncology, Azienda Ospedaliera S.S. Annunziata, Cosenza, Italy
- <sup>ww</sup> Department of Surgery, Università Campus Bio-Medico, Roma, Italy
- <sup>xx</sup> Department of Medical Oncology, Università Campus Bio-Medico, Roma, Italy
- <sup>yy</sup> Department of Radiation Therapy, Centro Nazionale di Adroterapia Oncologica, Fondazione CNAO, Pavia, Italy
- <sup>zz</sup> Associazione EHE Italia
- <sup>aaa</sup> Fondazione Italiana GIST ETS

## ARTICLE INFO

**Keywords:**  
 Angiosarcoma  
 Localized disease  
 Clinical management  
 Surgery  
 (neo)adjuvant chemotherapy  
 Radiotherapy  
 Multimodal treatment  
 Clinical recommendations

## ABSTRACT

Angiosarcoma (AS) represents a rare and aggressive vascular sarcoma, posing distinct challenges in clinical management compared to other sarcomas.

While the current European Society of Medical Oncology (ESMO) clinical practice guidelines for sarcoma treatment are applicable to AS, its unique aggressiveness and diverse tumor presentations necessitate dedicated and detailed clinical recommendations, which are currently lacking. Notably, considerations regarding surgical extent, radiation therapy (RT), and neoadjuvant/adjuvant chemotherapy vary significantly in localized disease, depending on each different site of onset. Indeed, AS are one of the sarcoma types most sensitive to cytotoxic chemotherapy. Despite this, uncertainties persist regarding optimal management across different clinical presentations, highlighting the need for further investigation through clinical trials.

The Italian Sarcoma Group (ISG) organized a consensus meeting on April 1st, 2023, in Castel San Pietro, Italy, bringing together Italian sarcoma experts from several disciplines and patient representatives from “Sofia nel Cuore Onlus” and the ISG patient advocacy working group. The objective was to develop specific clinical recommendations for managing localized AS within the existing framework of sarcoma clinical practice guidelines, accounting for potential practice variations among ISG institutions. The aim was to try to standardize and harmonize clinical practices, or at least highlight the open questions in the local management of the disease, to define the best evidence-based practice for the optimal approach of localized AS and generate the recommendations presented herein.

## Introduction

Angiosarcoma (AS) is a rare and aggressive vascular sarcoma. The current European Society of Medical Oncology (ESMO) clinical practice guidelines (CPGs) for the treatment of sarcomas apply to AS as well. However, AS aggressiveness and diverse tumor presentations differentiate it from other sarcomas, impacting clinical decisions. This is especially relevant in the context of localized disease, where considerations about the extent of surgery, the use of radiation therapy (RT), and the indication for neoadjuvant/adjuvant chemotherapy may vary. Conversely, AS are one of the sarcoma types most sensitive to cytotoxic chemotherapy, leading to a somewhat unique approach to systemic treatment. Finally, uncertainties persist regarding optimal treatment for different clinical presentations, ideally to be addressed through clinical trials. Yet, the rarity of AS poses challenges in conducting such trials.

On this background, the Italian Sarcoma Group (ISG) convened a consensus meeting of the optimal approach to localized AS on April 1, 2023, in Castel San Pietro (Bologna, Italy). The meeting involved Italian sarcoma experts from various fields and patient representatives from “Sofia nel Cuore Onlus” and the ISG patient advocacy working group to develop specific clinical recommendations for managing localized AS within the existing framework of CPGs on sarcomas. These recommendations take into account potential variations in clinical practices among

ISG institutions. The goal was, nonetheless, to standardize and harmonize clinical practices or, at the very least, to make different treatment attitudes explicit. Following this meeting, ISG launched an Italian multicentric prospective observational study on primary AS to address real-world clinical questions.

## Methodology

The consensus development process took place within the ISG community, with an active involvement of all centres belonging to the Italian Sarcoma domain of EURACAN and patient representatives. Specialists from seven specialities were involved (i.e. epidemiology, pathology, surgery, radiation oncology, adult medical oncology, pediatric medical oncology, and radiology). Literature search was conducted considering paper, written in English, including > 1 cases, published in PubMed from 2000 until December 2022 (Details on strategy and selection criteria are presented in [Supplementary material](#)). Each speciality subgroups met virtually to draft a first document and highlight the most critical aspects to be discussed with the whole group. During the consensus meeting critical points were discussed, reaching a consensus or sharing discrepancies. Afterwards, the final version of the document was drafted and circulated for the final approval. Due to the lack of prospective data on local phase, current practice is mainly based on

retrospective reports. Consequently, a degree of uncertainty needs to be accepted in clinical management and regulatory matters and, as a result, levels of evidence and grades of recommendation were not included.

### Epidemiology and clinical presentation

Angiosarcoma is a rare sarcoma (crude incidence, range: 0.3–0.5/100.000 [1–3]), with 140 new cases expected in Italy annually. There is a female predominance, however, the male-to-female ratio differs by site of origin, ranging from 0.2 for limb AS to 2.0 for cutaneous head and neck (H&N) AS [2]. AS can occur at any age, with a peak incidence in the seventh decade, and is very rare in children [4–7]. The mean age is higher in secondary AS compared to primary AS (74 vs 66 years, respectively) [8].

Although the etiology is unknown in most cases (also called “primary AS”), AS may be associated to risk factors (also named “secondary AS”). There are two well-known risk factors: chronic lymphedema and RT. Lymphedema-associated AS is also known as Stewart-Treves syndrome. Familial syndromes including neurofibromatosis, Maffucci syndrome, and Klippel-Trenaunay syndrome are also associated with AS. Occupational exposure to vinyl chloride and thorium dioxide is associated with hepatic AS. Other chemical carcinogens associated with AS include arsenic, radium, and anabolic steroids. Few studies report the association of AS with foreign bodies, including accidentally retained surgical gauze, vascular and orthopedic prostheses [9].

AS can occur anywhere in the body. Approximately 60% of AS arise in the skin and soft tissue, while 40% are visceral [10,11,2]. Based on a pool analyses of approximately 600 AS patients, H&N skin is the most common site (27%), followed by breast, mostly radiation-associated (20%), extremities (15%), trunk (9%), liver (6%), heart (5%), bone (4%), and spleen (3%) [9]. 80% of radiation-associated AS (RAAS) arise in the breast area [8].

AS clinical features vary depending on the site. Skin AS often appears as purple lesions, sometimes multiple and bleeding [12]. Deep tissue and breast AS present as enlarging lesions. Breast RAAS is often multifocal, spreading to skin and deep tissue. Cardiac AS, usually from the right atrium, shows symptoms like chest pain, dyspnea, cough, and hemoptysis [13].

### Prognosis

AS is typically aggressive. The prognosis is poor, with a 5-year overall survival (OS) ranging from 30 to 50%, although there is some prognostic variability across presentations. Visceral AS generally show a worse prognosis [4,14–17]. The risk of recurrence after surgery is high. The 5-year local relapse free survival (RFS) ranges from 25 to 35%. Typically in cutaneous AS, including RAAS, local recurrences can be difficult to manage and patients may die of locoregional disease [17–22]. The 5-year distant RFS is about 30%. Metastases may affect lungs, bone, liver, soft tissues, lymph node (LN), and brain [4,14–17].

With regard to prognostic factors, larger tumors (>5 cm) and the presence of an epithelioid component correlate with a worse outcome [4,15,23]. Most AS have a high-grade appearance. For those with a low-grade aspect, its prognostic role is debated, as even well-differentiated tumors can behave aggressively [24,25]. Interestingly, primary breast AS is the only AS subgroup in which the value of grading has been traditionally kept into consideration, despite conflicting results emerging from the available literature [26,27] and its importance has been recently re-assessed [28].

### General principles of localized as management

Patients should be managed within sarcoma reference centers or networks, by a dedicated sarcoma multidisciplinary team including pathologist, radiologist, surgical oncologist, radiation oncologist, medical oncologist, and palliative care specialist. Based on disease

presentation other specialists such as orthopedic surgeon, breast surgeon, plastic surgeon, genetist need to be involved.

### Pathology

Pathological diagnosis is recommended in all cases, before any treatment is started and pathologic review by an expert sarcoma pathologist is strongly recommended if the first diagnosis was made outside a reference center. Diagnosis should be made by core needle biopsy or incisional biopsy, obtaining a sufficient amount of tissue for accurate pathological evaluation. In case of a heterogeneous lesion, functional imaging should be used to guide the biopsy to the highest grade portions. Correlation with clinical aspects is crucial in the diagnostic process. Superficial and skin AS can be diagnosed with a punch biopsy, for deeper lesions is preferable percutaneous core needle biopsy with 14–16 G needle. For splenic lesions, the role of percutaneous biopsies is controversial due to the risk of bleeding.

### Morphology

AS morphological spectrum is rather broad. Details are provided in the [Supplementary material](#) (Pathology, Morphology).

### Immunophenotype

AS shows a typical membrane-type immunopositivity for CD31 and nuclear expression for ERG. Both these markers show high sensitivity but are not entirely specific. Details are provided in the [Supplementary material](#) (Pathology, Immunophenotype).

### Molecular profile

AS is molecularly heterogeneous. Despite recent data have shown a large site-specific molecular heterogeneity, the molecular characterization of AS is not recommended for the diagnosis.

Primary and secondary AS are characterized by a complex genetic profile. Molecular alterations such as the presence of *MYC* amplification are much more common RAAS [29]. Detection of *MYC* gene amplification or *MYC* protein overexpression represent powerful diagnostic tool that helps distinguish AS from atypical vascular lesions [30] and contribute to confirm a diagnosis of RAAS. A small minority of cases may lack *MYC* aberration and therefore diagnosis will rely only upon morphology. Furthermore, co-amplification of *FLT4* and *MAML1* has been reported in secondary AS, as additional genetic alterations involving the MAPK pathway [31] and mutations of *TP53*, *KDR* and *CDKN2* [32]. In primary breast AS, *KDR* and *PIK3CA* gene mutations are reported [28]. Fusions in AS are extremely rare, however, *CIC* gene rearrangements are reported in soft tissue AS [33]. Cutaneous AS arising in the H&N of elderly patients seem to be associated with high tumor mutational burden, as typically observed in tumors associated with an UV mutational signature [34].

---

*Pathological diagnosis is recommended before any treatment is started and should be confirmed by a sarcoma expert pathologist.*

---

*Molecular testing is not mandatory. However, in the suspicion of RAAS, it is useful to identify c-MYC amplification/expression by molecular analysis or immunohistochemistry.*

---

### Radiology

#### Staging

Gadolinium-enhanced magnetic resonance imaging (MRI) represents the exam of choice in AS, providing information about both anatomical

extent and tumour composition. Minimum protocol should include T1- and T2- weighted sequences, short tau inversion recovery or T2-weighted fat-saturated sequences, diffusion-weighted imaging (DWI) with apparent diffusion coefficient maps, and T1-weighted fat-saturated sequences after intravenous contrast administration. Dynamic contrast-enhanced MRI sequences are mandatory in breast, liver, and spleen.

In skin AS, MRI can underestimate disease extension and correlation with clinical aspects is crucial. Clinical photograph and biopsies of the surrounding tissues may be indicated for AS of the skin, especially when a pre-operative treatment is planned.

Staging should include a total body CT scan (including brain) to rule out metastases, and bone assessment by 18-F-FDG PET/CT or bone scintigraphy. Lung metastases show a characteristic pattern with multiple solid pulmonary nodules or, more rarely, with ground glass opacities surrounding pulmonary nodules (CT halo sign) [35].

#### Radiological features

AS manifests as an irregular enhancing infiltrative mass or as nodular lesion with an aggressive behavior on adjacent structures [36]. Generally, AS is characterized by low T1-weighted and high T2-weighted signal intensity (SI), with a significant restriction signal on DWI sequence. Necrotic areas present high T2-weighted SI, while hemorrhagic areas show high T1-weighted SI with marked low T2-weighted SI on gradient echo in the presence of hemosiderinic deposits.

In each specific site of origin, some peculiar characteristics may be observed. Details are provided in the [Supplementary material](#) (Radiology).

#### Radiological assessment of response

When pre-operative treatment is planned, MRI should be performed at the beginning, during, and prior to surgery. In skin AS, pre-operative treatments may necessitate skin tattoos to accurately gauge disease extent, as MRI might underestimate it. Similarly, capturing photographic images of visible tumors helps monitor treatment response.

---

**Gadolinium-enhanced MRI is the preferred exam to evaluate local disease extension. Staging should include whole body CT scan (including brain), and bone assessment by 18-F-FDG PET/CT or bone scintigraphy.**

---

## Surgery

#### General principles

Wide resection is the standard treatment for localized AS and should be performed by a sarcoma expert surgeon. This approach involves the removal of the tumor in a single specimen along with a surrounding rim of normal tissue.

The minimal margin considered adequate on fixed tissue may vary based on factors such as the use of neoadjuvant treatments and the presence of resistant anatomical barriers like muscular fascia, vascular adventitia, periosteum, and epineurium. Deep-seated AS in the upper or lower limb may directly involve a major vessel, typically an artery, necessitating en-bloc resection of the vascular bundle in such cases.

It is emphasized that systematic regional lymphadenectomy or sentinel LN biopsy is not recommended. Regional lymphadenectomy is only indicated when there is clinically and/or radiologically confirmed nodal involvement. *Recommendations.*

---

**Wide resection is the standard treatment of localized AS.**

---

**Systematic regional lymphadenectomy or sentinel LN biopsy are not recommended.**

---

#### Skin AS (H&N region)

For skin AS, which predominantly affects the H&N in the elderly, surgery is seldom recommended due to its multifocal presentation and extensive involvement of the scalp/face. Systemic treatment combined to definitive RT are typically considered viable alternatives to surgery. Clinical photographs and tattoos are useful to assess response and plan subsequent resection, when feasible.

In the small AS, often resected with a preoperative clinically diagnosis of non melanomatous skin cancer, wide excision should be performed to ensure negative margins both over the skin and in deep tissues. Bioptic mapping of the region may prove useful to assess the actual disease extent and plan the surgery. Plastic reconstruction to cover the defect is nearly always necessary. Tissue expanders are frequently utilized to prepare adequate flaps for tissue coverage. Otherwise, complex locoregional rotation flaps or free flaps are the only viable alternatives. Adjuvant RT may also be considered. *Recommendations.*

---

**When wide resection is unfeasible, definitive RT with or without systemic treatment represents an option.**

---

#### Breast region AS

Total mastectomy incorporating the muscular fascia is the standard treatment for primary breast AS and is preferred over breast-conserving surgery [37,38]. However, for small, peripheral primary breast AS within large breasts, wide resection could be considered on an individualized basis. RAAS often requires the excision of a wide area of the breast skin due to its multifocal presentation, and to remove previously irradiated skin. Therefore, conservative techniques are not recommended for breast RAAS. In general, while the skin is crucial for RAAS, the deep planes are more critical for primary breast AS, sometimes requiring en-bloc removal of the underlying muscles (major pectoralis and/or serratus) along with the affected breast parenchyma. Discussion at a sarcoma tumor board to review the pathology and treatment plan before any surgery is highly recommended.

Systematic regional lymphadenectomy or sentinel LN biopsy is not indicated. For patients with clinically suspicious nodes, ultrasound-guided fine-needle biopsy of enlarged nodes can accurately document regional metastases. In cases of pathologically confirmed LN involvement at staging, axillary dissection is appropriate.

Given the high risk of recurrence, cosmetic reconstruction should generally be delayed. For larger tumors or RAAS with extensive skin involvement, myocutaneous flaps are required to cover the excised area and no impact on cosmesis. The morbidity risk in case of major reconstructive surgery should not be underestimated, and the possibility of some delay in post-operative treatments should be factored during the initial strategy planning.

The use of implants in breast reconstruction is not the preferred choice both in primary AS, due to the need to remove a portion of the major pectoralis muscle, and in RAAS because of the previous RT. Consequently, myocutaneous flaps represent the first choice in most cases. The transverse rectum of abdomen myocutaneous (TRAM) flap and the latissimus dorsi flap are the most commonly used, with differences in terms of skin and volume replacement. The transposition of healthy, non-irradiated blood-supplied tissue may allow better healing and, in selected cases, can even be combined with implants for cosmetic



purpose. *Recommendations.*

Primary breast AS	Breast region RAAS
<p><b>Total mastectomy, including major pectoralis muscle fascia removal, is the treatment of choice. Deeper tumors may require resection of chest wall muscles like major pectoralis. For small, peripheral tumors in a large breast, wide excision with clear margins may be considered on a case-by-case basis.</b></p> <p><b>Breast reconstruction should be delayed, a 2–3 year free interval is suggested. In selected cases, the immediate (direct to implant) or dual time breast reconstruction with an expander may be considered.</b></p>	<p><b>Total mastectomy is the preferred treatment, with removal of previously irradiated skin. Conservative techniques are generally not recommended. On an individualized basis, for small, peripheral tumors within a large breast, wide excision could be considered, once multifocal disease has been excluded and free margins are obtained.</b></p> <p><b>Breast reconstruction should be delayed, a 2–3 year free interval is suggested.</b></p>

**Soft tissue AS**

Surgery adheres to the principle of STS resection. When a major vessel is involved or the tumor originates from a major vessel (usually an artery), the surgical approach should encompass the resection of the affected vascular bundle, with reconstruction as necessary. The accompanying vein is often involved or too closely sited to be preserved and is typically ligated. Arterial reconstruction is preferably performed using an autograft. In the rare cases when the tumor arises from the aorta, a PTFE prosthesis is recommended instead. If required, vein reconstruction may be carried out using autografts, homografts (cadaveric veins/arteries), or, albeit less preferred, PTFE prostheses.

For extremity AS, isolated limb perfusion (ILP) with TNF- $\alpha$  and melphalan, usually followed by surgery, may be considered as an option, with significant tumor responses observed [39]. ILP has no impact on systemic control (although it can be combined with other modalities). Additionally, ILP can be regarded as a definitive treatment in Stewart-Treves syndrome, especially in extensive multifocal AS. Electrochemotherapy may be another option for cutaneous AS, even if no data are available in this specific setting. *Recommendations.*

---

*Surgical treatment of soft tissue AS should adhere to the principles of STS resection. When a major vessel is involved, the resection of the vascular bundle is required and vascular reconstruction may be needed.*

---

*ILP may be an option in pre-operative setting in extremity AS. ILP may be considered as a definitive treatment in multifocal AS, especially in the context of Stewart-Treves syndrome.*

---

**Visceral AS (including heart)**

Surgery for visceral AS necessitates the resection of the affected viscus with negative margins. Sacrificing the entire organ is unnecessary if the anatomy and presentation permit a more conservative approach. Regional lymphadenectomy is unnecessary unless the regional LNs are clearly involved.

Surgery for heart AS poses particular challenges, and peri-operative treatments are vital to ensure tumor control and preserve acceptable remaining heart function. Surgery may be performed upfront for clinical reasons and peri-operative treatments delivered only in the post-operative setting. Definitive RT should be considered when a complete surgical approach is unfeasible. Heart transplantation is rarely, if ever, indicated in heart AS. *Recommendations.*

(continued)

---

*Surgical treatment of visceral AS necessitates the resection of the affected viscus, with negative margins, without the need to sacrifice the entire organ if the anatomy and presentation permit a more conservative approach.*

---

*Surgical treatment of visceral AS necessitates the resection of the affected viscus, with negative margins, without the need to sacrifice the entire organ if the anatomy and presentation permit a more conservative approach.*

---

*In heart AS complete resection with negative margins may be difficult to achieve. When surgery is unfeasible, definitive RT is an option.*

---

**Bone AS**

In appendicular skeleton AS, limb salvage should be considered when negative margins can be achieved. In centrally located tumors (axis and pelvis), achieving negative margins may be more challenging, yet it remains critical [40].

Following bone resection, conventional reconstruction should be undertaken using megaprosthesis, allografts, or allograft-prosthetic-composite reconstruction, depending on the tumor site and the patient’s age. Megaprosthesis should be favoured rather than biologic reconstruction when a post-operative RT is planned. Since bone AS may be multifocal, involving the same bone segment or different contiguous bones, radical surgery with entire bone segment removal can be considered or, in selected cases, limb amputation, especially in distal extremities. When bone AS presents with a pathologic fracture, tumoral spread and contamination of surrounding soft tissues make achieving negative margins difficult, and limb amputation should be considered to obtain local control [41]. *Recommendations.*

---

*Surgical treatment of bone AS should achieve negative margins both in axial and appendicular skeleton. In case on pathological fracture limb amputation should be considered.*

---

**Radiation therapy**

*General principles*

In high-grade, localized, extremity STS, neoadjuvant/adjuvant RT is considered standard treatment [42], based on prospective studies [43,44]. By contrast, there are no prospective data on the role of neoadjuvant/adjuvant RT in AS. However, given the high-risk of local recurrence post-surgery and the histotype’s sensitivity to RT, it’s usually added to surgical treatment.

Timing of RT should be shared jointly with surgeons in the context of a multidisciplinary tumor board. In STS, local control and overall survival (OS) are not influenced by the timing of RT. However, today, many centers prefer the pre-operative setting since a lower dose is needed and lower tissue volume is irradiated, resulting in a lower rate of long-term morbidity compared to the post-operative setting [42]. Despite the absence of specific data in AS, this approach is considered reasonable, given the radiosensitivity of this histotype. RT should be performed at a dose of 50 Gy and 60/66 Gy, in the pre-operative and post-operative setting, respectively, with the exception of some specific presentations in which different doses should be considered (see below).

In case of limited tumor size (i.e., <5 cm), superficial location and unifocality, after multidisciplinary discussion, RT may be omitted if the resection margins are microscopically negative. *Recommendations.*

---

*Perioperative RT is frequently indicated in AS. The setting varies among institutions, but there is an overall shift towards the use of neoadjuvant RT.*

---

*In case of limited tumor size (i.e., <5 cm), superficial location and unifocality RT may be omitted.*

---

(continued on next column)

**Skin AS (H&N region)**

When a surgical approach is feasible, the timing of complementary RT should be discussed on the basis of the plastic reconstruction [45], privileging a pre-operative setting if a plastic reconstruction is planned. Regarding RT extent, sarcoma centers vary in their approaches. Some favour a locoregional treatment limited to the disease and others adopt a total scalp irradiation (TSI) taking into consideration the absence of anatomical barriers in this site. The recommended doses in the pre-operative and post-operative setting are 50 Gy in 2 Gy/fraction and 60 Gy in 1.8–2 Gy/fraction, respectively.

In multifocal/diffuse H&N AS, RT with definitive intent can be offered as alternative to demolitive surgery. In this setting, 66/70 Gy should be considered [46–49].

Protons can have a dosimetric advantage even compared to more sophisticated techniques with photons, such as volumetric modulated arc therapy (VMAT), intensity modulated radiation therapy (IMRT) [50,51].*Recommendations.*

---

**In H&N AS, when a surgical approach is feasible, pre-operative RT is preferable, especially if a plastic reconstruction is foreseen.**

---

**In case of multifocal and diffuse skin involvement, definitive RT may be an option.**

---

**Breast region AS**

In primary breast AS, the use of neoadjuvant/adjuvant RT is recommended. RT may be omitted in case tumor nodule is unifocal and small in relation to the size of the breast, taking into account also the extent of received surgery.

Breast region RAAS are characterized by a high-risk of loco-regional recurrence [52–57]. However, the use of neoadjuvant/adjuvant RT in RAAS is still limited and varies across centers, out of concern of toxicities related to re-irradiation. This group agreed that neoadjuvant/adjuvant RT should be always discussed in breast region RAAS. Of course, there is a risk of either early toxicities such as dermatitis, skin necrosis and pain or late toxicities such as osteonecrosis, ribs fracture, soft tissue necrosis, lymphedema, fibrosis, brachial plexopathy, lung fibrosis, and coronaropathy (especially when RT is performed on the left chest wall). However, data on the feasibility and safety of re-irradiation have been provided, in the context of the management of recurrent breast carcinoma [58–61]. In addition, most recent RT techniques (e.g. VMAT, IMRT or tomotherapy) may help to limit toxicities, and protons may represent an additional advantage [62–66]. Finally, recently, an analysis on 84 breast region RAAS, treated at two reference Italian sites, showed that the addition of RT to surgery improved RFS in comparison to surgery alone [67]. The feasibility of a re-irradiation should always be evaluated at a sarcoma reference center. A range dose of 45–50.4 Gy and of 50.4–60 Gy should be considered, in the pre-operative and post-operative setting, respectively, after an accurate evaluation of the previous treatment dosage plan to assess the cumulative dose to organs at risk as heart (the recommended dose is Dmean <5–6 Gy, and possibly V5LV <17%, V23 <5%) [68], lungs, and spinal cord.

In case of diffuse multifocal skin involvement, when surgical resection is too morbid and at high-risk of local failure, RT may be considered as a definitive treatment.*Recommendations.*

<b>Primary breast AS</b>	<b>Breast region RAAS</b>
<i>Perioperative RT is often considered. RT may be omitted if tumor lesion is unifocal and small relative to breast size.</i>	<i>Perioperative RT should be considered in RAAS of the breast region.</i>

**Soft tissue AS**

Consistently with the treatment of high-grade STS of the limbs and superficial trunk [42], neoadjuvant/adjuvant RT is considered standard treatment in soft tissue AS.

When indicated, RT is preferably administered in the pre-operative setting, especially when a vascular reconstruction is planned.

The recommended doses are 50–50.4 Gy in 1.8–2 Gy/fraction and 60–66 Gy in 1.8–2 Gy/fraction in the pre-operative and post-operative setting, respectively.*Recommendations.*

---

***In soft tissue AS, the use of perioperative RT follows the principle applied in STS of other sites. A pre-operative setting is preferable, especially when a vascular reconstruction is planned.***

---

**Visceral AS**

In liver and spleen AS, no data support the systematic use of neoadjuvant/adjuvant RT.

In cardiac AS, the neoadjuvant/adjuvant RT is recommended. The post-operative setting is generally preferred, even because surgery is performed in emergency in many patients. The use of adjuvant RT is supported by some retrospective series that report an outcome benefit [13,69,70]. When surgery is not urgently required, the timing of RT should be discussed and agreed upon with the cardiac surgeon and pre-operative RT may be considered after obtaining a pathological diagnosis. Moreover, RT seems to be of value also after macroscopically incomplete (R2) surgery, in a site where a complete resection with free margins is challenging [70]. When surgery is unfeasible, definitive RT may be an option.

Irradiating a cardiac AS poses challenges due to the motion of the heart and lungs, as well as the risk of radiation-related cardiac toxicity. Therefore, it is strongly recommended to use specific high-technology RT techniques such as IMRT, VMAT, tomography (TOMO), MRI-guided RT, or particle therapy [71,72]. For addressing organ and target motion, RT planning should include 4D CT simulation. Techniques like breath-hold or respiratory gating could be useful in guiding RT, sparing organs at risk, and controlling organ motion. Image fusion with basal cardiac angio CT with contrast medium or MRI is recommended for target definition.

The recommended doses are 45–50 Gy in 1.8–2 Gy/fraction and 54–60 Gy in 1.8–2 Gy/fraction in the pre-operative and post-operative setting, respectively. Literature suggests a deleterious role of hypofractionation for expected higher RT related toxicity on healthy cardiac substructures [73].*Recommendations.*

---

***In heart AS, when surgery is macroscopically complete, the addition of RT should be weighted against toxicity. Definitive RT should be considered when surgical approach is unfeasible, or after R2 resection.***

---

***In other viscera perioperative RT should be discussed in the multidisciplinary board on a case by case basis.***

---

**Bone AS**

In bone AS, neoadjuvant/adjuvant RT should be considered on a case by case basis.

In a large retrospective study focusing on bone AS, adjuvant RT was associated to an improved disease-free survival in patients with localized tumors following complete surgical resection [40,74].

In the pre-operative and in the post-operative settings the

recommended doses are 50 Gy and 60 Gy, respectively. In a palliative setting (symptomatic) the dose is lower (30 Gy) [74].

However, in bone AS, considering the higher risk of wound dehiscence following pre-operative RT, which could eventually lead to a deep infection of the reconstruction, post-operative adjuvant RT should be preferred. Adjuvant RT hampers bone allograft healing, advising prosthetic over biologic options when post-operative RT is planned.

In case of unresectable lesion or in unfit patients for major surgery, definitive RT could be considered. *Recommendations.*

---

*In bone AS, perioperative RT should be considered on a case by case basis, encouraging post-operative setting.*

---

## Systemic treatment

Neoadjuvant/adjuvant chemotherapy is not a standard treatment for localized, resectable STS, given the conflicting results by the several randomized clinical trials [75,76]. However, in the most common extremity and superficial trunk STS, there is some evidence that patients at a higher risk of death may benefit from neoadjuvant chemotherapy with anthracycline and ifosfamide (AI) for 3 cycles, in terms of RFS and OS [77–82]. On this basis, the last version of the ESMO CPGs suggested full-dose neoadjuvant/adjuvant chemotherapy with AI for 3 cycles as an option for fit patients with localized STS at high-risk of death [42].

In AS, prospective data on neoadjuvant/adjuvant chemotherapy are lacking. The largest retrospective analysis in primary AS, involving 33 sarcoma centers in Europe, included 362 localized AS of any site and showed that neoadjuvant/adjuvant chemotherapy may improve outcomes for patients with larger tumors (>5 cm) and/or higher risk of death (predicted 10-year mortality risk >60%) [23]. The 10-year OS probability was determined using Sarculator [83], with tumor grade set at “3” and “vascular” histology selected for all patients. However, no conclusions were drawn about the best regimen. More recently, a retrospective analysis of breast region RAAS from two Italian centers showed a correlation between neoadjuvant/adjuvant chemotherapy and RFS. Gemcitabine-based regimens (gemcitabine +/- docetaxel) performed better than other regimens [67]. Indeed, over the past decade, given the promising activity and efficacy of gemcitabine and taxanes in advanced AS [84,85], their use in the neoadjuvant/adjuvant setting has increased in several centers, especially in Italy. This is particularly relevant for patients with RAAS, who likely received anthracyclines for previous cancer treatment.

On this basis, considering the high-risk of recurrence and that AS are one of the sarcoma types most sensitive to anthracycline-based chemotherapy, with an expected ORR of 25–30% in the advanced phase of disease [86–89], this group agreed that neoadjuvant/adjuvant chemotherapy is recommended in localized AS, >5 cm and/or at 10-year death risk >60%. For AS of <5 cm and/or 10-year death risk <60%, neoadjuvant/adjuvant chemotherapy can still be discussed but the policy varies across institutions. In the lack of a correlation between pathological grading and prognosis, grading should not be factored when neoadjuvant/adjuvant chemotherapy is discussed.

Regarding the chemotherapy regimen, this group reached a consensus that 3 cycles of AI chemotherapy represent a viable option, similar to other STS, also based on the documented activity of anthracyclines in advanced AS [86–89]. On the other side, although data available are limited, especially those on gemcitabine, valuing activity of gemcitabine and taxanes in advanced AS and recent data on the role of gemcitabine-based regimens in neoadjuvant/adjuvant setting [67], this group agreed that all the most active agents in AS (i.e. anthracyclines, ifosfamide, gemcitabine, taxanes) may be proposed, up to 6 cycles (e.g., 3 cycles of AI and 3 cycles of gemcitabine plus taxanes). Unfit patients or patients pretreated with anthracyclines may be treated with a gemcitabine-based regimen for 6 cycles or with gemcitabine

monotherapy for 3 cycles and paclitaxel monotherapy for 3 more cycles. Conversely, there is a lack of data supporting the utilization of liposomal doxorubicin in the neoadjuvant/adjuvant setting in sarcomas and angiosarcoma.

In locally-advanced AS, when a pre-operative systemic treatment with cytoreductive intent is needed, chemotherapy may be continued for more than 6 cycles, until best response and resectability are reached.

In cardiac AS, the feasibility of an anthracycline-based chemotherapy should be shared with a cardiologist and, when feasible, a close monitoring of cardiac function is recommended.

In bone AS, due to even scarcer data on the role of neoadjuvant/adjuvant chemotherapy compared to soft tissue AS, there is no consensus on its use. The decision and choice of regimen vary among sarcoma centers. Consistently, no definitive conclusions can be drawn on the use of adjuvant chemotherapy in bone AS and no recommendation on the superiority of a specific chemotherapy regimen can be provided. Details on literature are provided in the [Supplementary material](#) (Systemic treatment).

When chemotherapy is selected, the timing should be discussed in the multidisciplinary tumor board/network. A pre-operative treatment should be encouraged, possibly in combination to RT. Moreover, when pre-operative RT is selected, concurrent chemo-radiation therapy should be considered to prevent chemotherapy treatment delays. Data on combining AI with RT are available for extremity and trunk-wall STS [90]. In other sites, concurrent chemotherapy and RT feasibility should be evaluated in a multidisciplinary context, possibly using anthracyclines or ifosfamide alone to minimize toxicities. In summary, one of the following approaches might be offered after multidisciplinary discussion, for the treatment of localized AS:

- neoadjuvant chemotherapy → surgery → (+/- adjuvant chemotherapy) → adjuvant RT
- (+/- neoadjuvant chemotherapy) → concurrent chemotherapy (with AI, in combination, or as monotherapy) and RT → surgery → (+/- adjuvant chemotherapy)
- surgery → adjuvant chemotherapy → adjuvant RT

**Figures 1–5** report the treatment algorithm for localized AS, with the integration of the three modalities of treatment (surgery, RT, systemic treatment) with regard to every specific site. *Recommendations.*

---

*In soft tissue AS and fit patients, when neoadjuvant/adjuvant chemotherapy is selected, 3 cycles of full-dose AI is an option. Alternatively, the use of all the most active agents in AS can be considered (anthracyclines, ifosfamide, gemcitabine, taxanes) up to 6 cycles (e.g., AI for 3 cycles + gemcitabine plus taxanes for 3 cycles).*

*In bone AS, available data do not support the use of a specific chemotherapy regimen. The use of the regimens used in the other sites is an option.*

---

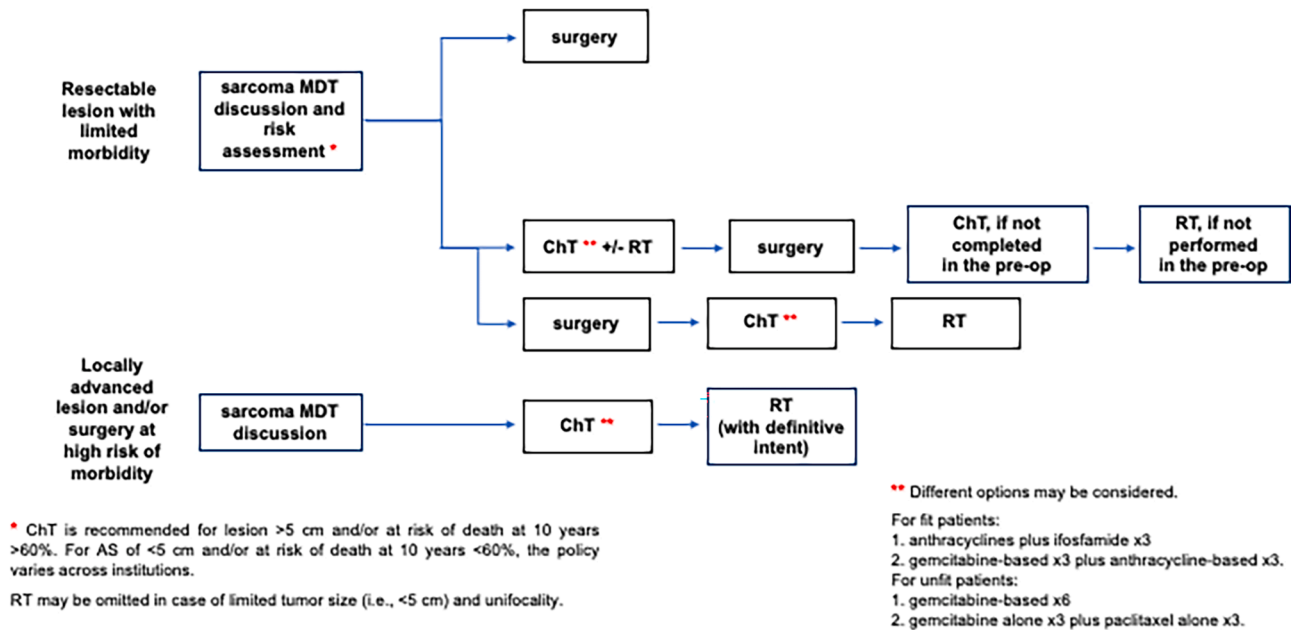
*The timing of the chemotherapy should be discussed in the context of a multidisciplinary tumor board. Pre-operative chemotherapy should be encouraged, possibly in combination to RT.*

---

## Follow-up

No data are available on optimal follow-up of AS. Treating physicians should inform patients to contact the treating team if there are any concerning symptoms and signs, particularly for cutaneous angiosarcoma. On the other side, consistently with sarcoma in general, following the end of treatment, an MRI of the primary tumor site and a whole-body CT scan may be suggested every 3–4 months for the first 2–3 years, then every 6 months up to 5 years, and then yearly. Cardiac ultrasound and cardiac function assessment are suggested in case of cardiac AS, and in patients treated with anthracycline-based neoadjuvant chemotherapy.

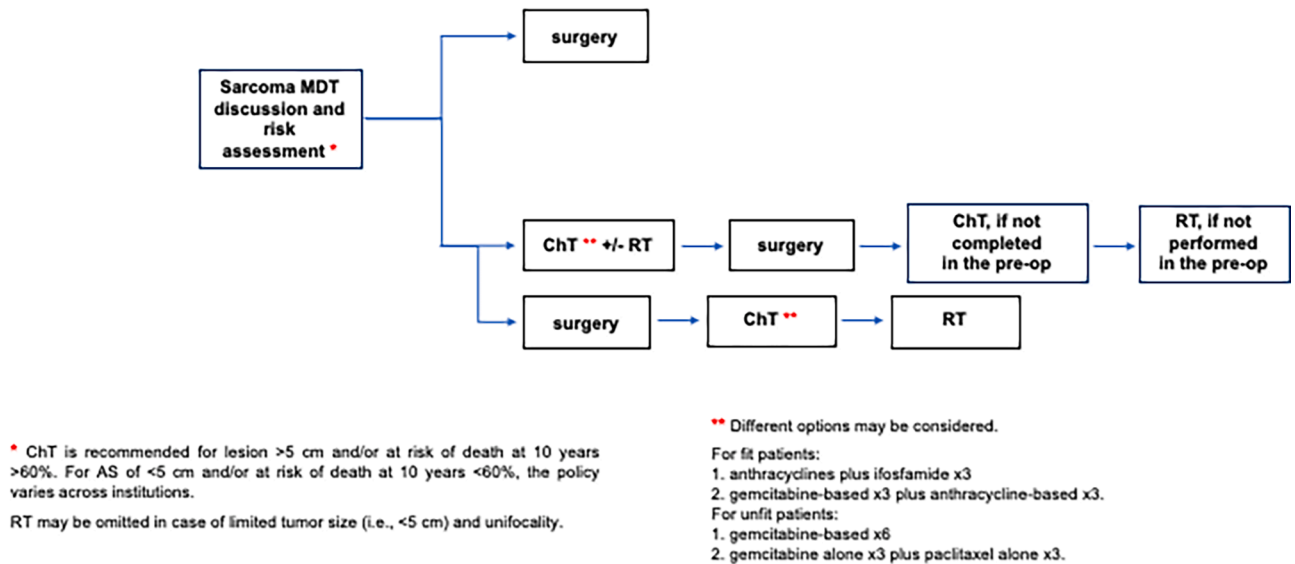
## Treatment algorithm, localized skin AS (head and neck) and breast region RAAS



Legend: AS= angiosarcoma; RAAS= radiation-associated angiosarcoma; MTD= multidisciplinary discussion; ChT= chemotherapy; RT= radiotherapy.

Fig. 1. Report the proposed treatment algorithm for localized skin AS, breast region RAAS.

## Treatment algorithm, localized primary breast AS



Legend: AS= angiosarcoma; MTD= multidisciplinary discussion; ChT= chemotherapy; RT= radiotherapy.

Fig. 2. Report the proposed treatment algorithm for localized skin AS, primary breast AS.

### Funding

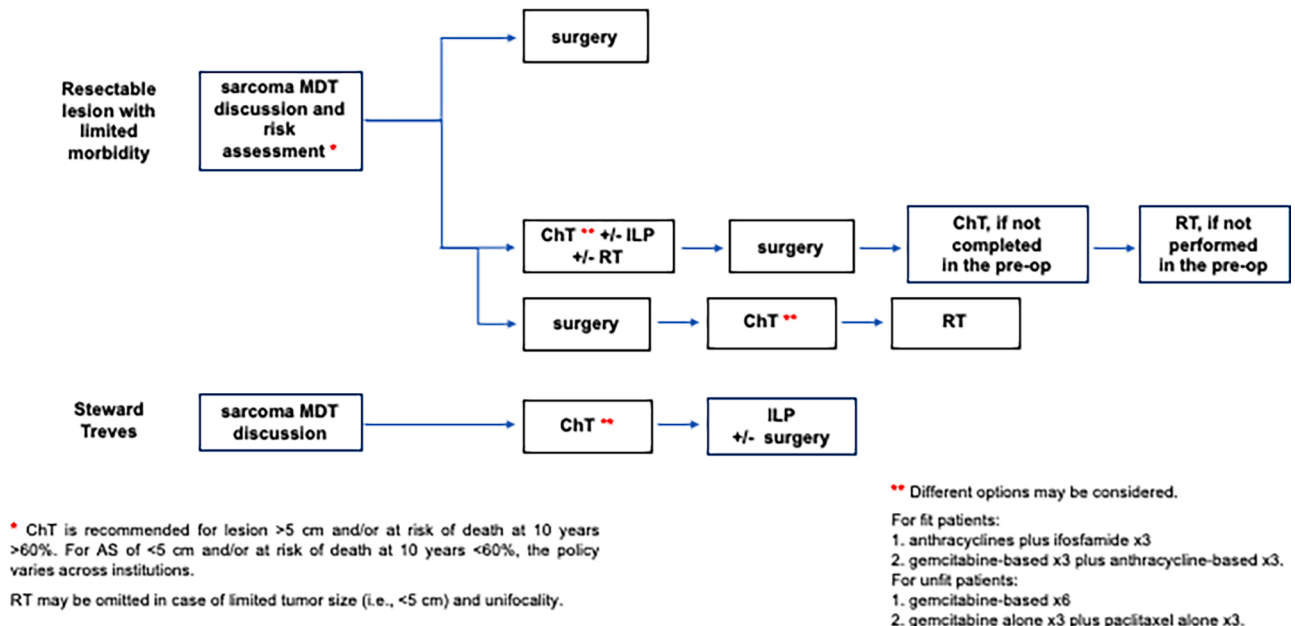
This research did not receive any specific grant from funding agencies in the public, commercial, or not-for-profit sectors.

### Authors contributions statement

**Elena Palassini** conceptualization, data curation, supervision, validation, original draft preparation, review and editing. **Giacomo G Baldi** conceptualization, data curation, supervision, validation, original draft



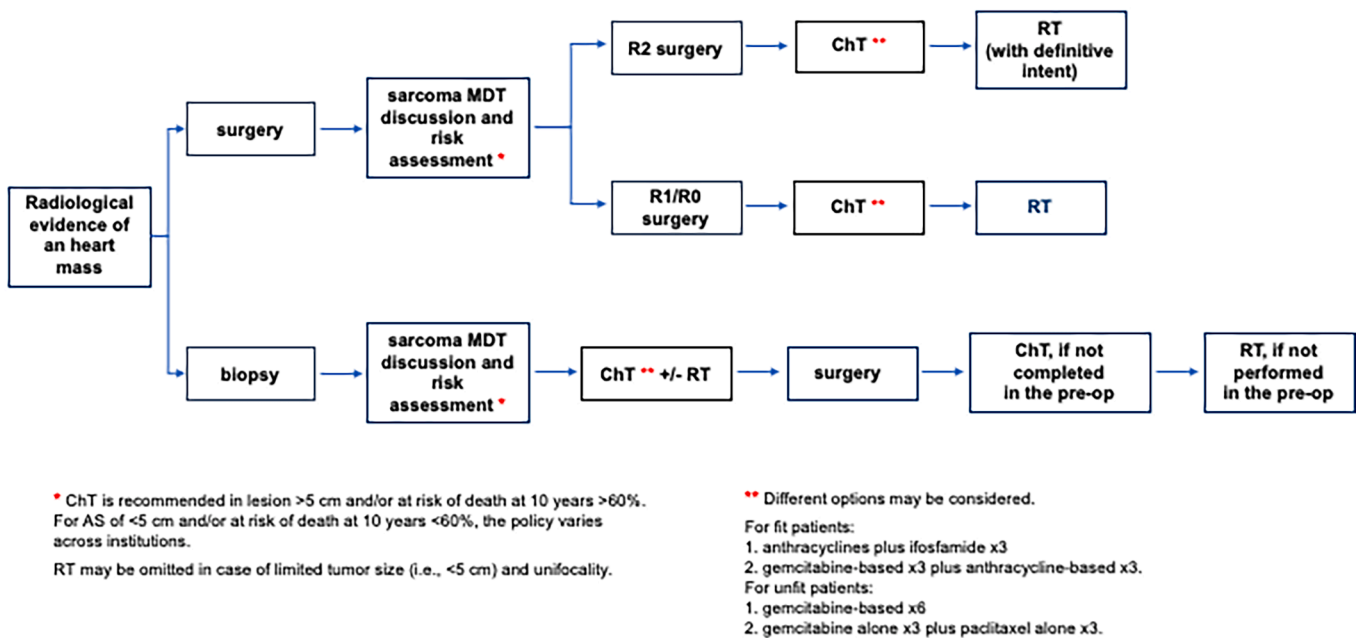
### Treatment algorithm, localized soft tissue AS



Legend: AS=angiosarcoma; MDT=multidisciplinary discussion; ChT= chemotherapy; ILP= isolated limb perfusion; RT= radiotherapy.

Fig. 3. Report the proposed treatment algorithm for localized soft tissue AS.

### Treatment algorithm, localized heart AS



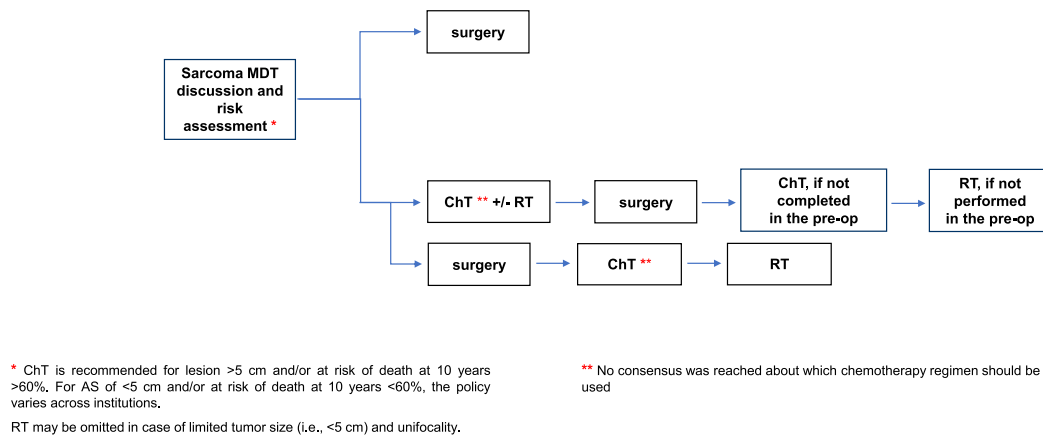
Legend: AS=angiosarcoma; MDT=multidisciplinary discussion; CT=chemotherapy; RT= radiotherapy.

Fig. 4. Report the proposed treatment algorithm for localized heart AS.

preparation, review and editing. **Sara Sulfaro** validation, review and editing. **Marta Barisella** original draft preparation, review and editing. **Giuseppe Bianchi** original draft preparation, review and editing. **Domenico Campanacci** original draft preparation, review and editing.

**Marco Fiore** original draft preparation, review and editing. **Marco Gambarotti** original draft preparation, review and editing. **Massimiliano Gennaro** original draft preparation, review and editing. **Alessandro Gronchi** original draft preparation, review and editing. **Carlo**

## Treatment algorithm, localized bone AS



Legend: AS= angiosarcoma; MTD= multidisciplinary discussion; ChT= chemotherapy; RT= radiotherapy.

Fig. 5. Report the proposed treatment algorithm for localized bone AS.

Morosi original draft preparation, review and editing. **Claudia Sangalli** original draft preparation, review and editing. Federico Navarra original draft preparation, review and editing. **Emanuela Palmerini** original draft preparation, review and editing. **Marta Sbraglia** original draft preparation, review and editing. **Annalisa Trama** original draft preparation, review and editing. **Paolo Giovanni Casali** conceptualization, data curation, supervision, validation, review and editing. **Silvia Stacchiotti** conceptualization, data curation, supervision, validation, review and editing. **All authors** validation, review and editing.

### Declaration of competing interest

The authors declare the following financial interests/personal relationships which may be considered as potential competing interests: None of the authors has any interests to report directly related to this manuscript. Outside the scope of this manuscript: **Elena Palassini**, Institutional Research Funding: Deciphera Pharmaceuticals, Blueprint Medicines, Cogent Biosciences, Amgen/Dompè, Bayer, GlaxoSmith Kline, Novartis, Pfizer, PharmaMar, Eisai, Eli Lilly, Advenchen Laboratories, Arog, Epizyme, Karyopharm Therapeutics, SpringWorks Ther, Daiichi Sankyo, Boehringer Ingelheim, Rain Therapeutics, Foghorn Ther Inc, Hutchinson MediPharam Lt, INBRX, PTC Ther. **Giacomo Giulio Baldi**, consulting fees from Eli Lilly, Pharmamar, AboutEvents; honoraria from Pharmamar, Eli Lilly, Glaxo Smith Kline, Merck Sharp & Dome, Eisai, Istituto Gentili; support for attending meetings and/or travels from Novartis, Pharmamar, Eli Lilly; participation on advisory board from Pharmamar, Eli Lilly, Glaxo Smith Kline, Merck Sharp & Dome, Eisai. **Sara Sulfaro**, **Marta Barisella**, **Giuseppe Bianchi**, **Domenico Campanacci**, **Marco Fiore**, **Marco Gambarotti**, **Massimiliano Gennaro**, **Carlo Morosi**, no conflict of interests to declare. **Federico Navarra**, travel grants from Pharmamar, Boehringer Ingelheim. **Claudia Sangalli**, advisory board from Boehringer Ingelheim, Astra Zeneca. **Rossella Bertulli**, travel grants from PharmaMar. Institutional Research Funding: Deciphera Pharmaceuticals, Blueprint Medicines, Cogent Biosciences, Amgen/Dompè, Bayer, GlaxoSmith Kline, Novartis, Pfizer, PharmaMar, Eisai, Eli Lilly, Advenchen Laboratories, Arog, Epizyme, Karyopharm Therapeutics, SpringWorks Ther, Daiichi Sankyo, Boehringer Ingelheim, Rain Therapeutics, Foghorn Ther Inc, Hutchinson MediPharam Lt, INBRX, PTC Ther. **Alexia Bertuzzi**, **Roberto Biagini**, **Angela Bonadonna**, **Antonella Brunello**, **Dario Callegaro**, no conflict of interests to declare. **Ferdinando Cananzi**, speaking fee from Istituto

Gentili. **Marco Cianchetti**, **Paola Collini**, **Daniela Comandini**, **Annalisa Curcio**, no conflict of interests to declare. **Lorenzo D'Ambrosio**, advisory board: PSI CRO Italy, GSK, AstraZeneca, Boehringer Ingelheim, Eisai. Meeting participation: GSK, AstraZeneca, PharmaMar. **Martino De Pas**, participation on advisory board from Glaxo Smith Kline, Boehringer Ingelheim. Trial support from: Pfizer, Blueprint Medicine, Gilead, Amgen, Merck. **Angelo Paolo Dei Tos**, no conflict of interests to declare. **Virginia Ferraresi**, Travel grants from PharmaMar, Gentili, Boehringer Ingelheim. Advisory Board: SERB Pharmaceuticals. **Andrea Ferrari**, **Alessandro Franchi**, no conflict of interests to declare. **Anna Maria Frezza**, Institutional Research Funding: Deciphera Pharmaceuticals, Blueprint Medicines, Cogent Biosciences, Amgen/Dompè, Bayer, GlaxoSmith Kline, Novartis, Pfizer, PharmaMar, Eisai, Eli Lilly, Advenchen Laboratories, Arog, Epizyme, Karyopharm Therapeutics, SpringWorks Ther, Daiichi Sankyo, Boehringer Ingelheim, Rain Therapeutics, Foghorn Ther Inc, Hutchinson MediPharam Lt, INBRX, PTC Ther. **Elena Fumagalli**, Advisory Board from Deciphera Pharmaceuticals. Institutional Research Funding: Deciphera Pharmaceuticals, Blueprint Medicines, Cogent Biosciences, Amgen/Dompè, Bayer, GlaxoSmith Kline, Novartis, Pfizer, PharmaMar, Eisai, Eli Lilly, Advenchen Laboratories, Arog, Epizyme, Karyopharm Therapeutics, SpringWorks Ther, Daiichi Sankyo, Boehringer Ingelheim, Rain Therapeutics, Foghorn Ther Inc, Hutchinson MediPharam Lt, INBRX, PTC Ther. **Matteo Ghilli**, **Daniela Greto**, no conflict of interests to declare. **Giovanni Grignani**, advisory board from Pharmamar, Incyte, Merck, Novartis, Deciphera, Bayer. **Michele Guida**, advisory board from Bristol Myers Squibb, Merck Sharp & Dohme, Novartis, Pierre Fabre. **Toni Ibrahim**, advisory board and consultation fees from Amgen, Glaxosmithkline, Pharmamar and Istituto Gentili. Travel grants from Istitaka Gentili and Pharmamar. **Marco Krengli**, **Roberto Luksch**, **Andrea Marrari**, **Marinella Mastore**, **Alessandra Merlini**, no conflict of interests to declare. **Giuseppe Maria Milano**, Advisory board from Bayer, GSK, SERBS Pharmaceuticals. **Piera Navarra**, **Maria Abbondanza Pantaleo**, **Antonina Parafioriti**, no conflict of interests to declare. **Iliaria Pellegrini**, Institutional Research Funding: Deciphera Pharmaceuticals, Blueprint Medicines, Cogent Biosciences, Amgen/Dompè, Bayer, GlaxoSmith Kline, Novartis, Pfizer, PharmaMar, Eisai, Eli Lilly, Advenchen Laboratories, Arog, Epizyme, Karyopharm Therapeutics, SpringWorks Ther, Daiichi Sankyo, Boehringer Ingelheim, Rain Therapeutics, Foghorn Ther Inc, Hutchinson MediPharam Lt, INBRX, PTC Ther. **Elisabetta Pennacchioli**, **Marco Rastrelli**, **Elisabetta Setola**, **Salvatore Tafuto**, **Salvatore Turano**,

**Sergio Valeri, Bruno Vincenzi, Viviana Vitolo, Andrei Ivanescu, Fiammetta Paloschi**, no conflict of interests to declare. **Paolo Giovanni Casali**, Institutional Research Funding: Deciphera Pharmaceuticals, Blueprint Medicines, Cogent Biosciences, Amgen/Dompè, Bayer, GlaxoSmith Kline, Novartis, Pfizer, PharmaMar, Eisai, Eli Lilly, Advenchen Laboratories, Arog, Epizyme, Karyopharm Therapeutics, SpringWorks Ther, Daiichi Sankyo, Boehringer Ingelheim, Rain Therapeutics, Foghorn Ther Inc, Hutchinson MediPharm Lt, INBRX, PTC Ther. **Alessandro Gronchi**, no conflict of interests to declare. **Silvia Stacchiotti**, personal financial interests (honoraria, consultancy or advisory role): Aadi, Astex Pharmaceuticals, Bavarian Nordic, Bayer, Boehringer Ingelheim, Daiichi Sankyo, Deciphera, Epizyme, Gentili, GSK, Agenus, Ikena, MaxiVAX, Novartis, PharmaMar, Pharma Essentia, Rain Therapeutics, Servier. Support for attending meetings and/or travel PharmaMar; Institutional financial interests: Advenchen, Bayer, Blueprint, Daiichi Sankyo, Deciphera, Epizyme, Eli Lilly, GSK, Hutchinson, Inhibrx, Karyopharm, Novartis, PharmaMar, Rain Therapeutics, SpringWorks; unpaid Member of the Scientific Advisory Board of the Chordoma Foundation, Member of the Scientific Advisory Board of the Desmoid Foundation, Member of the Scientific Advisory Board of the Epithelioid Hemangioendothelioma Group, Member of the Scientific Advisory Board of the Leiomyosarcoma Foundation.

## Acknowledgements

We would like to thank “Sofia nel Cuore Onlus” for their invaluable support in the consensus building and reviewing process, without which this effort would not have been possible.

## Appendix A. Supplementary data

Supplementary data to this article can be found online at <https://doi.org/10.1016/j.ctrv.2024.102722>.

## References

- de Pinieux G, Karanian M, Le Loarer F, et al. Nationwide incidence of sarcomas and connective tissue tumors of intermediate malignancy over four years using an expert pathology review network. *PLoS One* 2021;16(2):e0246958.
- Colas M, Gérazime A, Popescu D, et al. Angiosarcoma: A population-based cancer registry descriptive study of 45 consecutive cases diagnosed between 1979 and 2016. *Rare Tumors*. 2020;12:2036361320979216. 10.1177/2036361320979216.
- Bacon A, Wong K, Fernando MS, et al. Incidence and survival of soft tissue sarcoma in England between 2013 and 2017, an analysis from the National Cancer Registration and Analysis Service. *Int J Cancer* 2023;152(9):1789–803. <https://doi.org/10.1002/ijc.34409>.
- Lahat G, Dhuka AR, Halleli H, et al. Angiosarcoma: clinical and molecular insights. *Ann Surg* 2010;251(6):1098–106. <https://doi.org/10.1097/SLA.0b013e3181dbb75a>.
- Ferrari A, van Noesel MM, Brennan B, et al. Paediatric non-rhabdomyosarcoma soft tissue sarcomas: the prospective NRSTS 2005 study by the European Pediatric Soft Tissue Sarcoma Study Group (EpSSG). *Lancet Child Adolesc Health* 2021;5(8):546–58. [https://doi.org/10.1016/S2352-4642\(21\)00159-0](https://doi.org/10.1016/S2352-4642(21)00159-0).
- Ferrari A, Orbach D, Casanova M, et al. Metastatic adult-type non-rhabdomyosarcoma soft tissue sarcomas in children and adolescents: A cohort study from the European paediatric Soft tissue sarcoma Study Group. *Cancer* 2023;129(16):2542–52. <https://doi.org/10.1002/cncr.34814>.
- Ferrari A, Casanova M, Bisogno G, et al. Malignant vascular tumors in children and adolescents: a report from the Italian and German Soft Tissue Sarcoma Cooperative Group. *Med Pediatr Oncol* 2002;39(2):109–14. <https://doi.org/10.1002/mpo.10078>.
- Weidema ME, Flucke UE, van der Graaf WTA, et al. Prognostic Factors in a Large Nationwide Cohort of Histologically Confirmed Primary and Secondary Angiosarcomas. *Cancers* 2019;11(11):1780. <https://doi.org/10.3390/cancers11111780>.
- Young RJ, Brown NJ, Reed MW, Hughes D, Woll PJ. Angiosarcoma. *Lancet Oncol* 2010;11(10):983–91. [https://doi.org/10.1016/S1470-2045\(10\)70023-1](https://doi.org/10.1016/S1470-2045(10)70023-1).
- Mark RJ, Poen JC, Tran LM, Fu YS, Juillard GF. Angiosarcoma. A report of 67 patients and a review of the literature. *Cancer*. 1996;77(11):2400–2406. 10.1002/(SICI)1097-0142(19960601)77:11<2400::AID-CNCR32>3.0.CO;2-Z.
- Zhang C, Xu G, Liu Z, et al. Epidemiology, tumor characteristics and survival in patients with angiosarcoma in the United States: a population-based study of 4537 cases. *Jpn J Clin Oncol* 2019;49(12):1092–9. <https://doi.org/10.1093/jjco/hyz113>.
- Shon W, Billings SD. Cutaneous Malignant Vascular Neoplasms. *Clin Lab Med* 2017;37(3):633–46. <https://doi.org/10.1016/j.cll.2017.06.004>.
- Look Hong NJ, Pandalai PK, Hornick JL, et al. Cardiac angiosarcoma management and outcomes: 20-year single-institution experience. *Ann Surg Oncol* 2012;19(8):2707–15. <https://doi.org/10.1245/s10434-012-2334-2>.
- Fury MG, Antonescu CR, Van Zee KJ, Brennan MF, Maki RG. A 14-year retrospective review of angiosarcoma: clinical characteristics, prognostic factors, and treatment outcomes with surgery and chemotherapy. *Cancer J Sudbury Mass* 2005;11(3):241–7. <https://doi.org/10.1097/00130404-200505000-00011>.
- Fayette J, Martin E, Piperno-Neumann S, et al. Angiosarcomas, a heterogeneous group of sarcomas with specific behavior depending on primary site: a retrospective study of 161 cases. *Ann Oncol Off J Eur Soc Med Oncol* 2007;18(12):2030–6. <https://doi.org/10.1093/annonc/mdm381>.
- Lindet C, Neuville A, Penel N, et al. Localised angiosarcomas: the identification of prognostic factors and analysis of treatment impact. A retrospective analysis from the French Sarcoma Group (GSF/GETO). *Eur J Cancer Oxf Engl* 1990. 2013;49(2):369–76. <https://doi.org/10.1016/j.ejca.2012.08.016>.
- Depla AL, Scharloo-Karels CH, de Jong M, a. A., et al. Treatment and prognostic factors of radiation-associated angiosarcoma (RAAS) after primary breast cancer: a systematic review. *Eur J Cancer Oxf Engl* 1990. 2014;50(10):1779–88. <https://doi.org/10.1016/j.ejca.2014.03.002>.
- Torres KE, Ravi V, Kin K, et al. Long-term outcomes in patients with radiation-associated angiosarcomas of the breast following surgery and radiotherapy for breast cancer. *Ann Surg Oncol* 2013;20(4):1267–74. <https://doi.org/10.1245/s10434-012-2755-y>.
- D'Angelo SP, Antonescu CR, Kuk D, et al. High-risk features in radiation-associated breast angiosarcomas. *Br J Cancer* 2013;109(9):2340–6. <https://doi.org/10.1038/bjc.2013.590>.
- Cohen-Hallaleh RB, Smith HG, Smith RC, et al. Radiation induced angiosarcoma of the breast: outcomes from a retrospective case series. *Clin Sarcoma Res* 2017;7:15. <https://doi.org/10.1186/s13569-017-0081-7>.
- Mito JK, Mitra D, Barysaukas CM, et al. A Comparison of Outcomes and Prognostic Features for Radiation-Associated Angiosarcoma of the Breast and Other Radiation-Associated Sarcomas. *Int J Radiat Oncol Biol Phys* 2019;104(2):425–35. <https://doi.org/10.1016/j.ijrobp.2019.01.082>.
- Guram S, Covelli AM, O'Neill AC, et al. Multidisciplinary Intervention in Radiation-Associated Angiosarcoma of the Breast: Patterns of Recurrence and Response to Treatment. *Ann Surg Oncol* 2022;29(1):522–32. <https://doi.org/10.1245/s10434-021-10477-1>.
- Conforti F, Gronchi A, Penel N, et al. Chemotherapy in patients with localized angiosarcoma of any site: A retrospective European study. *Eur J Cancer Oxf Engl* 1990;2022(171):183–92. <https://doi.org/10.1016/j.ejca.2022.04.030>.
- Morgan MB, Swann M, Somach S, Eng W, Smoller B. Cutaneous angiosarcoma: a case series with prognostic correlation. *J Am Acad Dermatol* 2004;50(6):867–74. <https://doi.org/10.1016/j.jaad.2003.10.671>.
- Holden CA, Spittle MF, Jones EW. Angiosarcoma of the face and scalp, prognosis and treatment. *Cancer* 1987;59(5):1046–57. [https://doi.org/10.1002/1097-0142\(19870301\)59:5<1046::aid-cncr2820590533>3.0.co;2-6](https://doi.org/10.1002/1097-0142(19870301)59:5<1046::aid-cncr2820590533>3.0.co;2-6).
- Nascimento AF, Raut CP, Fletcher CDM. Primary Angiosarcoma of the Breast: Clinicopathologic Analysis of 49 Cases, Suggesting That Grade is not Prognostic. *Am J Surg Pathol* 2008;32(12):1896–904. <https://doi.org/10.1097/PAS.0b013e318176dbc7>.
- Donnell RM, Rosen PP, Lieberman PH, et al. Angiosarcoma and other vascular tumors of the breast: Pathologic analysis as a guide to prognosis. *Am J Surg Pathol* 1981;5(7):629–42. <https://doi.org/10.1097/0000478-198110000-00005>.
- Kuba MG, Dermawan JK, Xu B, et al. Histopathologic Grading Is of Prognostic Significance in Primary Angiosarcoma of Breast: Proposal of a Simplified 2-tier Grading System. *Am J Surg Pathol* 2023;47(3):307–17. <https://doi.org/10.1097/PAS.0000000000001998>.
- Manner J, Radlwiimmer B, Hohenberger P, et al. MYC high level gene amplification is a distinctive feature of angiosarcomas after irradiation or chronic lymphedema. *Am J Pathol* 2010;176(1):34–9. <https://doi.org/10.2353/ajpath.2010.090637>.
- Fernandez AP, Sun Y, Tubbs RR, Goldblum JR, Billings SD. FISH for MYC amplification and anti-MYC immunohistochemistry: useful diagnostic tools in the assessment of secondary angiosarcoma and atypical vascular proliferations. *J Cutan Pathol* 2012;39(2):234–42. <https://doi.org/10.1111/j.1600-0560.2011.01843.x>.
- Murali R, Chandramohan R, Möller I, et al. Targeted massively parallel sequencing of angiosarcomas reveals frequent activation of the mitogen activated protein kinase pathway. *Oncotarget* 2015;6(34):36041–52.
- Antonescu CR, Yoshida A, Guo T, et al. KDR activating mutations in human angiosarcomas are sensitive to specific kinase inhibitors. *Cancer Res* 2009;69(18):7175–9. <https://doi.org/10.1158/0008-5472.CAN-09-2068>.
- Huang SC, Zhang L, Sung YS, et al. Recurrent CIC Gene Abnormalities in Angiosarcomas: A Molecular Study of 120 Cases With Concurrent Investigation of PLCG1, KDR, MYC, and FLT4 Gene Alterations. *Am J Surg Pathol* 2016;40(5):645–55. <https://doi.org/10.1097/PAS.0000000000000582>.
- Rosenbaum E, Antonescu CR, Smith S, et al. Clinical, genomic, and transcriptomic correlates of response to immune checkpoint blockade-based therapy in a cohort of patients with angiosarcoma treated at a single center. *J Immunother Cancer* 2022;10(4):e004149.
- Tateishi U, Hasegawa T, Kusumoto M, et al. Metastatic angiosarcoma of the lung: spectrum of CT findings. *AJR Am J Roentgenol* 2003;180(6):1671–4. <https://doi.org/10.2214/ajr.180.6.1801671>.



- [36] Bhaludin BN, Thway K, Adejolu M, et al. Imaging features of primary sites and metastatic patterns of angiosarcoma. *Insights Imaging* 2021;12(1):189. <https://doi.org/10.1186/s13244-021-01129-9>.
- [37] Chapelier AR, Bacha EA, de Montpreville VT, et al. Radical resection of radiation-induced sarcoma of the chest wall: report of 15 cases. *Ann Thorac Surg* 1997;63(1):214–9. [https://doi.org/10.1016/s0003-4975\(96\)00927-7](https://doi.org/10.1016/s0003-4975(96)00927-7).
- [38] Scow JS, Reynolds CA, Degnim AC, Petersen IA, Jakub JW, Boughey JC. Primary and secondary angiosarcoma of the breast: the Mayo Clinic experience. *J Surg Oncol* 2010;101(5):401–7. <https://doi.org/10.1002/jso.21497>.
- [39] In't Veld EA, Grünhagen DJ, Verhoef C, H, et al. Isolated limb perfusion for locally advanced angiosarcoma in extremities: A multi-centre study. *Eur J Cancer Oxf Engl* 1990;2017(85):114–21. <https://doi.org/10.1016/j.ejca.2017.07.023>.
- [40] Palmerini E, Maki RG, Staals EL, et al. Primary angiosarcoma of bone: A retrospective analysis of 60 patients from two institutions. *Am J Clin Oncol* 2014;37(6):528–34. <https://doi.org/10.1097/COC.0b013e31827defa1>.
- [41] Malawer M, Sugarbaker PH. *Musculoskeletal Cancer Surgery: Treatment of Sarcomas and Allied Diseases*. Springer Netherlands, 2001. 10.1007/0-306-48407-2.
- [42] Gronchi A, Miah AB, Tos APD, et al. Soft tissue and visceral sarcomas: ESMO–EURACAN–GENTURIS Clinical Practice Guidelines for diagnosis, treatment and follow-up. *Ann Oncol* 2021;32(11):1348–65. <https://doi.org/10.1016/j.annonc.2021.07.006>.
- [43] Rosenberg SA, Tepper J, Glatstein E, et al. The treatment of soft-tissue sarcomas of the extremities: prospective randomized evaluations of (1) limb-sparing surgery plus radiation therapy compared with amputation and (2) the role of adjuvant chemotherapy. *Ann Surg* 1982;196(3):305–15. <https://doi.org/10.1097/0000658-198209000-00009>.
- [44] Pisters PW, Harrison LB, Leung DH, Woodruff JM, Casper ES, Brennan MF. Long-term results of a prospective randomized trial of adjuvant brachytherapy in soft tissue sarcoma. *J Clin Oncol Off J Am Soc Clin Oncol* 1996;14(3):859–68. <https://doi.org/10.1200/JCO.1996.14.3.859>.
- [45] Ward JR, Feigenberg SJ, Mendenhall NP, Marcus RB, Mendenhall WM. Radiation therapy for angiosarcoma. *Head Neck* 2003;25(10):873–8. <https://doi.org/10.1002/hed.10276>.
- [46] Guadagnolo BA, Zagars GK, Araujo D, Ravi V, Shellenberger TD, Sturgis EM. Outcomes after definitive treatment for cutaneous angiosarcoma of the face and scalp. *Head Neck* 2011;33(5):661–7. <https://doi.org/10.1002/hed.21513>.
- [47] Miki Y, Tada T, Kamo R, et al. Single institutional experience of the treatment of angiosarcoma of the face and scalp. *Br J Radiol* 2013;86(1030):20130439. <https://doi.org/10.1259/bjr.20130439>.
- [48] Suzuki G, Yamazaki H, Takenaka H, et al. Definitive Radiation Therapy for Angiosarcoma of the Face and Scalp. *Vivo Athens Greece* 2016;30(6):921–6. <https://doi.org/10.21873/invivo.11014>.
- [49] Okano N, Yumisaki H, Saito S, et al. Definitive Radiotherapy Using Electron Beam and Intensity-modulated Radiotherapy for Unresectable Angiosarcoma of the Scalp. *Anticancer Res* 2022;42(12):5991–7. <https://doi.org/10.21873/anticancer.16110>.
- [50] Sharma AM, Kowalski E, McGovern N, Zhu M, Mishra MV. Proton Versus Intensity-Modulated Radiation Therapy: First Dosimetric Comparison for Total Scalp Irradiation. *Int J Part Ther* 2020;6(3):19–26. <https://doi.org/10.14338/IJPT-19-00069.1>.
- [51] Vitolo V, Barcellini A, Mirandola A, et al. Is Proton Beam Radiotherapy Worthwhile in the Management of Angiosarcoma of the Scalp? *Anticancer Res* 2020;40(3):1645–9. <https://doi.org/10.21873/anticancer.14114>.
- [52] Gutkin PM, Ganjoo KN, Lohman M, et al. Angiosarcoma of the Breast: Management and Outcomes. *Am J Clin Oncol* 2020;43(11):820–5. <https://doi.org/10.1097/COC.0000000000000753>.
- [53] Kronenfeld JP, Crystal JS, Ryon EL, et al. Clinical Outcomes for Primary and Radiation-Associated Angiosarcoma of the Breast with Multimodal Treatment: Long-Term Survival Is Achievable. *Cancers* 2021;13(15):3814. <https://doi.org/10.3390/cancers13153814>.
- [54] Alves I, Marques JC. Radiation-induced angiosarcoma of the breast: a retrospective analysis of 15 years' experience at an oncology center. *Radiol Bras* 2018;51(5):281–6. <https://doi.org/10.1590/0100-3984.2017.0129>.
- [55] Seinen JM, Styring E, Verstappen V, et al. Radiation-associated angiosarcoma after breast cancer: high recurrence rate and poor survival despite surgical treatment with R0 resection. *Ann Surg Oncol* 2012;19(8):2700–6. <https://doi.org/10.1245/s10434-012-2310-x>.
- [56] Antman KH, Corson J, Greenberger J, Wilson R. Multimodality therapy in the management of angiosarcoma of the breast. *Cancer* 1982;50(10):2000–3. [https://doi.org/10.1002/1097-0142\(19821115\)50:10<2000::aid-cncr2820501004>3.0.co;2-u](https://doi.org/10.1002/1097-0142(19821115)50:10<2000::aid-cncr2820501004>3.0.co;2-u).
- [57] Sher T, Hennessy BT, Valero V, et al. Primary Angiosarcomas of the Breast. *Cancer* 2007;110(1):173–8. <https://doi.org/10.1002/cncr.22784>.
- [58] Notter M, Thomsen AR, Nitsche M, et al. Combined wIRA-Hyperthermia and Hypofractionated Re-Irradiation in the Treatment of Locally Recurrent Breast Cancer: Evaluation of Therapeutic Outcome Based on a Novel Size Classification. *Cancers* 2020;12(3):606. <https://doi.org/10.3390/cancers12030606>.
- [59] Würschmidt F, Dahle J, Petersen C, Wenzel C, Kretschmer M, Bastian C. Reirradiation of recurrent breast cancer with and without concurrent chemotherapy. *Radiat Oncol Lond Engl* 2008;3:28. <https://doi.org/10.1186/1748-717X-3-28>.
- [60] Merino T, Tran WT, Czarnota GJ. Re-irradiation for locally recurrent refractory breast cancer. *Oncotarget* 2015;6(33):35051–62. <https://doi.org/10.18632/oncotarget.6036>.
- [61] Müller AC, Eckert F, Heinrich V, Bamberg M, Brucker S, Hehr T. Re-surgery and chest wall re-irradiation for recurrent breast cancer: a second curative approach. *BMC Cancer* 2011;11:197. <https://doi.org/10.1186/1471-2407-11-197>.
- [62] Tommasino F, Durante M. Proton radiobiology. *Cancers* 2015;7(1):353–81. <https://doi.org/10.3390/cancers7010353>.
- [63] MacDonald SM, Patel SA, Hickey S, et al. Proton therapy for breast cancer after mastectomy: early outcomes of a prospective clinical trial. *Int J Radiat Oncol Biol Phys* 2013;86(3):484–90. <https://doi.org/10.1016/j.ijrobp.2013.01.038>.
- [64] Bradley JA, Dagan R, Ho MW, et al. Initial Report of a Prospective Dosimetric and Clinical Feasibility Trial Demonstrates the Potential of Protons to Increase the Therapeutic Ratio in Breast Cancer Compared With Photons. *Int J Radiat Oncol Biol Phys* 2016;95(1):411–21. <https://doi.org/10.1016/j.ijrobp.2015.09.018>.
- [65] Cuaron JJ, Chon B, Tsai H, et al. Early toxicity in patients treated with postoperative proton therapy for locally advanced breast cancer. *Int J Radiat Oncol Biol Phys* 2015;92(2):284–91. <https://doi.org/10.1016/j.ijrobp.2015.01.005>.
- [66] Thorpe CS, Niska JR, Girardo ME, et al. Proton beam therapy reirradiation for breast cancer: Multi-institutional prospective PCG registry analysis. *Breast J* 2019;25(6):1160–70. <https://doi.org/10.1111/tbj.13423>.
- [67] ESMO Open, 2024, in press.
- [68] Piroth MD, Baumann R, Budach W, et al. Heart toxicity from breast cancer radiotherapy. *Strahlenther Onkol* 2019;195(1):1–12. <https://doi.org/10.1007/s00066-018-1378-z>.
- [69] Randhawa JS, Budd GT, Randhawa M, et al. Primary Cardiac Sarcoma: 25-Year Cleveland Clinic Experience. *Am J Clin Oncol* 2016;39(6):593–9. <https://doi.org/10.1097/COC.0000000000001006>.
- [70] Isambert N, Ray-Coquard I, Italiano A, et al. Primary cardiac sarcomas: a retrospective study of the French Sarcoma Group. *Eur J Cancer Oxf Engl* 1990. 2014;50(1):128–36. <https://doi.org/10.1016/j.ejca.2013.09.012>.
- [71] Siontis BL, Leja M, Chugh R. Current clinical management of primary cardiac sarcoma. *Expert Rev Anticancer Ther* 2020;20(1):45–51. <https://doi.org/10.1080/14737140.2020.171738>.
- [72] Aoka Y, Kamada T, Kawana M, et al. Primary cardiac angiosarcoma treated with carbon-ion radiotherapy. *Lancet Oncol* 2004;5(10):636–8. [https://doi.org/10.1016/S1470-2045\(04\)01600-6](https://doi.org/10.1016/S1470-2045(04)01600-6).
- [73] Thariat J, Clément-Colmou K, Vugin G, et al. Radiation therapy of cardiac sarcomas. *Cancer Radiother J Soc Francaise Radiother Oncol* 2014;18(2):125–31. <https://doi.org/10.1016/j.canrad.2014.02.003>.
- [74] Palmerini E, Leithner A, Windhager R, et al. Angiosarcoma of bone: a retrospective study of the European Musculoskeletal Oncology Society (EMSOS). *Sci Rep* 2020;10(1):10853. <https://doi.org/10.1038/s41598-020-66579-5>.
- [75] Pervaiz N, Colterjohn N, Farrokhfar F, Tozer R, Figueredo A, Ghert M. A systematic meta-analysis of randomized controlled trials of adjuvant chemotherapy for localized resectable soft-tissue sarcoma. *Cancer* 2008;113(3):573–81. <https://doi.org/10.1002/cncr.23592>.
- [76] Woll PJ, Reichardt P, Le Cesne A, et al. Adjuvant chemotherapy with doxorubicin, ifosfamide, and lenograstim for resected soft-tissue sarcoma (EORTC 62931): a multicentre randomised controlled trial. *Lancet Oncol* 2012;13(10):1045–54. [https://doi.org/10.1016/S1470-2045\(12\)70346-7](https://doi.org/10.1016/S1470-2045(12)70346-7).
- [77] Frustaci S, Gherlinzoni F, De Paoli A, et al. Adjuvant chemotherapy for adult soft tissue sarcomas of the extremities and girdles: results of the Italian randomized cooperative trial. *J Clin Oncol Off J Am Soc Clin Oncol* 2001;19(5):1238–47. <https://doi.org/10.1200/JCO.2001.19.5.1238>.
- [78] Gronchi A, Stacchiotti S, Verderio P, et al. Short, full-dose adjuvant chemotherapy (CT) in high-risk adult soft tissue sarcomas (STS): long-term follow-up of a randomized clinical trial from the Italian Sarcoma Group and the Spanish Sarcoma Group. *Ann Oncol Off J Eur Soc Med Oncol* 2016;27(12):2283–8. <https://doi.org/10.1093/annonc/mdw430>.
- [79] Gronchi A, Palmerini E, Quagliuolo V, et al. Neoadjuvant Chemotherapy in High-Risk Soft Tissue Sarcomas: Final Results of a Randomized Trial From Italian (ISG), Spanish (GEIS), French (FSG), and Polish (PSG) Sarcoma Groups. *J Clin Oncol Off J Am Soc Clin Oncol* 2020;38(19):2178–86. <https://doi.org/10.1200/JCO.19.03289>.
- [80] Pasquali S, Colombo C, Pizzamiglio S, et al. High-risk soft tissue sarcomas treated with perioperative chemotherapy: Improving prognostic classification in a randomised clinical trial. *Eur J Cancer Oxf Engl* 1990;2018(93):28–36. <https://doi.org/10.1016/j.ejca.2018.01.071>.
- [81] Pasquali S, Pizzamiglio S, Touati N, et al. The impact of chemotherapy on survival of patients with extremity and trunk wall soft tissue sarcoma: revisiting the results of the EORTC-STBSG 62931 randomised trial. *Eur J Cancer Oxf Engl* 1990;2019(109):51–60. <https://doi.org/10.1016/j.ejca.2018.12.009>.
- [82] Pasquali S, Palmerini E, Quagliuolo V, et al. Neoadjuvant chemotherapy in high-risk soft tissue sarcomas: A Sarculator-based risk stratification analysis of the ISG-STBSG 1001 randomized trial. *Cancer* 2022;128(1):85–93. <https://doi.org/10.1002/cncr.33895>.
- [83] Callegaro D, Miceli R, Bonvalot S, et al. Development and external validation of two nomograms to predict overall survival and occurrence of distant metastases in adults after surgical resection of localised soft-tissue sarcomas of the extremities: a retrospective analysis. *Lancet Oncol* 2016;17(5):671–80. [https://doi.org/10.1016/S1470-2045\(16\)00010-3](https://doi.org/10.1016/S1470-2045(16)00010-3).
- [84] Stacchiotti S, Palassini E, Sanfilippo R, et al. Gemcitabine in advanced angiosarcoma: a retrospective case series analysis from the Italian Rare Cancer Network. *Ann Oncol Off J Eur Soc Med Oncol* 2012;23(2):501–8. <https://doi.org/10.1093/annonc/mdr066>.
- [85] Penel N, Bui BN, Bay JO, et al. Phase II trial of weekly paclitaxel for unresectable angiosarcoma: the ANGIOTAX Study. *J Clin Oncol Off J Am Soc Clin Oncol* 2008;26(32):5269–74. <https://doi.org/10.1200/JCO.2008.17.3146>.



- [86] Young RJ, Natukunda A, Litière S, Woll PJ, Wardelmann E, van der Graaf WTA. First-line anthracycline-based chemotherapy for angiosarcoma and other soft tissue sarcoma subtypes: pooled analysis of eleven European Organisation for Research and Treatment of Cancer Soft Tissue and Bone Sarcoma Group trials. *Eur J Cancer Oxf Engl* 1990. 2014;50(18):3178–86. <https://doi.org/10.1016/j.ejca.2014.10.004>.
- [87] Italiano A, Cioffi A, Penel N, et al. Comparison of Doxorubicin and Weekly Paclitaxel Efficacy in Metastatic Angiosarcomas. *Cancer* 2012;118:3330–6. <https://doi.org/10.1002/cncr.26599>.
- [88] Penel N, Italiano A, Ray-Coquard I, et al. Metastatic angiosarcomas: doxorubicin-based regimens, weekly paclitaxel and metastasectomy significantly improve the outcome. *Ann Oncol* 2012;23:517–23. <https://doi.org/10.1093/annonc/mdr138>.
- [89] D'Angelo SP, Munhoz RR, Kuk D, et al. Outcomes of Systemic Therapy for Patients with Metastatic Angiosarcoma. *Oncology* 2015;89(4):205–14. <https://doi.org/10.1159/000381917>.
- [90] Palassini E, Ferrari S, Verderio P, et al. Feasibility of Preoperative Chemotherapy With or Without Radiation Therapy in Localized Soft Tissue Sarcomas of Limbs and Superficial Trunk in the Italian Sarcoma Group/Grupo Español de Investigación en Sarcomas Randomized Clinical Trial: Three Versus Five Cycles of Full-Dose Epirubicin Plus Ifosfamide. *J Clin Oncol Off J Am Soc Clin Oncol* 2015;33(31):3628–34. <https://doi.org/10.1200/JCO.2015.62.9394>.