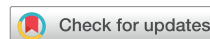

# Guidelines and Recommendations for Targeted Neonatal Echocardiography and Cardiac Point-of-Care Ultrasound in the Neonatal Intensive Care Unit: An Update from the American Society of Echocardiography



Patrick J. McNamara, MD, MSc, FASE (Chair), Amish Jain, MD, PhD, FASE, Afif El-Khuffash, MB BCh, Regan Giesinger, MD, FASE, Dany Weisz, MD, MSc, Lindsey Freud, MD, FASE, Philip T. Levy, MD, Shazia Bhombal, MD, Willem de Boode, MB BS, Tina Leone, MD, Bernadette Richards, RDCS, Yogen Singh, MB BCh, Jennifer M. Acevedo, ACS, John Simpson, MB BCh, FASE, Shahab Noori, MD, and Wyman W. Lai, MD, FASE, *Iowa City, Iowa; Toronto, Ontario, Canada; Dublin, Ireland; Boston, Massachusetts; Atlanta, Georgia; Nijmegen, the Netherlands; New York, New York; Columbus, Ohio; Loma Linda, Los Angeles, and Orange, California; Chicago, Illinois; and London, United Kingdom*

Targeted neonatal echocardiography (TNE) involves the use of comprehensive echocardiography to appraise cardiovascular physiology and neonatal hemodynamics to enhance diagnostic and therapeutic precision in the neonatal intensive care unit. Since the last publication of guidelines for TNE in 2011, the field has matured through the development of formalized neonatal hemodynamics fellowships, clinical programs, and the expansion of scientific knowledge to further enhance clinical care. The most common indications for TNE include adjudication of hemodynamic significance of a patent ductus arteriosus, evaluation of acute and chronic pulmonary hypertension, evaluation of right and left ventricular systolic and/or diastolic function, and screening for pericardial effusions and/or malpositioned central catheters. Neonatal cardiac point-of-care ultrasound (cPOCUS) is a limited cardiovascular evaluation which may include line tip evaluation, identification of pericardial effusion and differentiation of hypovolemia from severe impairment in myocardial contractility in the hemodynamically unstable neonate. This document is the product of an American Society of Echocardiography task force composed of representatives from neonatology-hemodynamics, pediatric cardiology, pediatric cardiac sonography, and neonatology-cPOCUS. This document provides (1) guidance on the purpose and rationale for both TNE and cPOCUS, (2) an overview of the components of a standard TNE and cPOCUS evaluation, (3) disease and/or clinical scenario-based indications for TNE, (4) training and competency-based evaluative requirements for both TNE and cPOCUS, and (5) components of quality assurance. (*J Am Soc Echocardiogr* 2024;37:171-215.)

The writing group would like to acknowledge the contributions of Dr. Regan Giesinger who sadly passed during the final revisions phase of these guidelines. Her contributions to the field of neonatal hemodynamics were immense.

**Keywords:** Targeted neonatal echocardiography, Neonatal hemodynamics, Point-of-care ultrasound

From the Department of Pediatrics, University of Iowa, Iowa City, Iowa (P.J.M., R.G.); the Department of Pediatrics, University of Toronto, Toronto, Ontario, Canada (A.J., D.W., L.F.); the Department of Paediatrics, Royal College of Surgeons in Ireland, Dublin, Ireland (A.E.-K.); the Division of Newborn Medicine, Boston Children's Hospital, and the Department of Pediatrics, Harvard Medical School, Boston, Massachusetts (P.T.L.); the Department of Pediatrics, Division of Neonatology, Emory University and Children's Healthcare of Atlanta, Atlanta, Georgia (S.B.); the Department of Neonatology, Radboud University Medical Center, Radboud Institute for Health Sciences, Amalia Children's Hospital, Nijmegen, the Netherlands (W.d.B.); Vagelos College of Physicians and Surgeons, Columbia University, New York, New York (T.L.); the Heart Center, Nationwide Children's Hospital, Columbus, Ohio (B.R.); Loma Linda University School of Medicine, Loma Linda, California (Y.S.); the Department of Pediatrics-Cardiology, Ann and Robert H. Lurie Children's Hospital of Chicago, Northwestern University Feinberg School of Medicine, Chicago, Illinois (J.M.A.);

the Department of Pediatrics, Evelina London Children's Hospital, London, United Kingdom (J.S.); the Fetal and Neonatal Institute, Division of Neonatology, Children's Hospital Los Angeles, Department of Pediatrics, Keck School of Medicine, University of Southern California, Los Angeles, California (S.N.); CHOC Children's Hospital, Orange, California (W.W.L.); and the University of California, Irvine, Orange, California (W.W.L.).

Reprint requests: American Society of Echocardiography, Meridian Corporate Center, 2530 Meridian Parkway, Suite 450, Durham, NC 27713 (E-mail: [ase@asecho.org](mailto:ase@asecho.org)).

0894-7317/\$36.00

Copyright 2023 Published by Elsevier Inc. on behalf of the American Society of Echocardiography.

<https://doi.org/10.1016/j.echo.2023.11.016>

**TABLE OF CONTENTS**

Background and Rationale for Targeted Neonatal Echocardiography	172
Background	172
Rationale for TNE in the NICU	172
Neonatal Cardiovascular Physiology for the Hemodynamics Consultant	173
Indications for TNE in NICUs	173
Indications for cPOCUS in the NICU	174
TNE: Practical Aspects	174
Elements of Standard TNE	174
Advanced Imaging and Measurements	177
Research Tools and Emerging Measurements	183
The First Complete Echocardiogram	183
The cPOCUS Evaluation	185
TNE: Application of Imaging	185
Disease-Based Screening	185
Clinical Scenario–Based Screening	196
TNE: Training and Accreditation	201
Previously Published Guidelines for Training in TNE	201
Knowledge Elements and Competencies for Clinical Practice in TNE	204
Proposed Training and Evaluation in TNE	204
Training and Evaluation in Neonatal Hemodynamics	205
Practice Eligibility Route for Neonatologists With TNE Expertise	206
Requirements for Training Programs in TNE and Neonatal Hemodynamics	206
cPOCUS: Training Recommendations	207
Quality Assurance for TNE and cPOCUS	207
Program Establishment	208
Conclusion	208
Notice and Disclaimer	209

**BACKGROUND AND RATIONALE FOR TARGETED NEONATAL ECHOCARDIOGRAPHY****Background**

Limitations in the clinical evaluation of the adequacy of circulatory function in neonates have long been recognized, especially for preterm neonates. These limitations have led to the increased use of bedside echocardiography by neonatal clinicians to assess the hemodynamic phenotype and cardiac function, especially in the past decade.<sup>1</sup> Globally, more neonatal intensive care units (NICUs) have established formal programs to incorporate echocardiography in the diagnosis and management of critically ill neonates.<sup>2,3</sup> Recognition of the importance of comprehensive training, including high-quality echocardiography skills, has culminated in the development of formal, 1 year subspecialty fellowship training programs in neonatal hemodynamics at centers in the United States and Canada over the past decade.

*Functional echocardiography* was the first term used to describe neonatologist-performed imaging assessments<sup>4</sup> to distinguish it from primarily anatomy-focused echocardiography performed by a cardiology service. However, over the past decade, different terms, such as *neonatologist-performed echocardiography* (NPE)<sup>5,6</sup> and *clinician-performed ultrasound*,<sup>7</sup> have been used interchangeably. In this article, we use the term *targeted neonatal echocardiography* (TNE), as proposed by the writing group of the American Society of Echocardiography (ASE) in 2011.<sup>8</sup> TNE involves the use of echocardiography for neonates with hemodynamic perturbation, where clinical suspicion for major structural defects is low, performed by, or under direct supervision of, and interpreted by a trained neonatolo-

gist and which involves comprehensive multimodal assessment of cardiac function and hemodynamics. Since the initial guideline published in 2011, the pool of neonatologists with expertise in TNE has increased substantially, aided by highly successful formal subspecialty neonatal hemodynamic fellowship programs, facilitating skill dissemination. In addition, scientific literature on the implementation of the TNE program has emerged.<sup>9,10</sup> Normative data for standard echocardiography indices for preterm and term infants have expanded, and newer methods for cardiac function assessment have been introduced. Finally, the development of neonatal echocardiography simulation models in the past decade has prompted calls for its use to support training in basic echocardiographic views and to identify structural abnormalities.<sup>6,11,12</sup> These developments, catalyzed by the first edition of the TNE guideline 2011, have motivated the need to reconvene an expert panel to update and revise the guidelines incorporating scientific progress, and make them more relevant to contemporary neonatal practice. This article replaces the 2011 TNE guideline and has been expanded to provide recommendations for cardiac point-of-care ultrasound (cPOCUS). cPOCUS in neonatology is not yet well defined, and there is significant overlap with TNE in scope<sup>13</sup>; in general, cPOCUS is a brief, qualitative, and less comprehensive assessment of cardiac function, indwelling arterial or venous catheters and life-threatening pericardial effusions.<sup>14</sup> The recently published ASE recommendations for cPOCUS provide a framework for imaging and practice, although neonates were not included.<sup>15</sup>

**Rationale for TNE in the NICU**

Longitudinal appraisal of cardiovascular status to maintain effective delivery of oxygen and nutrients and removal of carbon dioxide and waste products is pivotal for optimal organ function. The reliability of clinical indices of systemic perfusion, such as heart rate, blood pressure (BP), capillary refill time, urine output, lactate, and capillary refill time, is questionable.<sup>16–18</sup> Echocardiography estimation of cardiac output (left ventricular [LV] and right ventricular [RV] output) is feasible. Older pediatric echocardiography studies reported variable precision with discordance rates of  $\pm 30\%$ . More recent neonatal comparative evaluations with magnetic resonance imaging–derived estimates of cardiac output showed higher correlation because of increased assessment and measurement rigor.<sup>19,20</sup>

The use of TNE in the setting of a hemodynamic consultation results in modification of management strategies in almost 40% of cases; of note, the reported number is  $>80\%$  for critical illnesses such as acute pulmonary hypertension (PH) and systemic hypotension or shock.<sup>9,21,22</sup> In preterm infants with patent ductus arteriosus (PDA), TNE is commonly used to better adjudicate those shunts which are hemodynamically significant and therefore predictive of adverse clinical outcomes.<sup>23,24</sup> In addition, it is used to adjust the duration of pharmacologic treatment,<sup>25–27</sup> and to select patients for and prevent clinical instability after interventional closure (transcatheter device closure or surgical ligation).<sup>28,29</sup> Moreover, timely availability of TNE in NICUs may allow emergent diagnosis and treatment of life-threatening complications such as cardiac tamponade, reveal incidental but highly relevant findings such as malpositioned central venous catheters, and identify structural heart defects.<sup>30</sup> Comprehensive hemodynamic evaluation including TNE may result in faster clinical recovery in preterm infants with compromised systemic perfusion.<sup>31,32</sup> In addition, TNE is used to assess the severity of pulmonary vascular disease, transuductal and interatrial shunting, and myocardial performance during episodic acute PH<sup>33</sup> and may aid in risk stratification by identifying patients at highest risk for mortality or need for extracorporeal membrane oxygenation

### Abbreviations

<b>ASE</b> = American Society of Echocardiography
<b>BP</b> = Blood pressure
<b>BPD</b> = Bronchopulmonary dysplasia
<b>CDH</b> = Congenital diaphragmatic hernia
<b>CHD</b> = Congenital heart disease
<b>cPOCUS</b> = Cardiac point-of-care ultrasound
<b>DS</b> = Down syndrome
<b>ECMO</b> = Extracorporeal membrane oxygenation
<b>EF</b> = Ejection fraction
<b>EI</b> = Eccentricity index
<b>FAC</b> = Fractional area change
<b>HIE</b> = Hypoxic-ischemic encephalopathy
<b>IDM</b> = Infant of diabetic mother
<b>IVCT</b> = Isovolumetric contraction time
<b>IVRT</b> = Isovolumetric relaxation time
<b>LA</b> = Left atrial
<b>LV</b> = Left ventricular
<b>LVEF</b> = Left ventricular ejection fraction
<b>LVO</b> = Left ventricular output
<b>MV</b> = Mitral valve
<b>NHTNE</b> = Neonatal hemodynamics and targeted neonatal echocardiography
<b>NICU</b> = Neonatal intensive care unit
<b>NPE</b> = Neonatologist-performed echocardiography
<b>PA</b> = Pulmonary artery
<b>PAAT</b> = Pulmonary artery acceleration time
<b>PAP</b> = Pulmonary artery pressure
<b>PDA</b> = Patent ductus arteriosus
<b>PH</b> = Pulmonary hypertension
<b>PI</b> = Pulmonary insufficiency

(ECMO).<sup>34-37</sup> Moreover, TNE may provide information to guide more precise use of pulmonary vasodilator therapies during acute severe hypoxemia and enhanced evaluation of treatment response.<sup>38-40</sup> There is increased evidence that TNE-guided care enables earlier detection and delineation of cardiovascular compromise and supports patient-tailored, physiology-based hemodynamic management and monitoring. In summary, TNE is a useful clinical adjunct to aid neonatal cardiovascular assessment on the basis of a growing recognition that it can provide hemodynamic information that either complements what is clinically suspected or provides novel physiologic insight.<sup>41</sup> The integration of echocardiography derived hemodynamic information, relevant to an individual situation and directed by a specific clinical question, offers a blueprint from which to formulate a physiology-based diagnostic impression, upon which cardiovascular support is based, and evaluate the response to therapeutic intervention.<sup>42</sup>

### Neonatal Cardiovascular Physiology for the Hemodynamics Consultant

Neonates navigate complex cardiopulmonary sequences to transition from fetal to postnatal circulation, including sudden changes in lung volume and compliance, cardiac loading conditions and shunt physiology.<sup>43</sup> Pulmonary vasodilation is further regulated by alveolar recruitment, lower carbon dioxide tension, increase in oxygen tension, surge of vasodilator prostaglandins, and release of endogenous nitric oxide from endothelium.<sup>44</sup> The rise in systemic vascular resistance is aggravated by cold stress encountered after birth and a surge in endogenous vasoconstrictor substances during labor. Alterations in flow across intra- and extracardiac fetal shunts (e.g., ductus venosus, for-

<b>PICC</b> = Peripherally inserted central catheter
<b>POCUS</b> = Point-of-care ultrasound
<b>PVR</b> = Pulmonary vascular resistance
<b>RV</b> = Right ventricular
<b>RVET</b> = Right ventricular ejection time
<b>RVO</b> = Right ventricular output
<b>RVSP</b> = Right ventricular systolic pressure
<b>SBF</b> = Systemic blood flow
<b>SLPCV</b> = Selective laser photocoagulation of the communicating vessels
<b>STE</b> = Speckle-tracking echocardiography
<b>TAPSE</b> = Tricuspid annular plane systolic excursion
<b>TNE</b> = Targeted neonatal echocardiography
<b>TR</b> = Tricuspid regurgitation
<b>TTTS</b> = Twin-to-twin transfusion syndrome
<b>UVC</b> = Umbilical venous catheter

men ovale and PDA) are key physiologic determinants of extrauterine transition.<sup>43</sup> As pulmonary vascular resistance (PVR) falls secondary to lung expansion, flow across the PDA reverses, thereby increasing pulmonary blood flow which in turn exerts shear force on the pulmonary vascular endothelium. These changes prompt a switch from production of vasoconstrictor mediators to vasodilators, leading to a further drop in PVR. The direction of flow across the PDA becomes increasingly left to right. The postnatal rise in lung perfusion and elevation of oxygen saturation, in combination with an increase in bradykinins and decrease in prostaglandin levels promotes constriction of vascular smooth muscles in the ductus arteriosus.<sup>45</sup> Functional closure occurs within the first 48 hours for term-born infants, while anatomic closure is typically completed within 14 to 21 days. The higher pulmonary blood flow from increased RV output (RVO) and the left-to-right PDA shunt leads to an increase in pulmonary venous return and elevated left atrial (LA) pressure,

causing displacement of the flap of the foramen ovale over the rims of the fossa, limiting flow. Knowledge of these physiologic changes and their timing is crucial to enable proper interpretation and integration of the hemodynamic information obtained using TNE, especially during the perinatal period.

The transition from fetal to postnatal life is more complex in preterm infants with increased risk for hemodynamic compromise.<sup>42</sup> The potential determinants include immaturity of the myocardium, persistence of fetal shunts, inherently smaller pulmonary vascular capacity or adverse cardiovascular effects of lung disease and related ventilation strategies, and differential cytokine and/or pharmacologic responsiveness.<sup>43</sup> The preterm myocardium is composed of underdeveloped contractile mechanisms with disorganized myofibrils, immature calcium handling system, and inadequately compliant collagen, all contributing to a myocardium with relatively reduced diastolic performance and compliance, even more intolerant to an abrupt increase in afterload (e.g., following removal of the placenta), and lack of reserve to cope with reduced preload.<sup>46</sup> The delay in physiologic drop in PVR secondary to lung disease coupled with the failure to increase cardiac outputs and persistence of fetal shunts can contribute to a maladaptive transition.<sup>47</sup>

### Indications for TNE in NICUs

Several reports published over the past 10 years have highlighted the typical indications where TNE has been used by clinicians in tertiary

NICUs. Although these indications are often described in terms of suspected pathologies, the decision to perform TNE is usually based on the interpretation of presenting symptoms. The typical pathologies and their suggestive symptoms which may prompt a hemodynamic evaluation with the use of TNE in neonates, as well as specific goals of such an evaluation are listed in [Table 1](#). It is important to note that if the presenting symptoms are suspicious of critical congenital heart disease (CHD), or in conditions with known association with CHD (e.g., congenital diaphragmatic hernia [CDH], trisomy 21), patients must also receive a comprehensive echocardiogram that is reviewed by a pediatric cardiologist in a timely fashion. In addition, if neonatologist-performed TNE is the first patient evaluation, the study protocol should include the acquisition of images and views to confirm normal cardiac structure and connections. If deviations from normal are recognized, then timely review by a pediatric cardiologist is warranted.

### Indications for cPOCUS in the NICU

cPOCUS is a brief bedside ultrasound examination of the heart limited in its scope to specific clinical question. Point-of-care ultrasound (POCUS) is used for evaluations of other organ systems or as an aid during invasive procedures.<sup>48</sup> Although some clinicians who perform cPOCUS may also be trained in TNE, others may have less comprehensive training focused solely on the scope within POCUS. However, it is critical for all clinicians using ultrasound to know and practice within the scope and limitations of their own training and to seek support from more experienced operators when needed. In older children and adults, the use of focused cardiac ultrasound in the emergency departments or intensive care units has become common and is used for a quick adjunctive evaluation in clinical scenarios such as hypovolemia, hypotension, low-cardiac output states, effusions, sepsis, and coronary conditions.<sup>49,50</sup> In neonates, however, the potential for encountering undiagnosed critical CHD and/or complex cardiopulmonary hemodynamic physiologic states inherently complicates the practice and scope of limited imaging modalities, needing detailed TNE assessments and experienced operators to interpret the physiologic impact of findings. [Table 2](#) describes the potential clinical uses of a cPOCUS examination that may aid clinical decisions in a time-sensitive manner and the associated pitfalls for operators to consider. Extreme caution is recommended in practice of qualitative appraisal of heart function in symptomatic infants, particularly during the early transition because of the need to confirm normal cardiac anatomy. In addition, cPOCUS should not be used as a screening tool to detect CHD; however, deviations from normal anatomy detected or suspected during a cPOCUS assessment should prompt referral to a pediatric cardiologist. It is thus strongly recommended to obtain early definitive imaging (pediatric echocardiography or standard TNE), wherever feasible, particularly when patient symptoms remain unresolved despite cPOCUS-guided management. It is therefore necessary for clinicians performing ultrasound to use their skills with caution and for institutions to define the scope of performance and degree of oversight.

## TNE: PRACTICAL ASPECTS

### Elements of Standard TNE

All TNE evaluations must be comprehensive because unexpected physiologic findings which may modify clinical decisions are not uncommon. In addition, qualitative evaluation of cardiac function

should be limited to critical emergencies given the limited ability to detect mild or moderate disease and change over time. The following section describes the images and measurements that should be performed in all standard TNE examinations ([Table 3](#)).

**LV Systolic Function.** There are three potential methods of measuring LV ejection fraction (LVEF) which are influenced by geometric assumptions regarding the shape of the left ventricle. LVEF using M-mode imaging, which assumes that the left ventricle is circular in cross-section, is the least recommended because of the inaccuracy of its geometric assumptions, among other things. The area-length, or hemicylindrical hemiellipsoid model, assumes that the ventricular base is a cylinder, and the apex is ellipsoid ([Table 3](#), [Figure 1](#)). In contrast, the Simpson biplane method assumes the left ventricle to be conical; therefore, circular in cross-section ([Table 3](#), [Figure 2](#)). For both area-length and Simpson measurements, the tracing should occur at the endocardial-blood pool interface which typically has a smooth, regular contour, and should include adjacent structures (e.g., papillary muscles) as within the cavity. In the transitional period, when right-heart pressures are elevated (sometimes suprasystemic), these assumptions may be less applicable. For optimal image acquisition the LV apex should move minimally between end-diastole and end-systole. Significant basal displacement of the apex during systole suggests image foreshortening. Normal ejection fraction (EF) is considered 55% to 70%. Fractional shortening, like LVEF by M-mode imaging, is commonly used but has several limitations. First, it assumes that the region sampled at the tips of the mitral valve (MV) leaflets is representative of global LV systolic function. Second, in the setting of septal flattening the assumption that the left ventricle is circular may lead to significant inaccuracy in fractional shortening. The normal range is considered 30% to 45% ([Table 3](#), [Figure 3](#)).

### Recommendation

LVEF should be measured using either the area-length or Simpson biplane method.

**LV Diastolic Function and LA Loading.** Pulsed-wave Doppler measurements may provide insights regarding the relative pressure differences between the left atrium and left ventricle, and left heart filling. The peak velocity in the pulmonary vein may be low in the setting of PH and low pulmonary blood flow or high with a prominent diastolic wave in the setting of high-volume PDA shunt ([Table 3](#), [Figure 4](#)). A-wave reversal in the pulmonary vein may be a normal variant; however, in combination with other markers of LV diastolic dysfunction the duration and magnitude of the pulmonary vein A wave (in relation to the transmitral valve A wave) may be a marker of poor LV compliance resulting in backflow into the pulmonary veins during the atrial phase. Most normal term and preterm infants have a MV E/A ratio of <1 because of developmentally appropriate altered ventricular compliance ([Table 3](#), [Figure 5](#)). Because the velocity of early (mitral E) flow is determined by the pressure gradient between chambers, high MV E velocity (or MV E > A), may indicate a pressure- or volume-loaded left atrium. Similarly, in mature neonates a low E wave velocity may suggest impaired ventricular elastance. Isovolumetric relaxation time (IVRT) is determined by the pressure gradient between chambers and is mostly used to estimate the relative time it takes for pressure to build up in the left atrium sufficient to overcome LV pressure, thus opening the MV and initiating ventricular filling ([Table 3](#), [Figure 6](#)). Shorter IVRT suggests either high LA pressure (e.g., hemodynamically significant PDA) or high LV elastance and vice versa. LA dilation may be seen in the setting of LA volume

**Table 1** Typical pathologies and associated symptoms that may prompt hemodynamic evaluation of patients using targeted neonatal echocardiography in NICUs

Pathologies	Suggestive clinical concerns	Specific goals
PDA in premature neonates	<ul style="list-style-type: none"> <li>• Murmur</li> <li>• Bounding pulses, active precordium</li> <li>• Wide pulse pressure</li> <li>• Hypotension and/or metabolic acidosis during transition</li> <li>• Worsening ventilation and efficacy of oxygenation</li> <li>• Pulmonary hemorrhage</li> <li>• Screening to detect clinically silent large PDA in high-risk patients (&lt;27 wk gestational age)</li> </ul>	<ol style="list-style-type: none"> <li>i. Confirm diagnosis</li> <li>ii. Evaluate PDA size, shunt direction, and flow pattern</li> <li>iii. Evaluate signs of shunt magnitude</li> </ol>
Low SBF states during transition in premature neonates	<ul style="list-style-type: none"> <li>• Metabolic acidosis</li> <li>• Elevated lactate</li> <li>• Poor urinary output</li> <li>• Hypotension</li> <li>• Low cerebral oxygen saturation (near-infrared spectroscopy)</li> </ul>	Evaluate ventricular volumes, systolic performance, and outputs
Acute PH	<ul style="list-style-type: none"> <li>• Acute hypoxic respiratory failure despite adequate ventilation</li> <li>• Preductal oxygen saturation (SpO<sub>2</sub>) ≥ 7%-10% vs postductal</li> </ul>	<ol style="list-style-type: none"> <li>i. Confirm diagnosis and establish disease severity</li> <li>ii. Ventricular function and outputs</li> <li>iii. Shunt presence and flow characteristics</li> <li>iv. Sequential assessments to monitor progression</li> </ol>
Shock	<ul style="list-style-type: none"> <li>• Hypotension</li> <li>• Metabolic acidosis</li> <li>• Lactic acidosis</li> <li>• Oliguria</li> <li>• Hypotension (warm shock) or hypertension (cold shock)</li> <li>• Prolonged capillary refill time</li> </ul>	Evaluate ventricular volumes, systolic performance, and outputs
Infants with perinatal asphyxia	<ul style="list-style-type: none"> <li>• Early routine evaluation in infants with evidence of significant perinatal insult</li> <li>• High cardiac troponin</li> <li>• Signs of shock and/or acute PH</li> <li>• Low cerebral oxygen saturation</li> </ul>	<ol style="list-style-type: none"> <li>i. Evaluate biventricular systolic performance and outputs</li> <li>ii. As for shock and acute PH, when relevant</li> </ol>
Chronic PH	<ul style="list-style-type: none"> <li>• Routine evaluation in at-risk preterm neonates at 36 wk postmenstrual age: moderate to severe chronic lung disease, small for gestational age, previous history of acute PH, oligohydramnios</li> <li>• Preterm neonates with moderate to severe chronic lung disease demonstrating signs suggestive of significant pulmonary vascular disease: frequent hypoxemic episodes, unexpected worsening, or lack of expected improvement in respiratory course</li> </ul>	<ol style="list-style-type: none"> <li>i. Confirm diagnosis and establish severity</li> <li>ii. Evaluate RV size and systolic function</li> <li>iii. Evaluate for presence of left-to-right shunts</li> <li>iv. Rule out pulmonary vein disease/stenosis</li> </ol>
CDH	<ul style="list-style-type: none"> <li>• Acute hypoxic respiratory failure despite adequate ventilation</li> <li>• Routine early evaluation recommended to define normal anatomy and differentiate PA hypertension vs LV phenotype</li> </ul>	<ol style="list-style-type: none"> <li>i. Evaluate biventricular systolic performance and outputs</li> <li>ii. Assess PA vs venous hypertension</li> <li>iii. Assess severity of PA hypertension</li> </ol>
Pericardial/pleural effusion	<ul style="list-style-type: none"> <li>• Sudden unexpected cardiorespiratory deterioration in neonates with a central venous catheter in situ</li> </ul>	Confirm or rule out diagnosis.

loading (e.g., hemodynamically significant PDA) or pressure loading (e.g., high LV end-diastolic pressure due to diastolic dysfunction). It is conventional to use a ratio of LA to aortic root dimensions to quantify this, although LA volume has been used in some studies; however, neither has been validated with gold standard measures of cardiac volumes in neonates (Table 3, Figure 7).

### Recommendation

All standard TNE studies should consider including transmitral flow (E/A ratio, IVRT) and a measure of LA size. Measurement of pulmonary vein velocities may be considered.

**Systemic Blood Flow.** In the absence of shunts, systemic blood flow (SBF) can be calculated using the elements of the formula for LV output (LVO) (Table 3, Figure 8). To optimize the accuracy of the measurement it is essential that the angle of insonation with the aortic flow be as close to zero as possible and definitely  $<20^\circ$ . In addition, sample volume position should bisect the hinge point of the aortic valve and measurement of the LV outflow tract diameter should be at precisely the same anatomic location to ensure consistency with longitudinal assessments. In the setting of a hemodynamically significant PDA, where LVO is no longer a reliable estimate of SBF, surrogate measurements may be useful. Diastolic flow reversal in the descending aorta was the best predictor of cardiac magnetic resonance imaging derived estimates of PDA shunt volume. Conventional markers such as PDA diameter or left atrium/aortic root ratio performed poorly<sup>56</sup> (Table 3, Figure 9). Reversal of diastolic flow in the celiac artery, superior mesenteric artery and, less commonly, middle cerebral artery, which should have forward flow throughout diastole, are also associated with hemodynamic significance (Table 3, Figure 10). Absence of reversal should be interpreted with caution, particularly when end-organ pathology is present as diastolic flow may also be influenced by organ resistance.

### Recommendation

LVO should be routinely measured. Imaging to determine the diastolic flow direction centrally (descending aorta) and peripherally (celiac artery, superior mesenteric artery, middle cerebral artery) should be performed where ductal shunt significance is in question.

**RV Systolic Function.** Subjective assessment, although common, is not recommended because of limited sensitivity, particularly for mild and moderate disease.<sup>55</sup> Because of the geometric limitations imposed by the conformation of the right ventricle, volume estimation is not possible with two-dimensional echocardiography. As a result, surrogate markers of EF are used. Fractional area change (FAC) (Table 3, Figure 11) may be measured in either the RV-focused four-chamber or RV three-chamber views, although there is evidence of superior reproducibility for the RV three-chamber view.<sup>57</sup> In adults, the RV-focused four-chamber correlates well with cardiac magnetic resonance imaging-derived EF. For both views, identification of the endocardial-blood pool interface may be challenging because of trabeculations or papillary muscles, however, the interface may be identified by its smooth contour. Tricuspid annular plane systolic excursion (TAPSE) is a measure of longitudinal function that reflects RV EF<sup>58</sup> and for which normative data have been established across most gestational age categories<sup>57,59</sup> (Table 3, Figure 12). In addition, thresholds associated with poor prognosis

are established in some populations of term neonates (e.g., PH, hypoxic-ischemic encephalopathy [HIE]).<sup>35,60</sup>

RVO is calculated using either the short- or long-axis plane; however, both the velocity time integral and annulus should be measured in the same plane due to possible variations in annulus shape. Like LVO, the angle of insonation should be minimized and the sample volume should bisect the hinge point of the pulmonary valve (Table 3, Figure 13). Measurement of the pulmonary artery (PA) annulus should be at precisely the same anatomic location where the sample volume is placed to ensure consistency with longitudinal assessments. Branch PA flow should be measured to screen for branch PA stenosis which may interfere with the reliability of the estimate of RVO. RV diastolic function may be evaluated using tricuspid valve E/A ratio or Doppler tissue imaging, but normative data are limited.

### Recommendation

Objective measurement of RV systolic function including TAPSE, RV FAC, and RVO should be performed.

**Pulmonary Hemodynamics.** Assessment of mean PA pressure (PAP) is based on the use of the modified Bernoulli equation to estimate either the mean PAP obtained from the peak velocity of a complete jet of pulmonary insufficiency (PI) according to the calculation  $\text{mean PAP} = 1/3 \text{ RV systolic pressure (RVSP)} + 2/3 \text{ PA diastolic pressure or RVSP}$  (obtained from the peak velocity of a complete tricuspid regurgitant jet according to the equation  $\text{RVSP} = 4 \times \text{tricuspid regurgitation (TR) } V_{\text{max}}^2 + \text{estimated right atrial pressure}$ ) (Table 3, Figures 14 and 15). It is essential that the line of insonation be parallel to the direction of the jet. It is also important to note that absence of TR or PI does not imply normal PAP. Also, in the setting of RV systolic dysfunction TR-derived estimates of RVSP may be lower than would be expected in the setting of normal RV function for the degree of altered pulmonary hemodynamics.

PDA shunt direction, if present, provides a reliable indicator of the relative pressure between the systemic and pulmonary vascular beds at the level of the great vessels. Of note, eccentricity index (EI) may be used to quantify RV pressure loading. Systolic EI is a ratio of the mid-septum to the posterior wall diameter to the perpendicular diameter, parallel to the septal wall at the midpoint of the cavity (Table 3, Figure 16). As the left ventricle is expected to be round, a normal systolic EI is equal to 1, or a circular LV cross-section.<sup>61</sup> Subjective evaluation of septal flattening is unreliable, especially for mild to moderate disease,<sup>55</sup> so objective evaluation is recommended.

Assessment of PVR may be a useful adjunct in determining whether elevation in PAP relates to pulmonary vascular disease.<sup>62</sup> Because blood accelerates and reaches a maximum velocity more quickly in a rigid circuit the relationship of PA acceleration time (PAAT) to total RV ejection time (RVET) may be used as an indexed surrogate measure of PVR (the so-called PVR index) (Table 3, Figure 17). A ratio of PAAT to RVET  $< 0.25$  (some centers may use the inverse RVET/PAAT  $> 4.0$  which is more intuitive to parallel the directionality of changes in the index with changes in PVR) is suggestive of elevated PVR.<sup>57</sup> The presence of notching of PA flow, similarly, reflects poor compliance in the pulmonary vascular bed and may be useful.

### Recommendation

All standard TNE studies should include continuous-wave Doppler of any TR and/or PI jet, systolic EI, and evaluation of PA Doppler waveform for PVR index and the presence of notching.

**Table 2** Typical indications for which a limited focused evaluation using cPOCUS may aid clinical decisions in NICUs

Indication	Potential impact on decision-making	Pitfalls
Central catheter tip location	<ul style="list-style-type: none"> <li>• Ensure tip is central and not too deep in RA or beyond and assist repositioning in real time</li> <li>• Ensure UVC not intrahepatic, avoiding delay in diagnosis and need for repeated radiography</li> </ul>	<ul style="list-style-type: none"> <li>• Actual catheter tip may be difficult to identify in neonates</li> <li>• Artifacts can be mistaken for catheter</li> </ul>
Identification of effusions <ul style="list-style-type: none"> <li>• Sudden onset of shock (central line complication)</li> <li>• Aiding management of fetal hydrops at birth</li> </ul>	<ul style="list-style-type: none"> <li>• Immediate identification or exclusion of pericardial/pleural effusion as a cause of shock, assist in institution of specific treatments (e.g., discontinue infusion, emergency pericardiocentesis or pleurocentesis, as needed)</li> <li>• Identify compartment with most urgent need for drainage in newborn with multiple effusions to aid resuscitation efforts</li> </ul>	<ul style="list-style-type: none"> <li>• Must have knowledge about how to best drain pockets of fluid in different locations</li> </ul>
Suspected hypovolemia	<ul style="list-style-type: none"> <li>• Qualitative identification of underfilled cardiac chambers may guide volume resuscitation</li> <li>• May assist in decisions to alter ventilator strategies if affecting venous return</li> </ul>	<ul style="list-style-type: none"> <li>• Fetal shunts may complicate assessment of volume status</li> <li>• Relationship of IVC diameter and collapsibility and volume changes not well established in neonates, particularly with invasive ventilation</li> </ul>
Suspected underperfused states <ul style="list-style-type: none"> <li>• Hypotension</li> <li>• Lactic acidosis</li> <li>• Metabolic acidosis</li> </ul>	<ul style="list-style-type: none"> <li>• Qualitative findings such as grossly impaired myocardial systolic performance, hypercontractile myocardial function (e.g., vasodilatory physiology in sepsis) may aid clinical decisions (e.g., alter ventilator strategies, inotrope vs vasopressor and dose titration). LV fractional shortening may be taught at some centers.</li> </ul>	<ul style="list-style-type: none"> <li>• Scope limited by need to confirm normal cardiac anatomy, particularly for first few weeks of age</li> <li>• TNE required to delineate specific pathophysiology, interplay between pulmonary and systemic hemodynamics and shunts</li> </ul>

IVC, Inferior vena cava; RA, right atrium.

**Shunts.** An in-depth discussion on the evaluation of hemodynamic significance of the PDA will follow in Section 3. When measuring diameter, it is important to note (particularly after treatment) that there are differences in transductal size depending on the plane of insonation. A sweep from the aortic arch to the branch PAs from a high parasternal view has the greatest potential of demonstrating entire PDA length (Table 3, Figure 18). Left-to-right flow is exclusively from the aorta to the PA and right-to-left flow is the opposite (exclusively from PA to aorta). When there is bidirectional flow, flow should be further qualified as mostly left to right or right to left. PAP may be considered suprasystemic if  $\geq 60\%$  of transductal systolic flow is right to left<sup>63</sup> (Table 3, Figure 19). Branch PA diastolic velocity may be measured as an alternative marker of ductal shunt<sup>56</sup> (Table 3, Figure 20). Atrial communications are very common in the neonatal period and their size and shunt direction are optimally viewed from the subcostal window. Assessment of atrial shunt direction using pulsed-wave Doppler may be challenging because of frequent movement of the atrial septum.<sup>64</sup> It is also important to note that the atrial jet may be eccentric and, when directed toward the ostium of the superior vena cava, may appear blue on color Doppler but still reflect left-to-right flow. Atrial shunt direction is primarily reflective of atrial and ventricular compliance and should not be used independently to adjudicate pulmonary pressure relative to systemic.<sup>64</sup>

### Recommendation

All standard TNE should include an assessment for the presence and directionality of shunts. Evaluation of the PDA should include measures of LA volume loading and SBF as detailed in Section 3.

**Other Considerations.** TNE evaluation of central lines is important as thrombi and pericardial tamponade may all cause sudden and unexpected acute deterioration; specifically, cardiogenic shock or pulmonary embolism may ensue. Having a high index of suspicion for these complications is crucial and can be lifesaving.

### Recommendation

All standard TNE evaluations should include an assessment of the position of any central lines (Table 3, Figures 21 and 22), an exclusion of pericardial effusion (Table 3, Figure 23), and surveillance for potential complications such as thrombosis and/or vegetations (Table 3, Figure 24).

### Advanced Imaging and Measurements

The use of Doppler tissue imaging to obtain supplementary data about myocardial performance may have advantages over conventional Doppler methods. Conventional pulsed-wave Doppler captures the velocity of low amplitude, fast-moving signals and therefore reflects the velocity of blood. In contrast, Doppler tissue imaging captures the velocity of high amplitude, slower moving signals.<sup>65</sup> Higher temporal resolution, and therefore higher frame rate, is achievable when a very narrow sector is used. This makes it possible to capture time intervals, such as the isovolumetric contraction time and IVRT, with greater accuracy and enables calculations such as the systolic to diastolic duration ratio (Figure 25). This is particularly useful in neonates given the tendency toward high heart rates. There is limited neonatal literature; however, in adults the ratio of conventional Doppler velocity (e.g., MV E) to tissue Doppler velocity (e.g., LV lateral wall e') have been used

**Table 3** Images and measurements that should be included in any targeted neonatal echocardiogram

Measurement	View	Formula/ measurement (if applicable)	Measurement performance	Other points
<b>LV systolic function</b>				
Area-length method Also known as hemicylindrical hemielipsoid model	Apical and PSAX	Figure 1	<ul style="list-style-type: none"> <li>Calculated using a long axis length (<math>L</math>) and cross-sectional area (<math>A</math>) of an orthogonal short-axis view at the midpapillary muscle</li> </ul>	Assumptions <ul style="list-style-type: none"> <li>Base = cylindrical</li> <li>Apex = ellipsoid</li> </ul>
Simpson biplane Normal: 55%- 70%	Apical four-chamber/ apical two-chamber LV-focused view that maximizes LV area and ensures clear endocardial border definition	Figure 2	<ul style="list-style-type: none"> <li>Trace LV endocardial–blood pool interface (between cavity and compacted myocardium); end-systole and end-diastole</li> <li>Papillary muscles should be excluded from the cavity tracing and MV closed</li> <li>When approaching the MV plane, the contour is closed by connecting the two opposite sections of the MV ring (from the valve hinge point) with a straight line</li> </ul>	<ul style="list-style-type: none"> <li>ECG can help identify end of diastole, but end-systole is less reliable. Estimating the minimum chamber size on 2D evaluation is preferable.</li> </ul>
Fractional shortening Normal: 30%-45%	PLAX or PSAX	Figure 3	<ul style="list-style-type: none"> <li>Linear, internal dimensions may be obtained either on 2D or M-mode images of the left ventricle in PLAX or PSAX view</li> <li>M-mode imaging: line of interrogation should be applied at the level of the MV leaflet tips<sup>51</sup></li> <li>2D: measurements should be obtained from PSAX or PLAX view at the level of the MV leaflet tips</li> </ul>	<ul style="list-style-type: none"> <li>ECG can help identify end-systole and end-diastole.</li> <li>M-mode imaging: myocardial border of LV posterior wall (location of caliper application for measurements) may be denoted as the line of greatest slope during systole</li> </ul>
<b>LV diastolic function/LA loading</b>				
Pulmonary vein S, D, and A velocities	Apical four-chamber	Figure 4	<ul style="list-style-type: none"> <li>Align RLPV and place the sample volume parallel to flow inside the vein</li> </ul>	<ul style="list-style-type: none"> <li>Venous dilation may affect flow velocity, particularly when shunt is chronic</li> </ul>
Mitral E, A, and E/A Normal: GA dependent	Apical four-chamber	Figure 5	<ul style="list-style-type: none"> <li>PW Doppler at level of tips of MV leaflets</li> <li>Estimate ratio of velocity of early (E) and late (or atrial, A) waves</li> </ul>	<ul style="list-style-type: none"> <li>If E and A wave appear fused (cannot be distinctly identified), measurement should not be performed</li> </ul>
IVRT	Apical four-chamber	Figure 6	<ul style="list-style-type: none"> <li>Open LVOT with anterior angulation and/or slight clockwise rotation</li> <li>PW Doppler with the sample volume at the crossing of LV inflow and outflow</li> </ul>	<ul style="list-style-type: none"> <li>Increase sweep speed to spread out the waveform to facilitate IVRT measurement</li> </ul>

(Continued)



**Table 3** (Continued)

Measurement	View	Formula/ measurement (if applicable)	Measurement performance	Other points
LA/Ao ratio Normal <1.5 <sup>52</sup>	PLAX	Figure 7	<ul style="list-style-type: none"> <li>• M-mode measurement using leading edge of Ao to leading of LA end-diastole<sup>51</sup></li> <li>• Make sure two leaflets can be seen</li> </ul>	<ul style="list-style-type: none"> <li>• Relatively poor performance as a PDA marker in isolation<sup>53</sup></li> </ul>
SBF				
LVO Normal 150-300 mL/min/kg	Apical five-chamber, PLAX	Figure 8	<ul style="list-style-type: none"> <li>• VTI: PW Doppler with sample volume at level of aortic valve annulus</li> <li>• Annulus: from hinge point (not leaflet) to hinge point of annulus</li> </ul>	<ul style="list-style-type: none"> <li>• Angle of insonation as close to 0° as possible. Angle correction should not be used.</li> </ul>
Aortic diastolic flow Normal: absent flow throughout diastole	Suprasternal or abdominal	Figure 9	<ul style="list-style-type: none"> <li>• Image aortic arch and use color Doppler to identify D<sub>Ao</sub> (scale 60-70 cm/sec)</li> <li>• PW Doppler with sample volume in D<sub>Ao</sub> at the level of the diaphragm</li> <li>• Decrease “low-velocity reject” to &lt;0.1 m/sec to visualize lower velocity flow</li> </ul>	<ul style="list-style-type: none"> <li>• Diastolic flow reversal in the postductal D<sub>Ao</sub> and abdominal Ao reversal is a marker of hemodynamically significant PDA. Rarely this can denote hemodynamically important aortic valve incompetence in neonates.</li> <li>• Antegrade flow may suggest aortic arch obstruction or coarctation</li> <li>• Retrograde flow in the preductal arch may suggest cerebral vein of Galen malformation or severe LV disease</li> <li>• Suprasternal view preferred as easier to align parallel to flow</li> </ul>
Celiac artery and SMA diastolic flow velocity Normal: antegrade flow throughout	Subcostal LAX view	Figure 10	<ul style="list-style-type: none"> <li>• Image abdominal Ao in long axis and identify celiac trunk</li> <li>• PW Doppler with sample volume in proximal celiac artery or SMA</li> </ul>	<ul style="list-style-type: none"> <li>• Angle of insonation as close to 0° as possible. Angle correction should not be used.</li> <li>• Poor angle is common for SMA measurements</li> </ul>
RV function				
RV FAC Normal RV three-chamber: ≥0.35 RV four-chamber: ≥0.35	RV three-chamber or RV-focused apical four-chamber	Figure 11	<ul style="list-style-type: none"> <li>• RV-focused view that maximizes RV area</li> <li>• Trace RV endocardial–blood pool interface (between compacted myocardium and the cavity) at end-systole and end-diastole on images with clear</li> </ul>	<ul style="list-style-type: none"> <li>• Identifying the endocardial–blood pool interface may be challenging because of RV trabeculations or papillary muscle</li> </ul>

(Continued)

Table 3 (Continued)

Measurement	View	Formula/ measurement (if applicable)	Measurement performance	Other points
			<ul style="list-style-type: none"> <li>endocardial border definition</li> <li>RV trabeculations should be excluded from the cavity tracing</li> <li>When approaching the TV plane, the contour is closed by connecting the two opposite sections of the TV ring (from the valve hinge point)</li> </ul>	
TAPSE Normal: GA dependent <sup>54</sup>	Apical four-chamber (RV focused)	Figure 12	<ul style="list-style-type: none"> <li>DTI enhanced M-mode imaging is used with sector narrowed (if needed) such that frame rate is &gt;200 frames/sec</li> <li>Line of interrogation should pass through the apex and through the RV base at the lateral tricuspid annulus</li> <li>Cursor perpendicular to the TV annulus</li> </ul>	<ul style="list-style-type: none"> <li>Measurement should be performed from “leading edge to leading edge” or “outer edge to outer edge”</li> <li>TAPSE is calculated as the difference from end diastole to end systole</li> </ul>
RVO Normal 150-300 mL/min/kg	PLAX or PSAX	Figure 13	<ul style="list-style-type: none"> <li>Narrow window on the PA</li> <li>PW Doppler with sample volume at the level of the PV annulus</li> <li>PV diameter estimated as the distance between valve hinge points in late systole</li> </ul>	<ul style="list-style-type: none"> <li>Angle of insonation as close to 0° as possible</li> <li>PV should be well seen throughout the entire cardiac cycle</li> <li>VTI and annulus should be from the same plane</li> </ul>
Pulmonary hemodynamics				
PAP (PI jet)	PLAX or PSAX	Figure 14	<ul style="list-style-type: none"> <li>CW Doppler through the pulmonary regurgitation jet</li> </ul>	<ul style="list-style-type: none"> <li>PI jet velocity can be used to calculate components of PAP</li> </ul>
RV systolic pressure (TR jet)	Various	Figure 15	<ul style="list-style-type: none"> <li>CW Doppler of tricuspid regurgitation jet</li> <li>Measure peak TR jet velocity from a complete Doppler envelope</li> </ul>	<ul style="list-style-type: none"> <li>Falsely low TR jet velocity may occur in setting of reduced RV systolic function</li> </ul>
Systolic EI Normal ≤1.3	PSAX	Figure 16	<ul style="list-style-type: none"> <li>Ratio of left-right and AP diameter of LV at end-systole that quantitatively estimates “interventricular septal flattening”<sup>55</sup></li> <li>Level of papillary muscle</li> </ul>	<ul style="list-style-type: none"> <li>Ensure RV overlies LV</li> <li>Ventricular wall can be differentiated from papillary muscle by its smooth interface</li> </ul>
PVR index May be expressed as either RVET/PAAT (normal <4) or PAAT/RVET (normal <0.25)	PLAX or PSAX	Figure 17	<ul style="list-style-type: none"> <li>PW sample volume must be within the main PA at the tip of the PV leaflets when open</li> <li>Peak velocity of the Doppler envelope may appear “rounded,” such</li> </ul>	<ul style="list-style-type: none"> <li>Estimate of RVET may be difficult in setting of PDA shunt because of obscuration of the Doppler envelope at end-systole</li> </ul>

(Continued)

**Table 3** (Continued)

Measurement	View	Formula/ measurement (if applicable)	Measurement performance	Other points
			that one distinct peak is difficult to identify. In this scenario, PAAT should be measured at the earliest aspect of the peak, rather than at midpeak.	
<b>PDA</b>				
Ductal diameter	Suprasternal/high PS	Figure 18	<ul style="list-style-type: none"> <li>• With probe at 12 o'clock position, image the MPA and DAo visualizing the full length of the PDA</li> <li>• Measure diameter at the narrowest point along the ductal length, typically near the pulmonary end, when the shunt is at its peak during cardiac cycle</li> </ul>	<ul style="list-style-type: none"> <li>• Among neonates on mechanical ventilation, the high PS view may not provide optimal image quality; an alternative view is low PS by angling posteriorly from a branch PA view</li> </ul>
Ductal Doppler	Suprasternal/high PS	Figure 19	<ul style="list-style-type: none"> <li>• Sample volume within the PDA at pulmonary end, distal to the narrowest diameter. Use PW if there is no aliasing (typically peak velocity &lt; 2 m/sec) and CW if aliasing occurs despite increasing the PW scale to the maximum.</li> <li>• Measuring shunt gradient: perform a VTI trace of the PDA gradient to obtain the (1) peak systolic pressure gradient and (2) mean pressure gradient</li> </ul>	<ul style="list-style-type: none"> <li>• When using CW Doppler, ensure that Doppler beam is placed at the narrowest point of the PDA parallel to the direction of flow</li> </ul>
Branch PA velocity Normal diastolic velocity <0.3 m/sec	High PS	Figure 20	<ul style="list-style-type: none"> <li>• Narrow window on the PA and angle anteriorly to bring branch PAs into view</li> <li>• PW Doppler with sample volume within the proximal branch PA</li> </ul>	<ul style="list-style-type: none"> <li>• Left PA is typically easier to align and is therefore the preferred site for Doppler interrogation</li> </ul>
<b>Other core elements of TNE</b>				
UVC position	Subcostal modified PSAX	Figure 21	<ul style="list-style-type: none"> <li>• Identify the UVC in long axis in the ductus venosus and the tip of the UVC</li> </ul>	<ul style="list-style-type: none"> <li>• Eustachian valve appears as a thin, linear echogenic fold at the junction of the IVC and RA and may be mistaken for a central line</li> </ul>
UE PICC position	Sagittal high PS	Figure 22	<ul style="list-style-type: none"> <li>• Central to peripheral sequential evaluation technique:</li> </ul>	<ul style="list-style-type: none"> <li>• Identifying the catheter tip may be</li> </ul>

(Continued)

Table 3 (Continued)

Measurement	View	Formula/ measurement (if applicable)	Measurement performance	Other points
			<ol style="list-style-type: none"> <li>I. Evaluate for intracardiac placement: from multiple planes, sweep the right ventricle and right atrium; if no catheter identified, go to II</li> <li>II. Evaluate for SVC placement: from modified PS long-axis view, interrogate SVC for the presence of the catheter; if no catheter identified, go to III</li> <li>III. From high PS view, interrogate the subclavian and innominate veins for the presence of the catheter</li> </ol>	<p>challenging for PICC in the UE</p> <ul style="list-style-type: none"> <li>• Injection of a small volume of saline (and visualization of the saline exiting the catheter tip) is the most reliable method of ascertaining catheter tip position</li> </ul>
Pericardial effusion/ tamponade	Various	Figure 23	<ul style="list-style-type: none"> <li>• Pericardial effusion may be circumferential (larger volume) or focal (smaller volume, typically dependent areas)</li> <li>• Unilateral/localized effusions may also be located in the pleural space or abdomen</li> <li>• Tension pneumothorax may cause tamponade without a pericardial effusion</li> </ul>	<ul style="list-style-type: none"> <li>• Tamponade occurs when intrapericardial pressure exceeds RA pressure</li> <li>• RA collapse during ventricular systole, which reflects reduced atrial filling, is the earliest echocardiography indicator of tamponade</li> </ul>
Thrombus/vegetation	Various	Figure 24	<ul style="list-style-type: none"> <li>• Interrogate suspicious echogenic foci from at least two different planes, using continuous sweeps if possible</li> </ul>	<ul style="list-style-type: none"> <li>• Echogenic foci within cardiac chambers are common and should be distinguished from adjacent cardiac endocardium/myocardium</li> <li>• Pedunculated or mobile echogenic foci should elicit a high index of suspicion for thrombus or vegetation</li> </ul>

2D, Two-dimensional; Ao, aorta; AP, anteroposterior; CW, continuous-wave; DAo, descending aorta; ECG, electrocardiography; GA, gestational age; LAX, long-axis; LVOT, left ventricular outflow tract; PLAX, parasternal long-axis; PS, parasternal; PSAX, parasternal short-axis; PV, pulmonary valve; PW, pulsed-wave; RA, right atrium; RLPV, right lower pulmonary vein; SMA, superior mesenteric artery; SVC, superior vena cava; TV, tricuspid valve; UE, upper extremity; VTI, velocity-time integral.

as a relatively load independent measure of filling pressure and diastolic performance.<sup>66</sup> Similar calculations can be performed at the tricuspid valve free wall; however, normative data in neonates are limited. Pulse-wave Doppler tissue imaging may also be used to measure ventricular deformation/strain.<sup>67</sup> As in conventional Doppler, it is essential that the angle of insonation of the wall is

parallel with the sample volume placed just below the annulus. In neonates a standard Doppler gate size of 2 mm is recommended to minimize contamination by atrial signal. Additionally, Doppler tissue imaging is a point measurement and may not be reflective of global myocardial performance in the presence of regional wall motion abnormalities.

## Recommendation

Where normative data exist, Doppler tissue imaging provides additional information on myocardial performance and should be included in a standard TNE assessment as part of a multiparametric appraisal of heart function. Myocardial velocities should be considered when there is suspected heart dysfunction and disagreement between other modalities (e.g., TAPSE, RV FAC).

## Research Tools and Emerging Measurements

**Speckle-Tracking Echocardiography.** Speckle-tracking echocardiography (STE) is a method of function assessment that is used primarily to measure tissue deformation by tracking the motion of two-dimensional “speckles” within the myocardium throughout the cardiac cycle. Strain analysis involves the absolute deformation from baseline and is expressed as a percentage change.<sup>67</sup> Strain rate is the rate at which that deformation occurs and is thought to be less load dependent than strain, making it a potentially superior measure of contractility.<sup>67</sup> Both strain and strain rate may be measured for the left and right ventricles. Global longitudinal strain is increasingly recognized as a more effective technique than conventional EF in detecting subtle changes in LV function, and normative data for STE parameters have been published in select populations<sup>68-70</sup> (Figure 26).

Because the processes of LV systolic performance are complex and include three directions according to myocardial fiber alignment, strain may be measured using STE in three orientations: longitudinal, circumferential, and radial. RV systolic performance, in contrast, is limited to longitudinal strain which may be measured either in an RV-focused four-chamber or RV three-chamber view. Segmental RV strain should be measured at the free wall only and should not include the septum in the four-chamber view. STE has also been used to demonstrate the three phases of LA mechanics: (1) the reservoir phase (mitral closure to opening), which encompasses the LV isovolumetric contraction time, ejection, and IVRT; (2) the conduit phase, from MV opening through diastasis until the onset of LA contraction; and (3) the contraction phase, from the onset of LA contraction until MV closure. The clinical utility of LA strain remains an area of active research.

Finally, STE can be used in conjunction with other measurements. For example, the load dependency of strain may be used in conjunction with systemic BP to produce a measurement of LV myocardial work, which has been validated as a measure of myocardial energetics. Similarly, more comprehensive evaluation of the entirety of LV contractility may be obtained using a measurement of LV Twist, which is defined as the net difference of LV rotation between apical and basal short-axis planes. “Torsion” is the term used to describe LV twist indexed to its length and enables the comparison of LV twist across differing LV sizes. Rotational strain is performed at the basal (which rotates clockwise) and apical (which rotates counterclockwise) levels. Software is used to plot apical and basal rotation during one cardiac cycle to determine twist and then indexed to LV length to calculate LV torsion, which accounts for differences in LV size.<sup>71</sup>

To optimize STE, it is essential that the imaging plane includes the entirety of the wall(s) of interest throughout the cardiac cycle. Air interference is often a limitation of STE, particularly among babies with hyperinflated lungs or pneumomediastinum. Images that are going to be used for STE should be taken at similar heart rates such that it is possible for the software to integrate the images. For LA

strain, the strain task force recommends tracing the left atrium to extrapolate across pulmonary veins and LA appendage orifices.<sup>72</sup>

## Recommendation

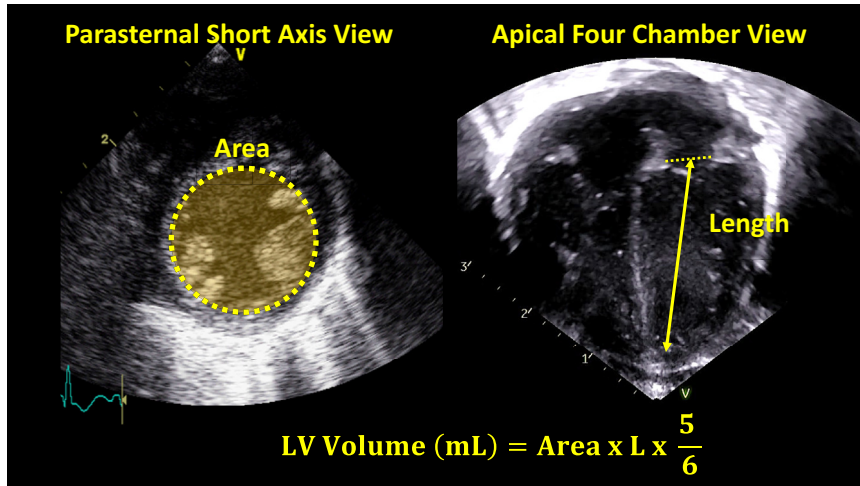
When performing standard TNE, STE may provide ancillary data regarding systolic performance, segmental abnormalities, and load dependency; however, natural history data are limited to date in the neonate, and further research is needed.

## The First Complete Echocardiogram

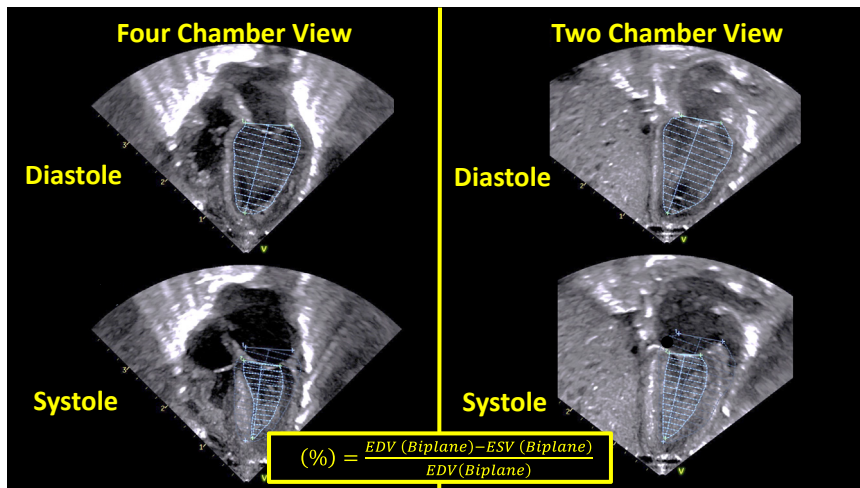
If standard TNE constitutes the first neonatal echocardiogram, for patients with low suspicion for CHD, it should include the essential views and sweeps to enable a comprehensive anatomical and functional assessment. The study should be performed by a sonographer with proficiency in performing a complete study to screen for critical CHD.<sup>73,74</sup> Although the study may be performed and interpreted preliminarily by a neonatologist with advanced TNE experience, it should also be reviewed by a pediatric cardiologist in a timely fashion (i.e., within 24 hours or a reasonable time frame on the basis of local standards).<sup>8</sup> Data from a single high-volume center reports high concordance of the impression from a first study, performed and interpreted by a trained neonatologist, with the results of the formal pediatric cardiology evaluation.<sup>75</sup> In addition, the need for reimaging was also low. Of note, the rate of major CHD was low, which shows compliance with the guidelines. It is also important to highlight that these results are reflective of a high-volume neonatal hemodynamics program which is closely integrated with the pediatric echocardiography laboratory; therefore, the results may not be applicable to low-volume or rural centers. Telemedicine may be an option for NICUs without pediatric cardiologists on staff.

The first complete echocardiogram must include standardized images and sweeps (Table 4) sufficient to exclude critical cyanotic lesions (e.g., d-transposition of the great arteries). Outflow tract obstruction must be assessed to exclude ductal dependency for SBF (for a neonate with shock) or pulmonary blood flow (for a neonate with cyanosis). Certain ductal-dependent lesions, such as coarctation of the aorta, may be difficult to assess without sufficient expertise and experience. Both atrioventricular valves and the ventricles should be evaluated for size and morphology to differentiate functional vs structural pathology, such as congenital valve dysplasia or primary cardiomyopathy. Sweeping in all planes is important to understand the anatomy in three dimensions and, using color Doppler, to assess for septal defects. Pulmonary venous return must be assessed critically, particularly for a cyanotic neonate with or without respiratory distress. As the pulmonary veins are small structures and various forms of anomalous drainage may occur, some more life-threatening than others in the neonatal period, careful review by a pediatric cardiologist is essential.

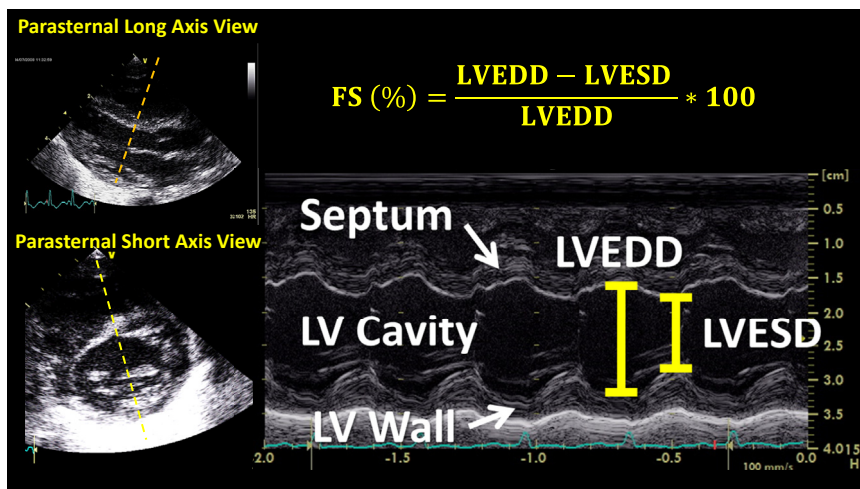
Other elements of the first-time anatomic evaluation may be performed in specific situations. Systemic venous anomalies are unlikely to be critical but may have important implications for central line access. Arch sidedness and branching should be evaluated for neonates with upper airway obstruction to exclude a vascular ring or PA sling. Aortic arch sidedness may also be necessary if surgical PDA ligation or other intrathoracic interventions are warranted. Finally, although coronary artery anomalies rarely present in the neonatal period, their evaluation is a standard part of first-time congenital heart studies. Complete evaluation of coronary artery anatomy and physiology should be performed during the hospitalization. Interpretation by



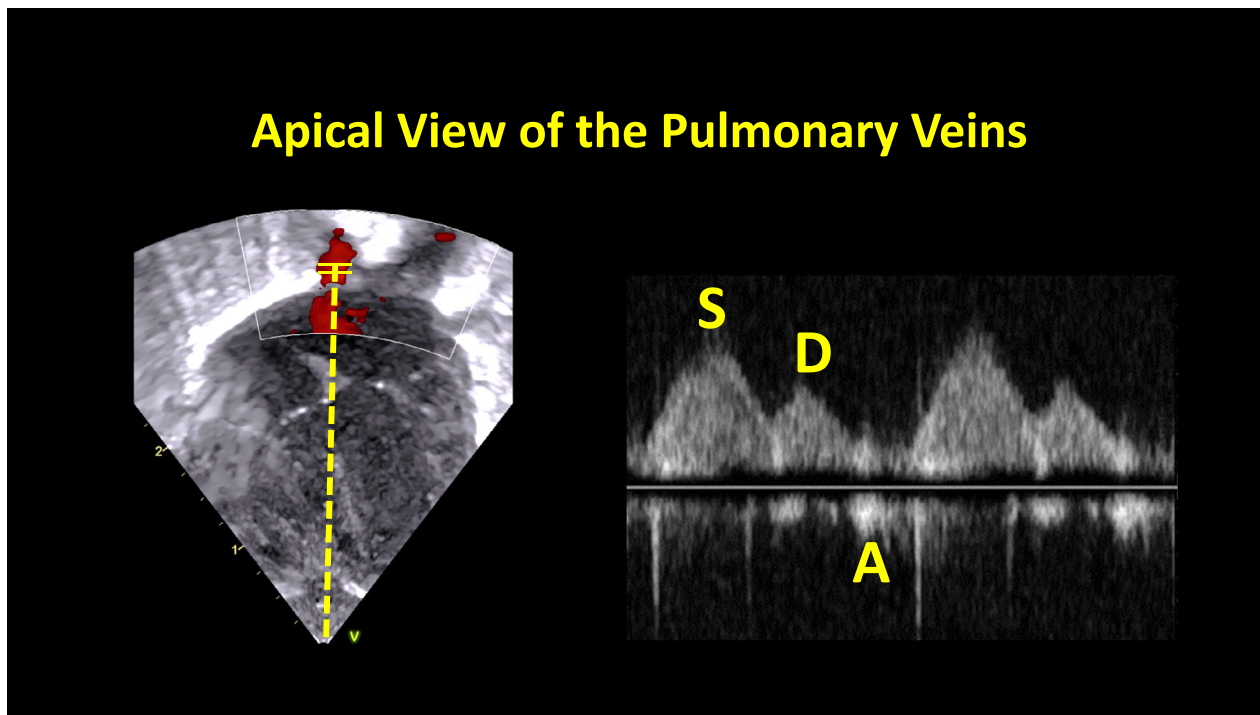
**Figure 1** LV volume measurement using the area-length method from the apical four-chamber view. *L*, Length; *r*, radius.



**Figure 2** Simpson biplane measurement of EF from the apical four-chamber and two-chamber views. *EDV*, End-diastolic volume; *ESV*, end-systolic volume.



**Figure 3** Shortening fraction measurement from the parasternal long-axis view. *FS*, Fractional shortening; *LVEDD*, LV end-diastolic diameter; *LVESD*, LV end-systolic diameter.



**Figure 4** Pulmonary vein S, D, and A velocities using pulsed-wave Doppler.

echocardiographers with expertise is important, and follow-up imaging may be performed as recommended.

### Recommendation

A neonatologist with advanced training in TNE may perform standard TNE as the first study in patients with a low index of suspicion for CHD, but the study should include the essential views and sweeps to enable anatomic assessment. At centers with on-site pediatric echocardiography laboratories, these studies should be reviewed within a timely manner on the basis of local standards. At centers without on-site pediatric cardiology, when significant CHD is suspected or diagnosed, transfer to a site with pediatric cardiology or remote pediatric cardiology study review should occur.

### The cPOCUS Evaluation

**Scope of cPOCUS Evaluation.** The recent ASE guidelines and recommendations for cPOCUS focused on use in children and adults, but neonates were excluded.<sup>15</sup> A recent technical report by the American Academy of Pediatrics, however, provided additional guidance on the use of POCUS, including cPOCUS, in neonates.<sup>76</sup> The role of cPOCUS in the evaluation of the acutely unstable neonate has also been suggested.<sup>77</sup> Therefore, the writing group felt it was important to delineate the scope of cPOCUS and how it differs from a standard TNE evaluation. cPOCUS is a brief, limited cardiovascular imaging evaluation in specific clinical situations. The typical indications for cPOCUS include evaluation of central catheter (arterial or venous) tip location, identification of pericardial or pleural effusions, and differentiation of hypovolemia vs myocardial dysfunction in an acutely unstable neonate (Table 2). At some centers, LV fractional shortening may be used to quantify the severity of heart dysfunction. Assessment of hemodynamic significance of PDA, acute

or chronic PH, or quantitative evaluation of heart function are not recommended indications for cPOCUS. A standard POCUS assessment may involve evaluation of multiple organ systems; therefore, as the emphasis on cardiac imaging is limited, the training requirements are less demanding than for standard TNE.

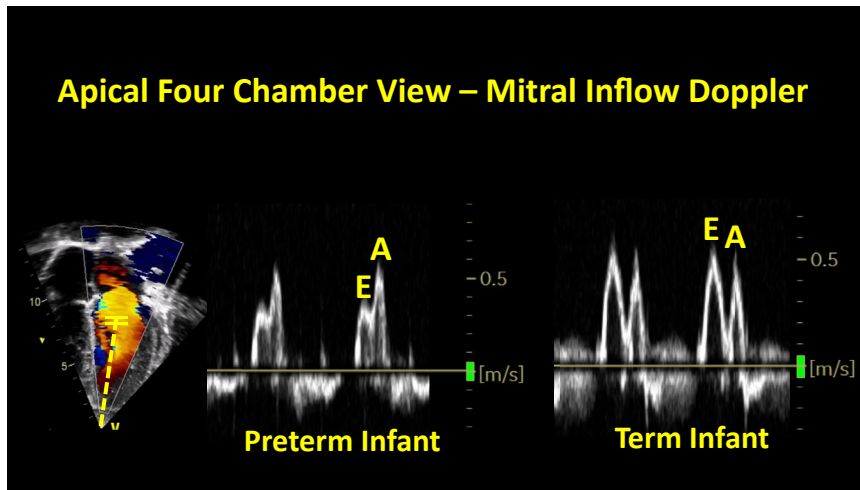
### Recommendation

A neonatologist-performed cPOCUS evaluation may include evaluation of central catheter tip location, identification of pericardial or pleural effusions, subjective (“eyeballing”) evaluation of inferior vena caval collapsibility as a surrogate of hypovolemia, and subjective evaluation of myocardial systolic performance. If a cPOCUS study is the first patient evaluation, a timely standard TNE evaluation or complete pediatric cardiology echocardiography evaluation is recommended.

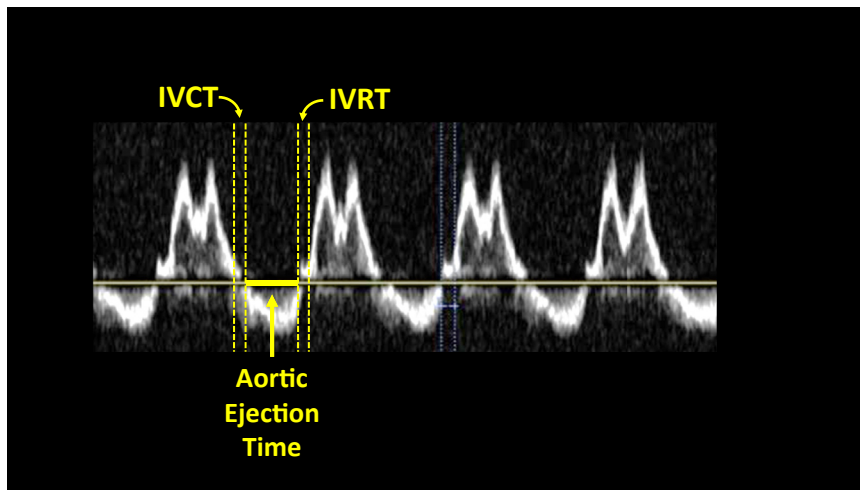
## TNE: APPLICATION OF IMAGING

### Disease-Based Screening

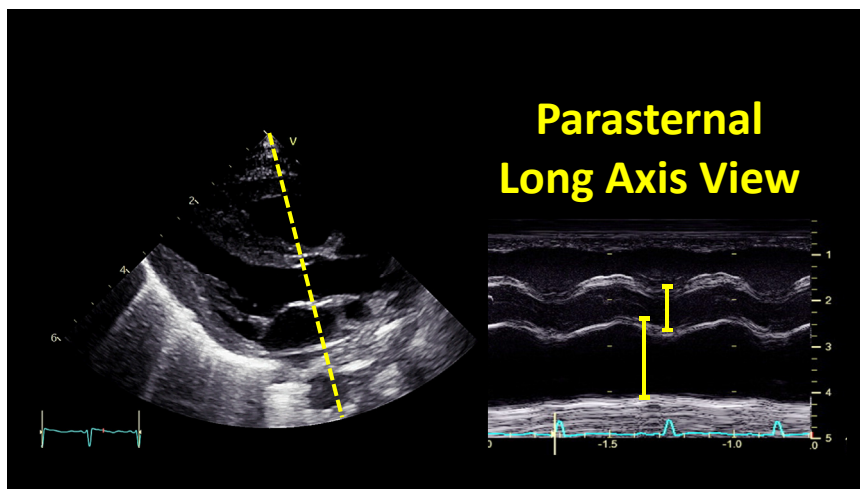
**PDA in Premature Infants. Scope of the Problem.** PDA is the most common cardiovascular abnormality in premature infants with >70% of infants <28 weeks’ gestation demonstrating persistent ductal patency beyond the first week of age.<sup>23</sup> Although accurate echocardiography determination of shunt volume is not feasible, surrogate markers of pulmonary overcirculation and systemic hypoperfusion are used to estimate the degree of hemodynamic significance.<sup>24</sup> Adjudicating hemodynamic significance requires integration of echocardiographic markers of PDA shunt volume and clinical factors such as gestational age or confounding treatments (e.g., mechanical ventilation). This may result in improved risk prediction facilitating a more accurate and targeted selection of infants that are more likely to benefit from treatment.<sup>78</sup> Those



**Figure 5** MV pulsed-wave Doppler measurement showing passive (E-wave) and active (A-wave) flow in preterm and term infants from the apical four-chamber view.

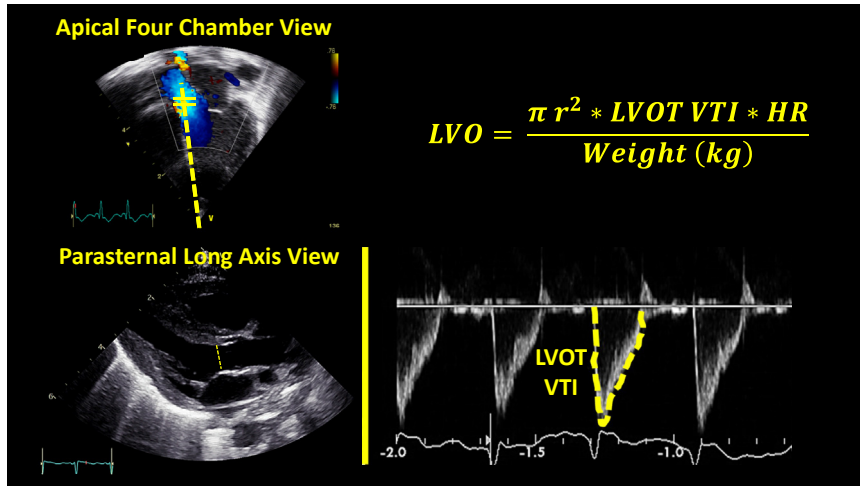


**Figure 6** Estimation of isovolumetric measurements using pulsed-wave Doppler from the apical four-chamber view. *IVCT*, Isovolumetric contraction time.

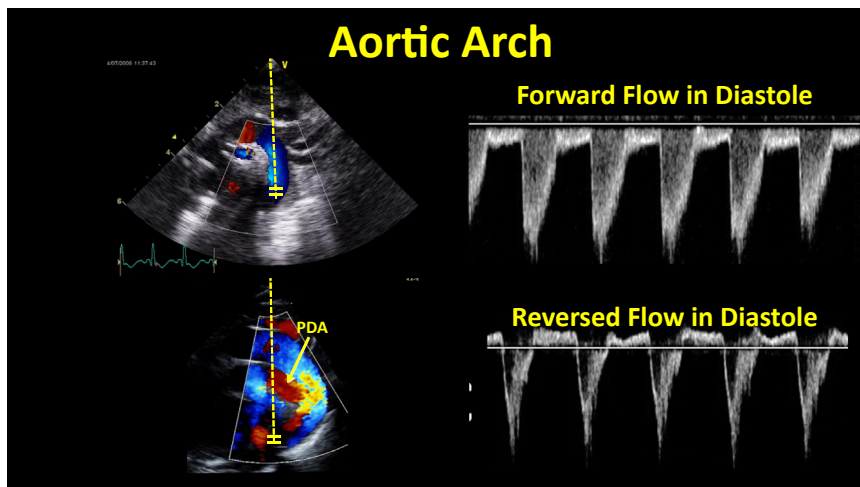


**Figure 7** LA-to-aortic root ratio measurement from the parasternal long-axis view. Ao, Aorta.

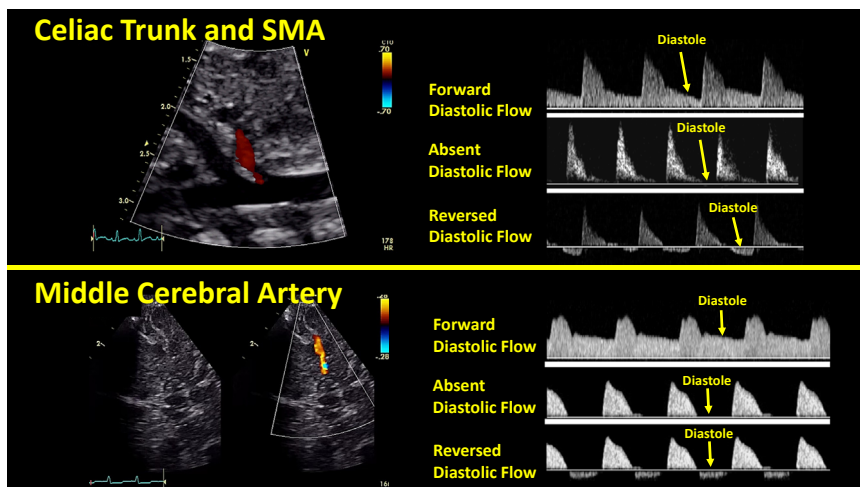




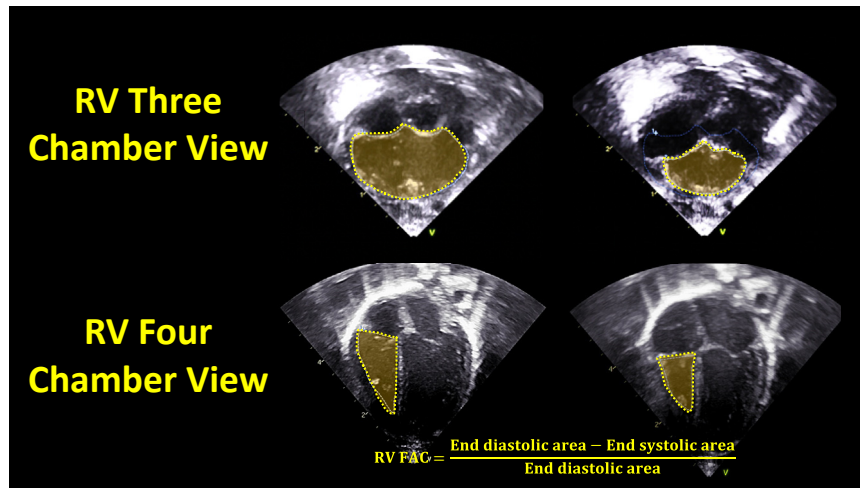
**Figure 8** LVO measurement on the basis of pulsed-wave Doppler from the apical five-chamber view. *HR*, Heart rate; *r*, radius; *VTI*, velocity-time integral.



**Figure 9** Pulsed-wave Doppler interrogation of aortic diastolic flow from the suprasternal arch view.



**Figure 10** Pulsed-wave Doppler interrogation of celiac trunk and superior mesenteric artery flow from the abdominal view and middle cerebral artery from the axial mastoid view.



**Figure 11** RV FAC measurement from the RV three-chamber and RV four-chamber views.

elements have been described at length elsewhere but include the following (Table 5): PDA shunt volume assessment and its impact on the systemic and pulmonary circulations (see the previous section), myocardial function evaluation (including LV diastolic performance), and antenatal and perinatal characteristics that can act as effect modifiers to either mitigate or exacerbate potential detrimental consequences of a shunt.

**Indications for and Suggested Timing of Echocardiography.** All premature infants with clinical features of pulmonary overcirculation (oxygenation or ventilation impairment) and/or systemic hypoperfusion (postductal hypotension, metabolic acidosis) should have timely echocardiography assessment. In addition, because of the imprecision of clinical symptoms, early screening echocardiogram within 72 hours after birth may be considered in extremely premature infants <28 weeks of gestation.

**Guidance on Clinical Decision-Making.** Currently there is no consensus on the need for, or timing of PDA treatment in preterm infants. Ascribing hemodynamic significance should be based on a multiparametric echocardiography approach including ductal size and the pattern of transductal flow, markers of pulmonary overcirculation and systemic hypoperfusion.

## Recommendations

In every neonate with clinical suspicion for PDA, or those <28 weeks' gestation, the first standard TNE study to characterize hemodynamic significance of PDA should be sufficiently comprehensive to exclude major CHD, especially ductal-dependent systemic or pulmonary blood flow lesions. Subsequent TNE may be useful in follow-up to document spontaneous closure or the effect of treatment. Patients suspected of an additional cardiovascular malformation should be referred for pediatric cardiology review, or transfer if indicated, in a timely manner.

**PH in Infants with Bronchopulmonary Dysplasia.** Scope of the Problem. Bronchopulmonary dysplasia (BPD)-associated PH is an important morbidity occurring up to 20% of high-risk

premature infants.<sup>79</sup> There are several risk factors associated with developing BPD-associated PH. These include fetal growth restriction, oligohydramnios, prolonged rupture of membranes, preeclampsia, prolonged exposure to PDA, length of mechanical ventilation and oxygen supplementation, and extreme prematurity.<sup>80</sup> BPD-associated PH is associated with an increased risk for mortality and morbidity in premature infants; therefore, prompt recognition and diagnosis are essential for ongoing management.<sup>81</sup>

**Indications for and Suggested Timing of Echocardiography.** Screening for BPD-associated PH should be considered for all premature infants requiring ventilator support beyond the first week of age. A screening echocardiogram is recommended for all preterm infants born before 29 weeks' gestation, who require ongoing oxygen requirement or assisted ventilator support, at 8 postnatal weeks or 36 weeks (whichever is sooner) postmenstrual age to screen for the presence of BPD-associated PH.

**Guidance on Clinical Decision-Making.** Standard TNE should be used to estimate PAP, RV function, and the adequacy of SBF (Table 5). TNE can be used to guide the initiation of therapy, assess treatment response, and finally to guide the weaning of treatment. Assessment of PAP should include the interrogation of the TR jet and the shunt velocity across the PDA, if present, to estimate RVSP and PAP. However, those markers may not be present in all infants and can underestimate the degree of PH in the presence of RV dysfunction. Assessment of septal wall morphology from the parasternal short-axis view and the calculation of the systolic EI may provide an objective measure of the degree of septal flattening observed in the presence of elevated RV pressure. PAAT and PVR index are validated and reproducible markers that can be used to detect the presence of elevated PAP in premature infants. Subjective assessment of RV function is highly unreliable and should be avoided.<sup>55</sup> RV function should be objectively assessed using validated measurements including FAC, Doppler tissue imaging, TAPSE, and deformation imaging. Appraisal of pulmonary vein flow (all visualized vessels) to detect high pulmonary vein velocity (>1.0 m/sec) should be a mandatory component of all studies for BPD-associated PH, with timely referral to a pediatric cardiologist.

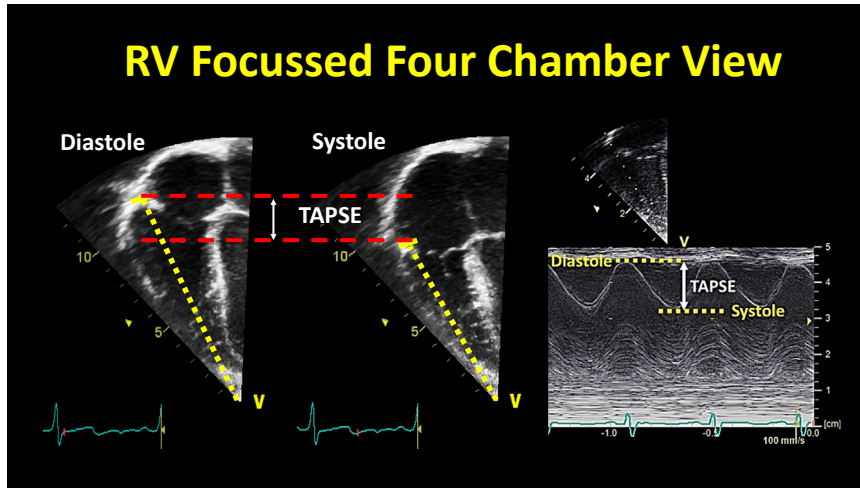


Figure 12 TAPSE measurement from the apical four-chamber view.

### Recommendation

Preterm infants with persistent need for respiratory support (continuous positive airway pressure or mechanical ventilation) and/or prolonged oxygen need should be considered for standard TNE evaluation to screen for the presence of PH and rule out CHD. Infants born before 29 weeks' gestation and rule out CHD. Infants born before 29 weeks' gestation should be considered for a screening TNE assessment at 8 postnatal weeks or 36 weeks' postmenstrual age (whichever is sooner) to assess for the presence of BPD-associated PH. TNE allows assessment of the effect of treatment on PAP, RV function, shunt direction at the atrial and ductal levels, and screening for pulmonary vein stenosis.

900,000 neonatal deaths each year.<sup>82</sup> Therapeutic hypothermia has become standard of care therapy in the developed world, with evidence from randomized trials suggesting both a morbidity and mortality benefit.<sup>83</sup> Observational studies have suggested that deranged cerebral blood flow during the first 3 to 4 postnatal days may be associated with a greater likelihood of abnormal brain outcomes.<sup>60,84-86</sup> Although the mechanism by which this may occur is uncertain, ischemia/reperfusion disease in the setting of impaired cerebral autoregulation is a biologically plausible mechanism. RV dysfunction is a common co-traveler with HIE, in part because of a common mechanistic origin. In utero adaptation to impaired placental substrate delivery results in redirection of blood away from the lungs (via increasing PVR) to the most vulnerable organs which include the adrenal gland, coronary circulation and the brain.<sup>87</sup> This results in two primary issues of postnatal adaptation. First, the pulmonary vasculature is primed to constrict, which impedes the rapid postnatal PVR decline; this is further exacerbated by the presence of acidosis, hypercarbia and hypoxia and places a substantial

**Infants with HIE. Scope of the Problem.** HIE is one of the leading causes of neonatal mortality worldwide and contributes to nearly

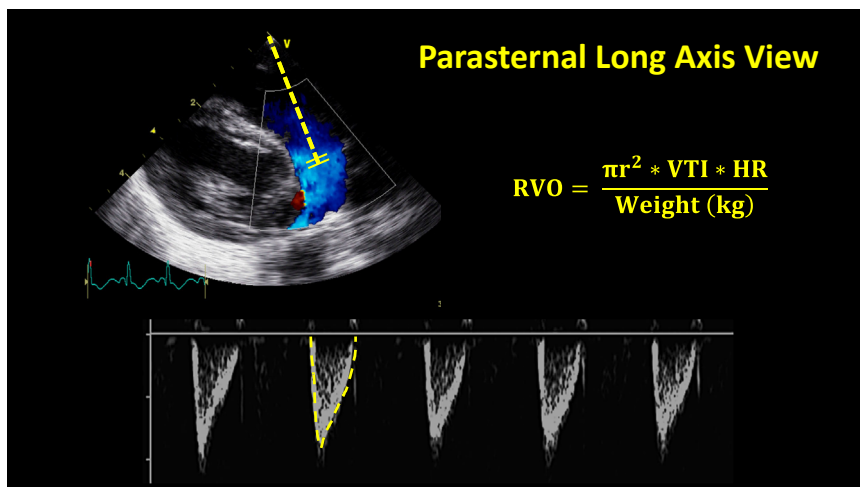
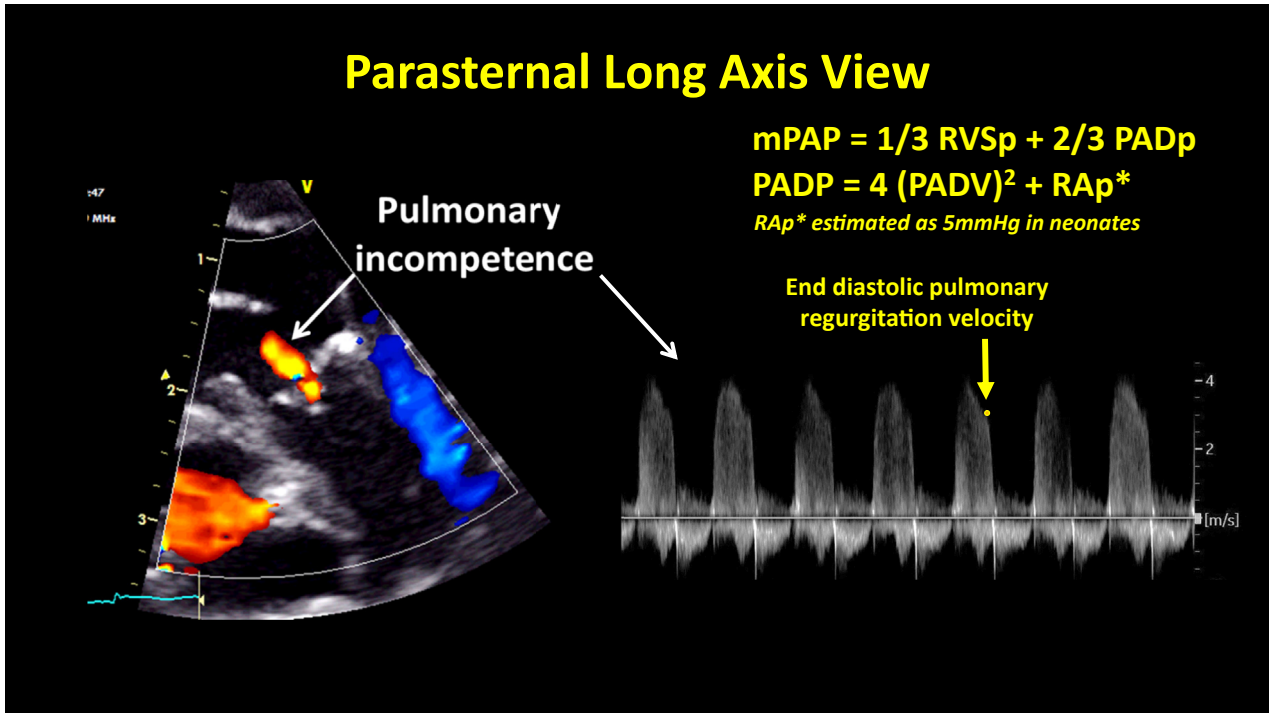


Figure 13 RVO measurement on the basis of pulsed-wave Doppler from the parasternal long-axis view. HR, Heart rate; r, radius; VTI, velocity-time integral.

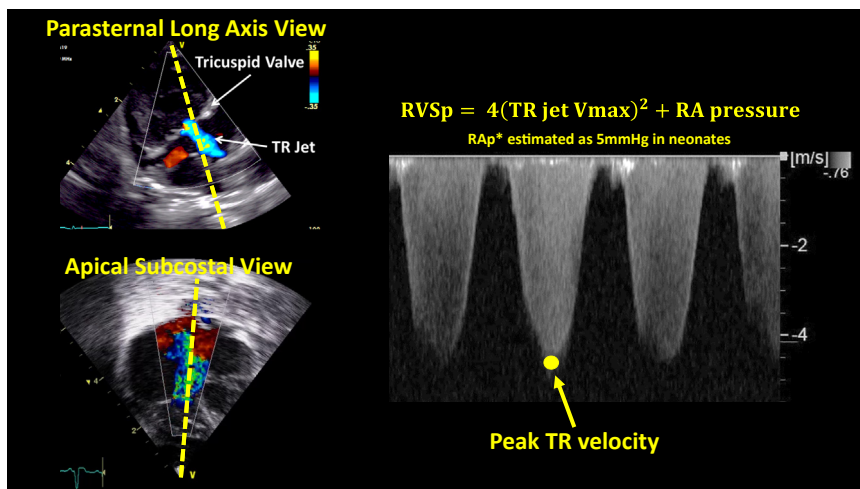


**Figure 14** PAP measurement on the basis of pulsed-wave Doppler from the parasternal long-axis view. *mPAP*, Mean pulmonary artery pressure; *PADP*, PA diastolic pressure; *PADV*, PA diastolic velocity; *RAp*, right atrial pressure; *RVSp*, RV systolic pressure.

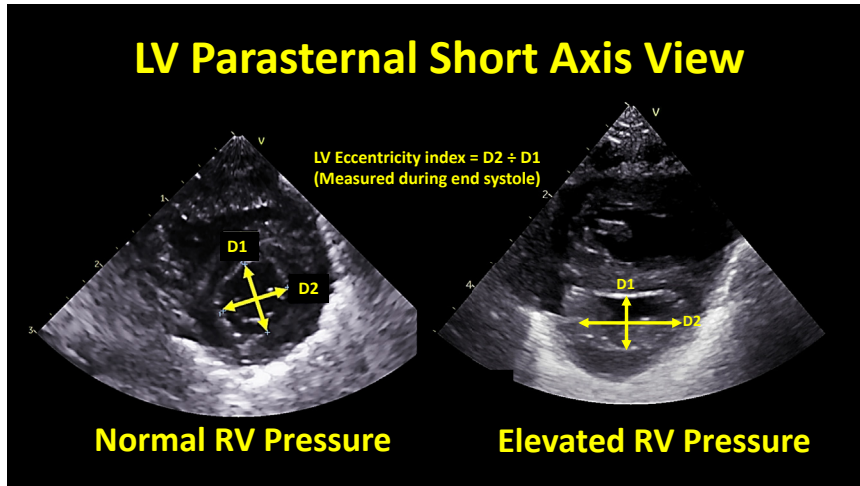
afterload stress on the right ventricle. Second, the right ventricle is vulnerable to simultaneous ischemic injury because of its prominent role in the transitional circulation<sup>88</sup> and has a greater ratio of circumferential radius to wall thickness<sup>89</sup> and lower coronary perfusion pressure in the presence of high central venous pressure.<sup>90</sup> In addition to some degree of primary injury, the left ventricle may be compromised because of impaired preload, ventricular interdependence (a secondary impact due to shared muscle fibers), or via ventriculoventricular interaction (impact of a pressure- and volume-loaded right ventricle on LV compliance, filling, and size). The ductal shunt may be an important modulator of either systemic or pulmonary blood flow in patients with univentricular dysfunction. Therapeutic hypothermia

results in peripheral vasoconstriction, which may mask hypoperfusion. In addition, other biochemical markers of cardiovascular health are difficult to interpret following a hypoxic-ischemic event<sup>91</sup> because of the primary hypoxic-ischemic insult. RV dysfunction and PH may be present despite relatively subtle clinical symptoms.

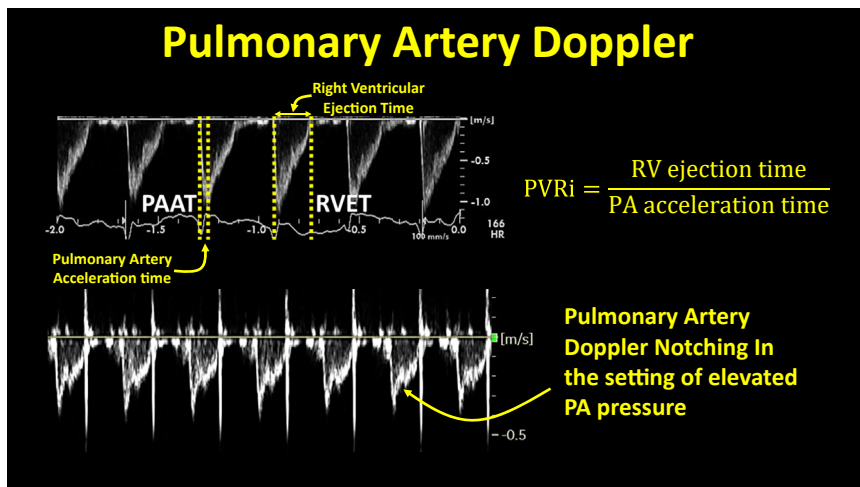
**Indications for Echocardiography.** All infants with HIE who present with cardiovascular instability or hypoxemic respiratory failure, and/or require vasoactive agents, should undergo timely standard TNE. Screening echocardiography may be beneficial because of the poor reliability of common markers of systemic perfusion (e.g., elevated lactate, decreased urinary output).<sup>92-94</sup> It is essential to



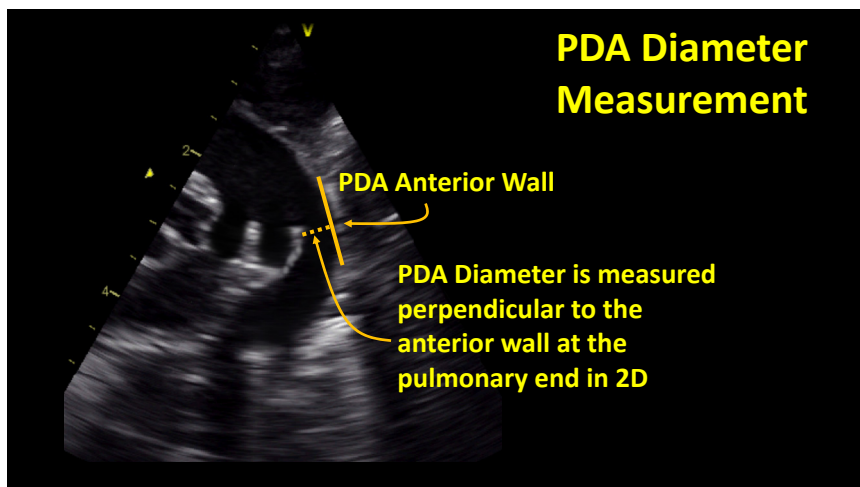
**Figure 15** RV systolic pressure measurement on the basis of continuous-wave Doppler from the apical four-chamber view. *RA*, Right atrial; *RVSp*, RV systolic pressure.



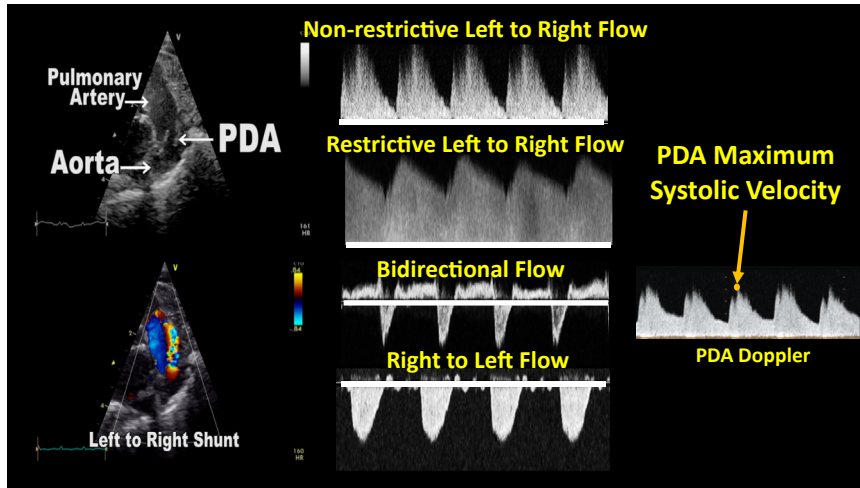
**Figure 16** LV EI from the parasternal short-axis view at the level of the papillary muscle just distal to MV leaflets.



**Figure 17** PVR index (PVRi) on the basis of pulsed-wave Doppler from the parasternal long-axis view. PVRi may be calculated as either RVET:PAAT (normal, <4.0) or PAAT/ RVET (normal, <0.25) according to institutional standards.



**Figure 18** PDA diameter measurement estimated from the suprasternal view.



**Figure 19** Pulsed-wave Doppler interrogation of PDA flow from the suprasternal view.

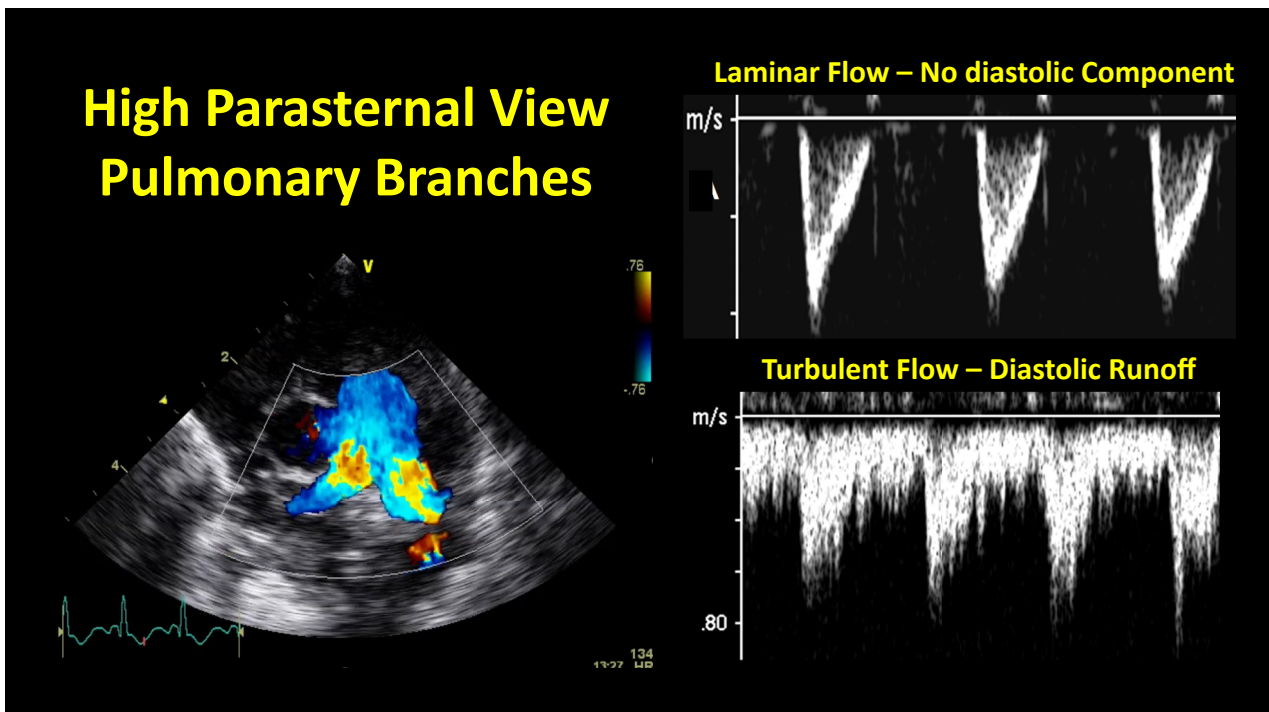
rule out duct-dependent CHD, in addition to evaluating for the consequences of perinatal hypoxia-ischemia.

*Imaging Techniques and Guidance of Clinical Decision-Making.* It is preferable that TNE evaluation take place as early in the hospitalization as is feasible. Multiple reassessments may be required to guide therapy in acutely unstable patients. Particular attention to measures of RV performance, PAP and ductal shunt directionality are recommended (Table 5). A right-to-left ductal shunt should also prompt consideration of duct-dependent SBF (e.g., LV dysfunction). The presence of a left-to-right atrial shunt is further suggestive of a left heart systolic dysfunction. Comprehensive evaluation including objective metrics of RV performance should be performed.

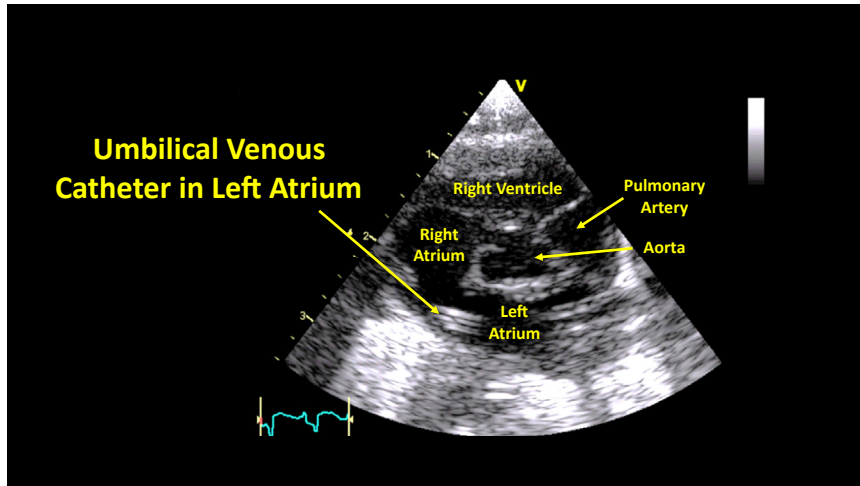
**Recommendations**

Infants with HIE and hemodynamic instability and/or oxygenation failure should undergo standard TNE as soon as feasible to appraise pulmonary pressures, myocardial function, and cardiac output. Hemodynamically stable patients with moderate to severe HIE may benefit from screening to evaluate for subclinical disease and support prognostication.

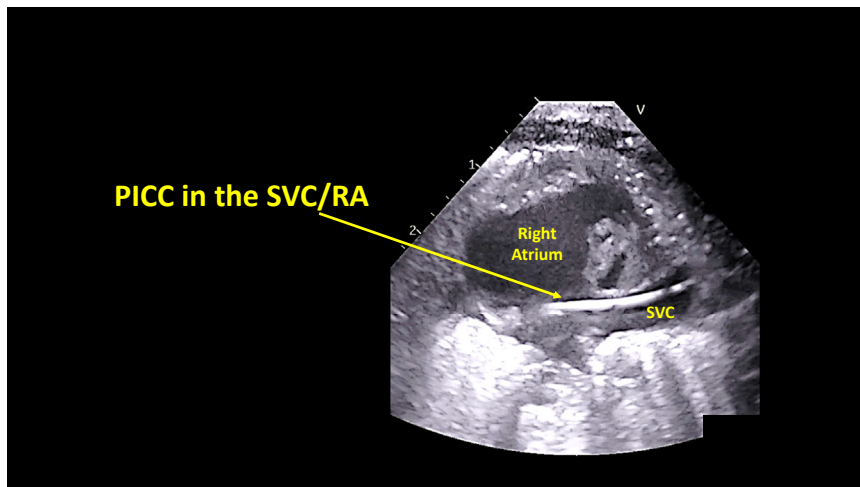
*Infant of Diabetic Mother. Pathophysiology and Mechanistic Phenotypes.* Infants of diabetic mothers (IDMs) may present with different cardiac phenotypes, including CHD, cardiac muscle



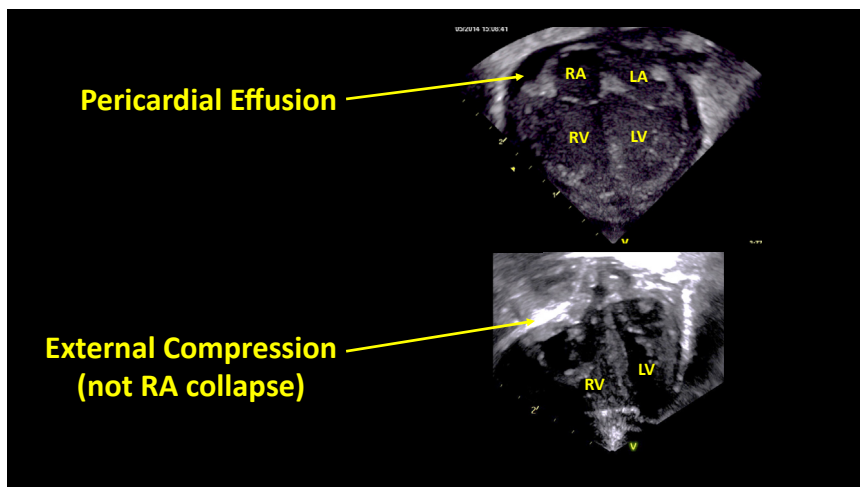
**Figure 20** Pulmonary branch artery velocity from the high parasternal view.



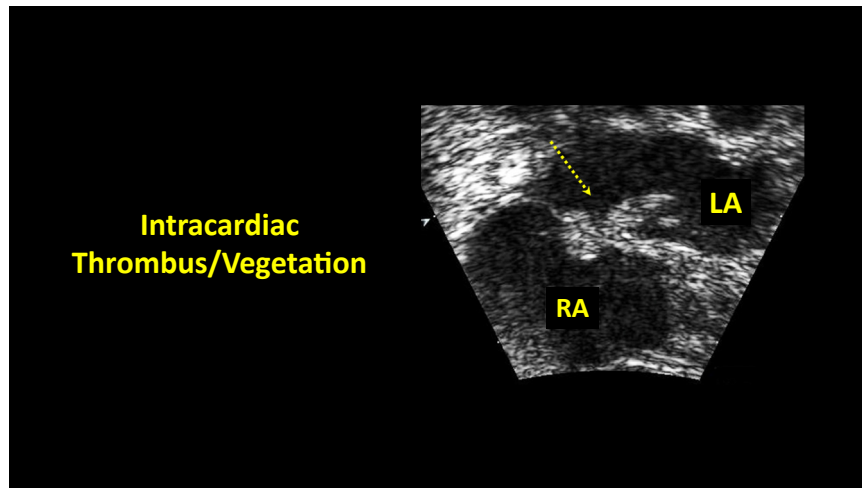
**Figure 21** Interrogation of UVC tip position from the subcostal short-axis view.



**Figure 22** Interrogation of PICC tip from the high parasternal view. RA, Right atrium; SVC, superior vena cava.



**Figure 23** Pericardial effusion and tamponade.



**Figure 24** Image of intracardiac thrombus and vegetation from the subcostal view. RA, Right atrium.

hypertrophy disorders, and/or disturbances of cardiovascular and pulmonary adaptation after birth.<sup>95</sup> The most common pathology is asymmetrical septal hypertrophy (an anabolic result of fetal hyperinsulinemia triggered by maternal hyperglycemia).<sup>96</sup> Myocardial hypertrophy can extend beyond the septum and involve the free walls symmetrically. As the right and left posterior walls can become thickened diastolic dysfunction in the setting of normal systolic function may ensue.<sup>97</sup> Further hypertrophy may obstruct the LV outflow tract and leads to impaired muscle relaxation and diastolic filling, decreased SBF, and decreased cardiac output. The severe form of the diabetic cardiomyopathy may also lead to decreased pulmonary blood flow and reduced pulmonary venous return presenting clinically with hypoxemia. Additionally, fetal hyperinsulinemia can transiently delay surfactant synthesis and secretion leading to persistent elevation of pulmonary pressures and vascular resistance during the immediate postnatal period.<sup>95</sup> Although most of the alterations in cardiac morphology and systemic or pulmonary hemodynamics appear to resolve during the first 2 to 4 weeks after birth,<sup>98-101</sup> some patients have persistent functional abnormalities beyond 1 month.<sup>102</sup>

**Indications for Echocardiography.** Clinical phenotypes relate directly to the degree of dynamic obstruction to the LV outflow tract, diastolic and eventual systolic dysfunction, and impact on the pulmonary vasculature. In the setting of a presumed low-cardiac output state (cyanosis, tachypnoea, tachycardia, and cardiomegaly) or PH (increase oxygen requirement, BP lability), TNE is used to detect the different presentations of cardiopulmonary compromise in IDM and facilitate appropriate therapeutic intervention.

**Imaging Techniques and Guidance of Clinical Decision-Making.** TNE assessment of an IDM with suspected hypertrophic cardiomyopathy and/or PH includes evaluation of chamber dimensions, heart function, and pulmonary pressures, with special attention paid toward the septum and its relationship to the LV outflow tract and degree of obstruction (Table 5). The increase in basal septal thickness may lead to apposition of the anterior leaflet of the MV to the interventricular septum during systole leading to dynamic LV outflow tract obstruction. RV morphology is assessed by both linear dimensions and RV areas acquired at end-diastole and end-systole from the RV-focused apical four-chamber view. RV and LV systolic and diastolic function

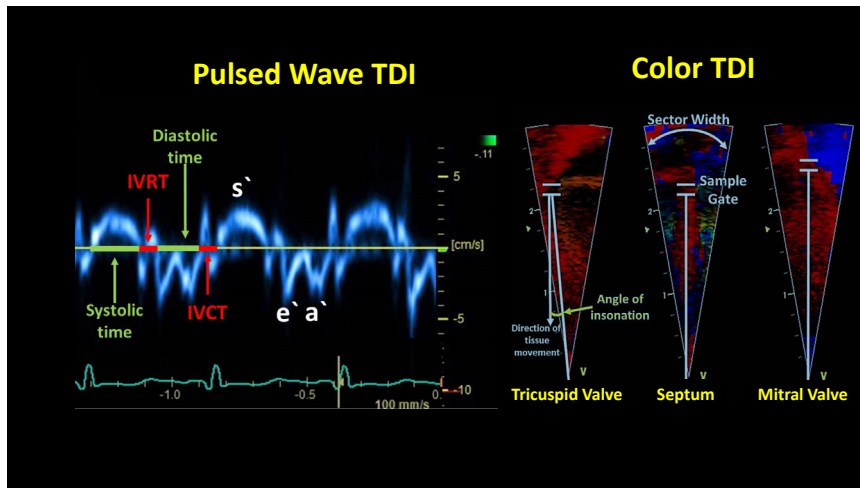
are evaluated as previously described. Note that left and right cardiac output calculations may be unreliable in the presence of outflow tract obstruction and influenced by shunts. Torsion and LV longitudinal systolic strain by STE may be impaired in IDMs during the transitional period,<sup>103</sup> even with preserved EF, suggesting that rotational mechanics may offer a more sensitive measure of ventricular function.<sup>104</sup> Although septal wall thickness may normalize by 1 month of age, abnormal global and segmental systolic and diastolic strain values may persist.<sup>102</sup>

## Recommendations

In IDMs with clinical signs of low cardiac output or PH, standard TNE should be performed to exclude CHD and evaluate the degree of dynamic obstruction to the LV outflow tract, diastolic and systolic dysfunction, and impact on the pulmonary vasculature.

**Twin-to-Twin Transfusion Syndrome. Pathophysiology and Mechanistic Phenotypes.** Twin-to-twin transfusion syndrome (TTTS) affects approximately 10% to 15% of monochorionic-diamniotic pregnancies and is a significant contributor to perinatal morbidity and mortality.<sup>105</sup> The resultant myocardial functional and structural phenotypes are poorly understood but may stem from the presence of placental anastomoses leading to a distinct clinical phenotype. Chronic hypovolemia and growth restriction complicates the donor twin, while chronic fluid overload, hydrops, and an adverse afterload environment are hallmarks of the recipient twin.<sup>106,107</sup> If left untreated, the mortality rate can approach 100% in one or both fetuses with most survivors experiencing significant morbidity including adverse neurodevelopmental outcomes.<sup>108</sup> Treatment of TTTS with selective laser photocoagulation of the communicating placental vessels (SLPCV) improves survival and cardiovascular outcomes by alleviating, or at least mitigating, the abnormal circulatory load and cardiac morbidity.<sup>109,110</sup> There is an increased incidence of structural valvular disease in affected fetuses including tricuspid, mitral, and most commonly pulmonary valves occurring predominantly in the recipient twin.<sup>111</sup> TTTS results in a cardiomyopathy, occurring predominantly in recipient twins, that is only partially understood; specifically, recipient monochorionic-diamniotic twins with TTTS who do





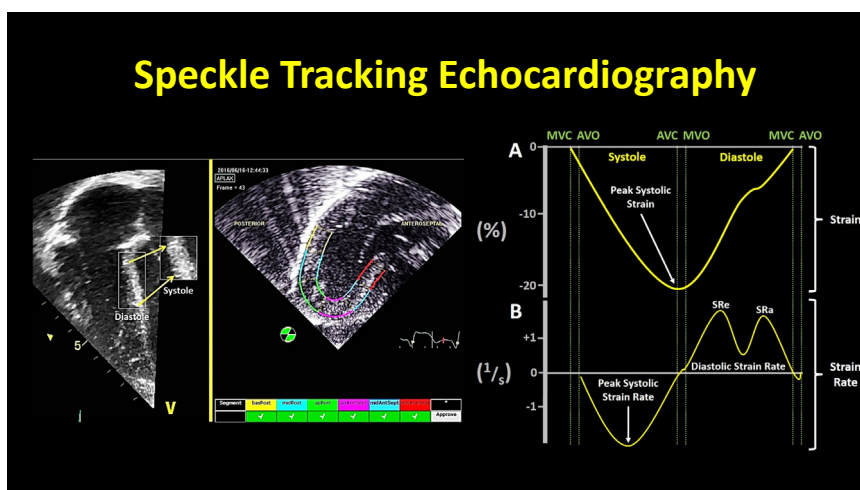
**Figure 25** Doppler tissue imaging. *IVCT*, Isovolumetric contraction time.

not undergo SLPCV exhibit persistent myocardial hypertrophy and systolic dysfunction, over the first postnatal week. A reduction in both strain and strain rate STE measurements suggest a multifactorial etiology for the dysfunction including adverse loading conditions and impaired contractility.<sup>112</sup> In addition, ventricular hypertrophy and placentally derived renin-angiotensin system effectors and discordant endothelin are important contributors to diastolic dysfunction in recipient fetuses that can precede systolic function.<sup>113,114</sup> This dysfunction can persist postnatally, especially in infants with TTTS who did not undergo SLPCV.

**Indications for Echocardiography.** Structural heart disease and the acquired cardiomyopathy leading to adverse functional and morphologic changes are evolving processes that can extend into the postnatal period. Detailed structural, functional, and morphologic evaluation is therefore recommended to correlate findings with the clinical course, guide therapy, and monitor treatment. If neonatologist-performed TNE is the first patient evaluation, the study should be reviewed by a pediatric cardiologist or a comprehensive pediatric echocardiography study should be obtained after to appraise the anatomy. Infants with persistent functional and/or structural ab-

normalities at discharge require long-term pediatric cardiology follow-up. This approach should be implemented in all TTTS infants, regardless of SLPCV treatment, as it may prove beneficial to identify the long-standing sequelae of cardiomyopathy induced by the syndrome.

**Imaging Techniques and Guidance of Clinical Decision-Making.** Standard TNE examination of infants with TTTS should include the essential views and sweeps to enable structural assessment with close attention given to valvar disease, especially the pulmonary valve of the recipient twin (Table 5). Repeat assessments are recommended due to the dynamic and evolving nature of the condition. Special attention should be paid to linear and morphologic measurements of the left and right ventricles including cavity dimensions. Assessment of pulmonary hemodynamics and surrogates of RV afterload including PAAT or RVET: PAAT index, LV EI, tricuspid valve regurgitant jet velocity (if present), and PDA shunt characteristics are helpful in characterizing pulmonary hemodynamics. Biventricular functional assessment is also recommended to include EF, Doppler tissue imaging, and deformation analysis. The use of both strain and strain rate techniques may aid in the determination of the underlying



**Figure 26** STE. *AVO*, Aortic valve opening; *AVC*, aortic valve closure; *MVC*, MV closure; *MVO*, MV opening.

**Table 4** Mandatory anatomic surveillance components of comprehensive TNE scan

Echocardiography view	First study	Subsequent scans
Situs and position of the heart in the thorax	✓	
Systemic venous return to the RA (IVC/SVC)	✓	
Left and right atrial size and shape	✓	✓
Interatrial septum, PFO, ASD, direction of shunting	✓	✓
AV valve morphology	✓	
Atrioventricular concordance	✓	
Presence of AV regurgitation/flow acceleration	✓	✓
Ventricular chamber size and shape	✓	✓
Presence or absence of VSDs (sweeps required)	✓	✓
LV and RV outflow tract obstruction	✓	✓
Ventricular-arterial concordance	✓	
Aortic and pulmonary valve morphology	✓	
Presence of aortic and pulmonary valve regurgitation	✓	✓
AV leaflets and coronary origins	✓	
Branch PA size and flow	✓	✓
Presence/absence of PDA and shunt	✓	✓
Aortic arch sidedness	✓	✓*
Arch patency	✓	✓
Pulmonary venous drainage into left atrium	✓	

ASD, Atrial septal defect; AV, aortic valve; IVC, inferior vena cava; PFO, patent foramen ovale; RA, right atrium; SVC, superior vena cava; VSD, ventricular septal defect.

\*Sidedness should be re-confirmed at the time of PDA surgical ligation or percutaneous device closure.

etiology of dysfunction and contribution of loading conditions vs intrinsic contractility.<sup>115</sup>

## Recommendations

Infants with TTTS, regardless of antenatal treatment with SLPCV, should undergo standard TNE assessments to identify pulmonary or systemic hemodynamics, characterize loading conditions and assess myocardial performance.

700.<sup>116</sup> Approximately 50% of babies with DS will have some form of CHD, the most common being atrioventricular septal defects, followed by ventricular septal defects. PH is also extremely common during the early neonatal period with recent literature suggesting an incidence approaching 40%; however, this is likely to be an underestimate, as the data were obtained from retrospective studies using nonstandardized clinical and echocardiographic diagnostic criteria.<sup>117</sup> PH in infants with DS is multifactorial and may be characterized by reduced alveolarization, decreased vessel density, persistence of the double-capillary network, hypertensive arterial remodeling, blunted response to nitric oxide, and the presence of CHD.<sup>118-120</sup> In addition, LV diastolic dysfunction and resultant increased LA pressure leads to pulmonary venous hypertension, which plays a role in the evolution of secondary arterial PH.<sup>121</sup> Infants with DS are also at increased risk for LV and RV dysfunction which is evident during fetal life and persists throughout the neonatal period and into adulthood.<sup>121-125</sup>

**Indications for Echocardiography.** All symptomatic infants with a confirmed or suspected diagnosis of DS, and low clinical suspicion for CHD, may undergo comprehensive TNE evaluation to assess structural integrity, determine the presence of PH, and evaluate myocardial performance.<sup>126</sup> At centers with immediate access to pediatric echocardiography laboratory services, a complete echocardiography assessment and pediatric cardiology consultation is recommended. Ongoing follow-up is determined by the findings on the initial TNE assessment; however, regular inpatient follow-up should be considered to assess the evolution of pulmonary hemodynamics.

**Imaging Techniques and Guidance of Clinical Decision-Making.** If a standard TNE examination of infants with DS is the first patient assessment, it should include the essential views and sweeps to enable structural assessment with close attention given to the presence of atrioventricular septal defects (Table 5). If neonatologist-performed TNE is the first patient evaluation, the study should be reviewed by a pediatric cardiologist or a comprehensive pediatric echocardiography study should be obtained after to appraise the anatomy. Special attention should be paid to pulmonary hemodynamics, indices of LV and RV function, and cavity dimensions. Assessment of pulmonary hemodynamics and surrogates of RV afterload including PAAT or RVET: PAAT index, LV EI, tricuspid valve regurgitant jet velocity if present, and PDA shunt characteristics are helpful in characterizing pulmonary hemodynamics and guiding the initiation of pulmonary vasodilator therapy. Follow-up scans to assess treatment response and plan long-term care are essential.

## Recommendations

Infants with confirmed or suspected DS should undergo standard TNE assessment soon after delivery to assess structural integrity, presence of PH, and adequacy of myocardial performance. Postdischarge follow-up is recommended and should be determined on the basis of the initial findings.

## Clinical Scenario–Based Screening

**Neonatal Hypotension. Definition and Scope of the Problem.** Mean BP is the most common clinical parameter used to characterize systemic hypotension, and is used as a surrogate of end-organ perfusion to guide intervention.<sup>127</sup> However, there is increasing

**Infants with Down Syndrome. Pathophysiology and Mechanistic Phenotypes.** Down syndrome (DS) is the most common chromosomal abnormality of infants with a global incidence of 1 in

**Table 5** Disease-based screening and key measurements

Condition	Principles of assessment	Key measurements
PDA	<ul style="list-style-type: none"> <li>Evaluate PDA characteristics</li> <li>Identify pulmonary overcirculation</li> <li>Measure systemic hypoperfusion</li> <li>Rule out moderate-severe RV or LV systolic dysfunction</li> <li>Rule out CHD and ductal-dependent lesions</li> </ul>	<ul style="list-style-type: none"> <li>PDA size, pressure gradient, and shunt direction</li> <li>Pulmonary vein diastolic wave <math>V_{max}</math>, LA/Ao, LVO (or LVO/RVO), E/A ratio, IVRT, LVEDD</li> <li>Postductal aortic, celiac and middle cerebral artery diastolic flow (absent, reversed)</li> <li>LVEF/RV FAC/TAPSE</li> </ul>
PH/acute hypoxemia	<ul style="list-style-type: none"> <li>Appraise pulmonary hemodynamics (differentiate flow-driven from resistance-driven PH)</li> <li>Assess RV systolic and diastolic function</li> <li>Assess LV systolic and diastolic function</li> <li>Exclude CHD and ductal-dependent lesions</li> </ul>	<ul style="list-style-type: none"> <li>PDA flow direction, peak TR jet velocity, PAATi or RVET/PAAT ratio, LV end-systolic EI, pulmonary vein systolic/diastolic velocity</li> <li>RV FAC; TAPSE; RVO; DTI <math>s'</math>, <math>e'</math>, <math>a'</math> (consider strain/SR)</li> <li>LVEF; LVO, E/A ratio; IVRT; DTI <math>s'</math>, <math>e'</math>, <math>a'</math></li> <li>Pulmonary vein Doppler in chronic PH</li> </ul>
Systemic hypotension	<ul style="list-style-type: none"> <li>Assess LV and RV systolic function</li> <li>Assessment of preload/afterload</li> <li>Characterize intra- and extracardiac shunts</li> <li>Assess LV and RV morphology</li> <li>Rule out CHD</li> </ul>	<ul style="list-style-type: none"> <li>LVEF, LVO, IVRT, RV FAC, TAPSE, RVO</li> <li>IVC collapsibility, tissue Doppler-measured systolic and diastolic time intervals</li> <li>PFO, VSD, PDA assessment (see above)</li> <li>LVPWd and IVSd (M-mode imaging of LV)</li> <li>Images/views to exclude obstructive left heart disease including coarctation are critical</li> </ul>
HIE	<ul style="list-style-type: none"> <li>Assess RV systolic function</li> <li>Assess LV systolic and diastolic function</li> <li>Assess pulmonary hemodynamics</li> <li>Rule out CHD</li> </ul>	<ul style="list-style-type: none"> <li>RV FAC; TAPSE; RVO; DTI <math>s'</math>, <math>e'</math>, <math>a'</math> (consider RV free wall strain)</li> <li>LVEF; LVO; E/A ratio; IVRT; DTI <math>s'</math>, <math>e'</math>, <math>a'</math> (consider strain/SR)</li> <li>PDA flow direction, peak TR jet velocity, PAATi or RVET/PAAT, LV end-systolic EI, pulmonary vein peak systolic/diastolic velocity</li> <li>Images/views to exclude obstructive left heart disease including coarctation are critical</li> </ul>
IDM	<ul style="list-style-type: none"> <li>Assessment of LV hypertrophy</li> <li>Quantify obstructive left heart disease</li> <li>Appraise LV diastolic function</li> <li>Assess pulmonary hemodynamics</li> </ul>	<ul style="list-style-type: none"> <li>LVPWd and IVSd (M-mode imaging of LV)</li> <li>LVOT flow velocity (continuous-wave Doppler)</li> <li>RV morphology (subjective appraisal)</li> <li>LV E/A ratio, IVRT</li> <li>PDA flow direction, peak TR jet velocity, PAATi or RVET/PAAT, LV end-systolic EI, pulmonary vein peak systolic/diastolic velocity</li> </ul>
TTS	<ul style="list-style-type: none"> <li>Cardiomyopathy/hypertrophy in recipient</li> <li>Assess LV diastolic dysfunction in donor</li> <li>Assess pulmonary hemodynamics</li> <li>Valvular disease, especially pulmonary stenosis</li> </ul>	<ul style="list-style-type: none"> <li>LVPWd and IVSd (M-mode imaging of LV)</li> <li>LV E/A ratio, IVRT</li> <li>PDA flow direction, peak TR jet velocity, PAATi or RVET/PAAT, LV end-systolic EI, pulmonary vein peak systolic/diastolic velocity</li> <li>RV morphology (subjective appraisal)</li> <li>RVOT and LVOT flow velocity; requires serial assessments</li> </ul>
DS	<ul style="list-style-type: none"> <li>Characterize CHD</li> <li>Assess pulmonary hemodynamics</li> <li>Assess LV and RV function</li> </ul>	<ul style="list-style-type: none"> <li>Focus on interatrial/interventricular septal defects</li> <li>PDA flow direction, peak TR jet velocity, PAATi or RVET/PAAT, LV end-systolic EI, pulmonary vein peak systolic/diastolic velocity</li> <li>LVEF; LVO; E/A ratio; IVRT; DTI <math>s'</math>, <math>e'</math>, <math>a'</math> (consider strain/SR)</li> <li>RV FAC; TAPSE; RVO; DTI <math>s'</math>, <math>e'</math>, <math>a'</math> (consider RV free wall strain)</li> </ul>

Ao, Aorta; DTI, Doppler tissue imaging; IVC, inferior vena cava; IVSd, interventricular septal wall thickness at end-diastole; LVEDD, LV end-diastolic dimension; LVOT, LVOT outflow tract; LVPWd, LV posterior wall thickness at end-diastole; PAATi, pulmonary artery acceleration time corrected for heart rate; PFO, patent foramen ovale; RVOT, right ventricular outflow tract; SR, strain rate;  $V_{max}$ , peak velocity; VSD, ventricular septal defect.

**Table 6** Knowledge elements for training in neonatal hemodynamics and TNE

Domain	Specific knowledge elements
1. Cardiovascular anatomy and physiology	<ol style="list-style-type: none"> <li>1. Normal and abnormal structure of the heart</li> <li>2. Components and determinants of cardiac output               <ol style="list-style-type: none"> <li>a. Determinants of preload, contractility, and afterload</li> <li>b. Frank-Starling, stress-velocity, and force-frequency relationships</li> <li>c. Systemic vascular function curves</li> <li>d. Ventricular pressure-volume loops</li> </ol> </li> <li>3. Myocardial oxygen supply and demand</li> <li>4. Physiology of intra- and extracardiac shunts</li> <li>5. Peripheral circulation               <ol style="list-style-type: none"> <li>a. BP and volume, including neuro-hormonal control, cardiac reflexes, and baroreceptors</li> <li>b. Mixed venous oxygen saturation and the relationship of venous oxygenation and cellular metabolism</li> <li>c. Fick principle and applications to mixed venous oxygen saturation</li> </ol> </li> <li>6. Regional circulation               <ol style="list-style-type: none"> <li>a. Starling forces and fluid exchange in the microcirculation</li> <li>b. Systemic and cerebral autoregulation in preterm and term neonates</li> </ol> </li> </ol>
2. Pulmonary physiology	<ol style="list-style-type: none"> <li>1. Physiology of the pulmonary circulation in neonates               <ol style="list-style-type: none"> <li>a. Normal transition from fetal to postnatal life including physiology of the normal postnatal increase in pulmonary blood flow</li> <li>b. Pathophysiology of impairment in postnatal pulmonary blood flow and potential therapeutic targets</li> </ol> </li> <li>2. Influence of positive pressure ventilation on systemic and pulmonary hemodynamics</li> </ol>
3. Disease states: etiology and pathophysiology	<ol style="list-style-type: none"> <li>1. PDA in preterm neonates, including post-PDA closure syndrome</li> <li>2. Shock (all types)</li> <li>3. Acute PH secondary to               <ol style="list-style-type: none"> <li>a. Parenchymal lung disease, including pulmonary hypoplasia</li> <li>b. Pulmonary venous hypertension, including LV diastolic and/or systolic dysfunction</li> <li>c. Lesions with increased pulmonary blood flow, including cardiac shunts and arteriovenous malformations</li> <li>d. Idiopathic PA hypertension</li> </ol> </li> <li>4. Chronic PH, including due to left heart disease, pulmonary disease, or increased pulmonary blood flow from cardiac shunts</li> <li>5. Pericardial effusion and tamponade</li> <li>6. Hemodynamic consequences of perinatal and postnatal HIE</li> <li>7. Systemic hypertension and hypotension</li> </ol>
4. Diagnostics and monitoring	<ol style="list-style-type: none"> <li>1. Laboratory               <ol style="list-style-type: none"> <li>a. Biochemical measures of end-organ perfusion</li> <li>b. Biomarkers of cardiac volume and pressure loading</li> </ol> </li> <li>2. Non-sonographic measurements of cardiac output, including bioimpedance- and bioreactance-based tools</li> <li>3. Invasive catheter measurements, including central venous catheterization and diagnostic and therapeutic cardiac catheterizations</li> <li>4. Near-infrared spectroscopy</li> </ol>
5. Principles of echocardiography in the neonate	<ol style="list-style-type: none"> <li>1. Biologic effects and safety of echocardiography</li> <li>2. Principles of physics (including equations) and instrumentation of echocardiography, including M-mode, two-dimensional, and blood and tissue Doppler echocardiography</li> <li>3. Indications, strengths, limitations, and clinical utility of transthoracic echocardiography</li> <li>4. Common ultrasound artifacts and their identifying echocardiographic features</li> <li>5. Echocardiographic appearance and normal variants of cardiac structures, including cardiac chambers, valves, pericardium, and major blood vessels</li> <li>6. Echocardiographic appearance of abnormal cardiac structures and cardiac function in disease states</li> <li>7. Appearance and positioning of central arterial and venous catheters</li> </ol>

*(Continued)*

**Table 6** (Continued)

Domain	Specific knowledge elements
6. Therapeutics	<ol style="list-style-type: none"> <li>8. Maturity-based normative data for echocardiographic indices of cardiac function in healthy neonates and within the spectrum of hemodynamic disturbance</li> <li>9. Diagnostic test characteristics of echocardiographic measurements, including reliability, reproducibility, and measures of predictive accuracy</li> <li>1. Mechanism of action and indications for common hemodynamic treatments including               <ol style="list-style-type: none"> <li>a. Inotropic medications</li> <li>b. Vasopressor medications</li> <li>c. Systemic vasodilator medications</li> <li>d. Prostaglandins</li> <li>e. Pulmonary vasodilator medications (including inhaled nitric oxide)</li> </ol> </li> <li>2. Volume expanders</li> <li>3. Diuretics</li> <li>4. Management of PDA, including indications for and selection of conservative management, medications, and device or surgical closure</li> <li>5. Cardiopulmonary interactions and titration of mechanical ventilation and other methods of respiratory support in the neonate with hemodynamic instability</li> </ol>

recognition that BP, as the dependent variable defining organ perfusion, is only one of the end points of interest. Furthermore, there are several recognized limitations with the use of BP to monitor and treat low-blood flow states in preterm and term infants, including the lack of robust normative data sets,<sup>127</sup> dissociation between BP and SBF,<sup>42</sup> and overreliance on singular estimates of mean BP rather than systolic and diastolic BPs separately.<sup>128</sup> The relationship between hypotension, cerebral perfusion, and adverse neurodevelopmental sequelae is therefore questionable.

Neonatal sepsis is a common cause of both compensated (normal BP) and uncompensated shock. Sepsis affects myocardial contractility either directly or through ventricular-ventricular interaction with the left ventricle, contributing to further deterioration. Vasodilatory shock and capillary leak may both be present in sepsis and contribute to low RV preload and low pulmonary blood flow which may mimic acute PH physiology.<sup>129</sup> A similar pattern is observed in necrotizing enterocolitis, which can also result in vasoactive shock attributable to the release of cytokines and the alteration in endothelial function.

**Indications for Echocardiography.** In any neonate presenting with signs of hypotension and clinical signs of a low-cardiac output state (especially in premature infants during the transitional period), standard TNE should be considered to characterize the underlying physiology and recognize deviations from normal anatomy. In the absence of structural heart disease, standard TNE can be used in the management of hypotension and shock because it can be helpful in identifying the underlying mechanisms.

**Imaging Techniques and Guidance of Clinical Decision-Making.** Assessment of myocardial performance in neonates with low systolic BP should include evaluation of left and right heart function and morphology (Table 5). TNE can be used to measure cardiac output in critically ill newborn infants,<sup>16-18,130</sup> which may enhance the interpretation of BP. The calculations of RVO and LVO provide estimates of pulmonary and SBF, respectively; however, in the presence of fetal shunts, measurements of RVO and LVO are not a direct estimate of pulmonary or SBF. Morphologic measures can provide diagnostic clues for evidence of hypertrophy and dilation associated with cardiomyopathies unrelated to CHD.<sup>95</sup> For the right ventricle, structural as-

sessments should include measures of areas (end-systolic and end-diastolic), cavity dimensions at the base, midcavity, and length of the right ventricle from the apex to the middle of the base in the RV-focused apical four-chamber view. RV outflow dimensions can be obtained from either the parasternal long-axis or short-axis view to assess the proximal and distal components of the RV outflow tract. For the left ventricle, morphologic assessment should include relative wall thickness, LV mass, volume, and linear dimensions. Characterization of the hemodynamic significance of a PDA is essential because of its contribution to transitional systemic hypotension.

## Recommendations

Standard TNE might provide additional diagnostic information regarding causality and guide medical management in hypotensive neonates or those with suspected low-cardiac output state. TNE should be considered in any neonate who presents with sepsis-like symptoms, especially in the setting of a known maternal viral prodrome. These infants should be serially monitored for cardiomyopathy, arrhythmias, and potential circulatory collapse.

**The Hypoxemic Infant. Scope of the Problem and Differential Diagnosis.** Neonatal hypoxemia can result in decreased tissue oxygen delivery and metabolic acidosis. Hypoxemia can result from multiple etiologies, including intracardiac right to left shunts and/or intrapulmonary shunt secondary to ventilation-perfusion mismatch.<sup>131</sup> The differential diagnosis for hypoxemia in an infant includes CHD with compromised pulmonary blood flow; lung disease due to conditions such as pneumonia, pneumothorax, and meconium aspiration syndrome; and acute PH due to sepsis, HIE, CDH, or diagnoses such as trisomy 21 and IDM. In any neonate with hypoxemia, it is imperative to rule out CHD, especially conditions which require acute intervention (e.g., transposition of the great vessels with intact atrial septum, obstructed pulmonary venous return). In a structurally normal heart, TNE evaluation of patients with presumed PH may aid quantification of the severity of PH, appraisal of RV function, and the adequacy of

pulmonary and systemic hemodynamics. If no PDA is present, RV failure may result, as well as LV diastolic dysfunction through ventricular-ventricular interactions. In addition, exposure to prolonged hypoxia may contribute to LV diastolic dysfunction.

**Role of Echocardiography in Aiding Clinical Assessment.** Standard TNE is indicated to differentiate the etiology of hypoxemia and to direct management in a patient with a structurally normal heart. If standard TNE is the first patient evaluation it should include the essential views and sweeps to rule out the presence of CHD. Infants with cyanotic CHD will be hypoxemic but will not necessarily be hypoxic, and will continue to be closely monitored for signs of suboptimal tissue oxygenation. Longitudinal TNE evaluation may be useful to monitor changes in PAP, RV or LV function, and indices of pulmonary or SBF after therapeutic intervention.

**Role of Echocardiography in Guiding Therapeutic Interventions.** Once the etiology of hypoxemia is determined, echocardiography can guide initial intervention as well as provide longitudinal assessment as physiology changes. Assessment of PH by echocardiography includes assessment of pulmonary pressures and PVR, presence and direction of atrial and ductal shunt, as well as RV and LV functional assessment (Table 5). Elevated right-sided pressures can be evaluated through measurement of TR to estimate RV systolic pressure, PI jet to estimate mean PAP, and systolic EI  $> 1$ .<sup>33</sup> Systolic time intervals of the right ventricle may provide valuable information on PVR, with emerging literature on measurements such as PAAT.<sup>62,132</sup> Finally, measurements such as TAPSE or RV FAC, myocardial performance index, MV inflow ratios, LVO, and RV and LV strain may enhance diagnostic capabilities. Shunting patterns may aid diagnostic appraisal, especially in patients with CDH; specifically, atrial shunting is reflective of RV and LV compliance, whereas a right-to-left or bidirectional ( $>30\%$  right-to-left) PDA shunt suggests elevated PAP.

## Recommendation

In a patient with hypoxemia, standard TNE is important to facilitate diagnostic appraisal, guide the institution of pulmonary vasodilators, inotropes or vasoactive agents, and enable rapid triage of patients for pediatric cardiology review when anatomic abnormalities are unexpectedly identified. Longitudinal hemodynamic assessment with echocardiography can guide monitoring and refinement of therapeutic intervention.

**Noncardiac Congenital Anomalies. Definition and Scope of the Problem.** Noncardiac congenital anomalies comprise  $\geq 10\%$  of NICU admissions and can be categorized as malformations, deformations, and disruptions.<sup>133</sup> Patients with congenital anomalies represent a subgroup with high rate of morbidity and mortality.<sup>51</sup> There is increasing evidence that patients with CDH, occurring in approximately 1 in 3,000 live births, may have a variable underlying phenotype that affects morbidity and mortality; specifically, pulmonary hypoplasia with varying degrees of PH and RV dysfunction or LV hypoplasia leading to pulmonary venous hypertension have both been reported.<sup>52</sup> Early differentiation of the specific phenotype is important to ensure the basis for treatment is based on the underlying physiology. In patients with omphalocele, echocardiography aids the identification of associated CHD and/or PH. Vein of Galen malforma-

tion, a congenital brain arteriovenous fistula, can lead to high-output cardiac failure in the neonate, with high morbidity and mortality.<sup>53</sup> Of note, patients with vein of Galen malformation can develop PH which may either be due to elevated PVR secondary to pulmonary vascular remodeling (“resistance-driven physiology”; pulmonary vasodilators are beneficial) or due to pulmonary over circulation with systemic steal (“flow-driven physiology”; pulmonary vasodilators are harmful).<sup>54</sup> TNE may enable differentiation of the specific phenotype, allowing treatment guidance.

**Role of Echocardiography in Aiding Clinical Assessment.** In patients with congenital anomalies, standard TNE with the essential views and sweeps can aid the identification of associated CHD or pulmonary vascular disorders. If neonatologist-performed TNE is the first patient evaluation, the study should be reviewed by a pediatric cardiologist or a comprehensive pediatric echocardiography study should be obtained afterward to appraise the anatomy. In a structurally normal heart, TNE augments bedside assessment to identify pathologic hemodynamic states such as PH and ventricular dysfunction.

**Role of Echocardiography in Guiding Therapeutic Interventions.** TNE aids characterization of PH in malformations such as CDH, omphalocele, and vein of Galen malformation and guides therapeutic interventions. Early screening echocardiography may be helpful in the CDH population because of the increased use of ECMO in patients with ventricular dysfunction.<sup>52</sup> Longitudinal TNE assessment may allow disease or physiology specific changes in management that positively impact the hospital course. TNE evaluation of patients with CDH, omphalocele, and vein of Galen should include assessment of PAP, biventricular size and function, arch anatomy, as well as the presence of shunts to appraise the severity of PH and its impact on heart function and systemic/pulmonary hemodynamics. PH is more pronounced in patients with giant omphalocele (defects  $>5$  cm and including the liver) with higher mortality in patients with RV dysfunction on initial echocardiography.<sup>134</sup> Thus, initial, and subsequent echocardiography should include assessment of pulmonary pressures and RV function. In vein of Galen malformation, evaluation of LVO and RVO is essential to ensure differentiation of “resistance” and “flow-driven” phenotypes because of the need for individualized treatment and the need for judiciousness in the use of selective pulmonary vasodilators.

## Recommendation

Standard TNE, which includes the essential views and sweeps to enable exclusion of major CHDs, should be performed in patients with CDH, omphalocele, and vein of Galen malformation. Longitudinal hemodynamic assessment through TNE can aid in characterizing the underlying physiology, defining phenotypes and guiding therapeutic intervention.

**Central Lines and ECMO Cannulation. Scope of the Problem.** Infants in the NICU often need central access in the form of umbilical venous catheters (UVCs) or umbilical arterial catheters or peripherally inserted central catheters (PICCs). Placement of PICC lines under ultrasound guidance has been strongly recommended for adults and children to reduce complications and increase procedural success.<sup>135</sup> In addition, ultrasound is now increasingly being used to both place and confirm the UVC tip position. This has been

**Table 7** Enabling competencies for the performance of TNE

Subtask	Enabling competencies
1. Preparation	<ol style="list-style-type: none"> <li>1. Prioritization/urgency of performance</li> <li>2. Knowledge of machine operation, including selection of probes and techniques for image optimization</li> </ol>
2. Optimize physical environment	<ol style="list-style-type: none"> <li>1. Consider patient temperature, infection prevention, stability, minimal handling, operator skill and/or experience, and limited scan time</li> <li>2. Recommend single use gel packets to minimize infection risk, especially in extremely premature babies</li> <li>3. Give appropriate attention to the neonate's comfort</li> </ol>
3. Image acquisition	<ol style="list-style-type: none"> <li>1. Select the appropriate diagnostic mode (2D, color Doppler, pulsed-wave Doppler, continuous-wave Doppler, M-mode imaging) and scanning protocol</li> <li>2. Optimize image acquisition</li> <li>3. Identify cardiac structures, including cardiac chambers, valves, pericardium, major blood vessels and indwelling catheters</li> </ol>
4. Measurement and analysis	<ol style="list-style-type: none"> <li>1. Perform measurements and calculations</li> <li>2. Use computer applications and postprocessing tools to optimize imaging analysis</li> </ol>
5. Interpretation and report	<ol style="list-style-type: none"> <li>1. Interpret measurements using appropriate normative ranges</li> <li>2. Produce a comprehensive written report of the echocardiogram taking into account the complete context of the patient</li> </ol>

2D, Two-dimensional.

shown to be more accurate and reliable than the conventionally used chest radiographs.<sup>30,136</sup> Similarly, ECMO cannulation can be routinely performed under ultrasound guidance, and ultrasound or echocardiography is a reliable and readily available modality to confirm ECMO cannula tip position.<sup>137</sup>

**Guidance on Clinical Decision-Making.** Ultrasound is the best modality to assess the accuracy of UVC and PICC line tip position: it is safe, reliable, noninvasive, and readily available and minimizes the use of ionizing radiation. cPOCUS or TNE should be used to confirm tip position of UVCs, PICC lines, and ECMO cannulas.

### Recommendations

cPOCUS or TNE should be routinely used to confirm UVC tip position after placement. Given the significant risk for migration with UVCs, it warrants surveillance imaging (while the line is in situ) to determine the accuracy of the tip position and thrombus formation. Similarly, PICC lines and ECMO cannulation should be performed under image guidance. When TNE is performed for other indications, all imaging protocols should include appraisal of indwelling catheters (where feasible) to document correct positioning.

**Screening for Pericardial Effusion. Scope of the Problem.** Pericardial effusion is not uncommon in infants being treated in the NICU. It could be part of the disease process, a sequela to cardiac surgery or a complication of central lines or catheters. Although most infants tolerate mild to moderate pericardial effusion well, some may have hemodynamic compromise, especially if the rate of accumulation is rapid, leading to cardiac tamponade.

**Guidance on Clinical Decision-Making.** cPOCUS or standard TNE should be routinely used to evaluate infants with suspected pericardial effusion or tamponade physiology or those with sudden unexplained deterioration with hemodynamic compromise. The size of

the effusion does not always align with the degree of hemodynamic significance; rather, rate of accumulation of the effusion may be a more important determinant. Dilatation of the inferior cava, RV diastolic collapse, and variability in atrioventricular valve inflow are additional signs of hemodynamic significance.

### Recommendations

Pericardial effusion should be ruled out in any infant with sudden unexplained deterioration with hemodynamic compromise, especially when a central line is in situ. This should be differentiated from pleural effusion. Pericardiocentesis should be performed under ultrasound guidance, when the pericardial effusion results in hemodynamic compromise or tamponade physiology, or occasionally for diagnostic purposes.

### TNE: TRAINING AND ACCREDITATION

Guidelines for training in TNE have historically been derived through comparisons with, and extrapolations from, guidelines for training in pediatric or adult echocardiography. Over the past decade, formal, structured training and clinical programs in neonatal hemodynamics have been developed that provide the foundation for accreditation of this subspecialty by regulatory bodies.<sup>2</sup>

#### Previously Published Guidelines for Training in TNE

The previously published (2011) guidelines on TNE covered the indications for TNE, technical aspects, specific neonatal conditions and training requirements.<sup>8</sup> In the United Kingdom, an expert consensus statement was published in 2016 with representation from both neonatology and pediatric cardiology.<sup>5</sup> Implementation of both guidelines has proven to be challenging at some centers because of the needs for training within a tertiary pediatric cardiology center. In addition, concerns have been raised that there was an

**Table 8** Enabling competencies for the provision of NHTNE consultation to the NICU

Subtask	Enabling competencies
1. Perform a patient-centered clinical assessment and establish a management plan	<ol style="list-style-type: none"> <li>1. Determine the question to be answered by TNE consultation</li> <li>2. Elicit a history, perform a physical examination, select appropriate investigations, and interpret the results for the purpose of diagnosis and management, disease prevention, and health promotion               <ol style="list-style-type: none"> <li>a. Perform TNE for the evaluation of                   <ol style="list-style-type: none"> <li>i. PDA, including post-PDA closure syndrome</li> <li>ii. Hypotension or shock</li> <li>iii. Suspected acute PH due to (1) parenchymal lung disease, including pulmonary hypoplasia; (2) pulmonary venous hypertension; (3) lesions with increased pulmonary blood flow; (4) idiopathic PA hypertension</li> <li>iv. Suspected chronic PH</li> <li>v. Pericardial effusion or tamponade</li> <li>vi. HIE</li> <li>vii. Systemic hypertension</li> <li>viii. Position of central arterial or venous catheters</li> </ol> </li> <li>b. Integrate echocardiography findings with the clinical assessment and findings of other hemodynamic studies and monitoring data</li> <li>c. Formulate a differential and most likely diagnosis on the basis of relevant findings</li> </ol> </li> <li>3. Establish a patient- and family-centered management plan               <ol style="list-style-type: none"> <li>a. Integrate knowledge of neonatal hemodynamics, cardiovascular anatomy, and imaging findings to provide consultative advice specific to the underlying indication:</li> <li>b. Provide recommendations for patient management, which may include                   <ol style="list-style-type: none"> <li>i. Initiation or titration of inotropic, vasopressor, or vasodilator medications, prostaglandins, diuretics, or volume expanders</li> <li>ii. Weaning and discontinuing medications</li> <li>iii. Management of PDA (among preterm neonates), including conservative, pharmacologic, and procedural/surgical closure</li> <li>iv. Titration of respiratory support</li> </ol> </li> </ol> </li> </ol>
2. Establish plans for ongoing care and, when appropriate, timely consultation	<ol style="list-style-type: none"> <li>1. Implement a patient-centered care plan that supports ongoing care, follow-up on investigations, response to treatment, and further consultation               <ol style="list-style-type: none"> <li>a. Provide recommendations for the timing of TNE reassessment</li> <li>b. Determine the need for and the timing of consultation with the pediatric cardiology service</li> </ol> </li> </ol>
3. Multidisciplinary communication and collaboration	<ol style="list-style-type: none"> <li>1. Actively contribute, as an individual and as a member of a team providing care, to the continuous improvement of health care quality and patient safety               <ol style="list-style-type: none"> <li>a. Recognize and respond to harm from health care delivery, including patient safety incidents</li> <li>b. Adopt strategies that promote patient safety and address human and system factors</li> </ol> </li> <li>2. Communicate using a patient-centered and family-integrated approach that encourages trust and is characterized by empathy, respect, and compassion</li> <li>3. Participate, in the role of TNE consultant, in the sharing of health care information and plans with families</li> <li>4. Work effectively with physicians and other colleagues in the health care professions               <ol style="list-style-type: none"> <li>a. Establish and maintain positive relationships and engage in respectful shared decision-making with physicians and other colleagues in the health care professions to support relationship-centered collaborative care</li> <li>b. Negotiate overlapping and shared responsibilities with physicians and other colleagues in the health care professions in episodic and ongoing care</li> <li>c. Convey information from the TNE assessment to the referring physician in a manner that enhances patient management</li> <li>d. Work within the boundaries of the consultant role</li> </ol> </li> <li>5. Hand over the care of a patient to another TNE practitioner to facilitate continuity of safe patient care</li> </ol>



**Table 9** Enabling competencies for management of an NHTNE service

Subtask	Enabling competencies
1. Equipment maintenance	<ol style="list-style-type: none"> <li>1. Demonstrate an understanding of the factors affecting the lifetime of equipment and recognize the need for replacement or additional equipment</li> <li>2. Demonstrate an understanding of the selection of equipment and process of equipment acquisition</li> </ol>
2. Reporting and image archiving	<ol style="list-style-type: none"> <li>1. Document and share written and electronic information about the medical encounter to optimize clinical decision-making, patient safety, confidentiality, and privacy               <ol style="list-style-type: none"> <li>a. Provide image capture and imaging documentation to facilitate reference to previous or subsequent imaging</li> <li>b. Store images that provide support for the diagnosis, treatment plan, and differential diagnosis for the presenting symptoms and findings</li> <li>c. Develop a written report, using appropriate terminology, summarizing all of the salient positive and negative echocardiographic findings</li> <li>d. Provide written clinical conclusions, integrating imaging and clinical data</li> </ol> </li> </ol>
3. Quality assurance	<ol style="list-style-type: none"> <li>1. Contribute to the improvement of health care delivery in teams, organizations, and systems               <ol style="list-style-type: none"> <li>a. Apply the science of quality improvement to contribute to improving the TNE system of patient care</li> <li>b. Participate in systemic quality process evaluation and improvement</li> <li>c. Analyze patient safety incidents to enhance systems of care</li> </ol> </li> <li>2. Develop, implement, and maintain a quality assurance program for TNE</li> <li>3. Participate in peer assessment and standard setting through the promotion of quality assurance by discussing TNE studies and reports with other physicians, pediatric cardiologists, and sonographers</li> </ol>
4. Leadership in health care systems	<ol style="list-style-type: none"> <li>1. Establish an effective collaborative model of care with the pediatric echocardiography laboratory and/or medical imaging department, including mechanisms for ongoing dialogue, shared imaging protocols, and clinical care strategies</li> <li>2. Develop institutional policies and/or guidelines regarding the hemodynamic evaluation and management of neonates and use of targeted echocardiography</li> <li>3. Apply knowledge of health care financing, including physician remuneration, budgeting, and organizational funding</li> <li>4. Develop and rationalize NICU policy and infrastructure to support the process of referrals for TNE consultation               <ol style="list-style-type: none"> <li>a. Identify indications for TNE consultation and guidelines regarding the timeliness of consultation</li> <li>b. Demonstrate an understanding of the clinical and administrative infrastructure for requesting TNE consultation and accessing TNE consultation reports and recommendations</li> </ol> </li> </ol>

overemphasis on the training needs to exclude CHD, rather than directing the training toward meeting the specific competencies needed for each neonatal hemodynamic indication.

The Australasian Society for Ultrasound in Medicine guidelines for clinician-performed cardiac ultrasound mandate training at an approved neonatal center only. The duration of basic training is shorter and involves completion of a logbook of 50 echocardiograms, which includes a requirement to “competently record a series of images to clearly demonstrate normal cardiac anatomy.” There is an option for more advanced training including recognition of different forms of CHD by echocardiography.<sup>138</sup>

**North American Guidelines and Accreditation: Neonatal Hemodynamics and TNE.** In 2022, the Royal College of Physicians and Surgeons of Canada established neonatal hemodynamics and TNE (NHTNE) as an area of focused competence diploma, representing the first recognition of formal training of the subspecialty by a national accrediting body. The prescribed training pathway included guidelines specifying a comprehensive set of competency training requirements (comprising knowledge elements and training experiences), elements of a portfolio for documentation of experiences

and skill acquisition, and standards of accreditation for training programs in NHTNE. The duration of training is 1 year, and successful completion is dependent upon acquisition of a comprehensive set of competencies for clinical practice, without a prespecified minimum number of echocardiography studies performed.<sup>139</sup> Currently, there is no nationally approved accreditation mechanism in the United States. At some centers (e.g., the University of Iowa) the infrastructure, educational curriculum, and evaluative methods used for hemodynamic training has received local graduate medical education office accreditation. There are an insufficient number of programs presently to request Accreditation Council for Graduate Medical Education approval, but this should be a long-term goal.

**European Guidelines on NPE.** In 2015, a European special interest group was convened under the auspices of the European Society for Paediatric Research to produce a consensus statement on the training requirements for NPE in Europe, because of the aforementioned challenges in implementing the 2011 TNE guidelines.<sup>6</sup> The group defined the training facilities and infrastructure necessary for optimal training conditions in a European context and discussed some practical aspects including a suggested governance structure

**Table 10** Research opportunities and priorities for TNE and cPOCUS in neonates

Section and focus areas	Research opportunities and priorities
Rationale for TNE	<ul style="list-style-type: none"> <li>• Develop high-quality evidence for the use of TNE to provide enhanced mechanistic insights into common neonatal hemodynamic disease states and determine thresholds for intervention.</li> <li>• Develop prospective studies and clinical trials to characterize the impact of TNE-guided care (monitoring, treatment) on patient outcomes.</li> </ul>
Rationale for cPOCUS	<ul style="list-style-type: none"> <li>• Study the diagnostic reliability and safety of cPOCUS evaluations vs gold standard TNE or pediatric cardiology evaluations.</li> <li>• Develop high-quality evidence for use of cPOCUS-guided care on patient outcomes.</li> </ul>
Image optimization and measurement analyses	<ul style="list-style-type: none"> <li>• Develop standardized criteria for interpreting echocardiography data, including definitions of normal and abnormal findings.</li> <li>• Design longer, time-to-event clinical trials to validate potential LV- and RV-based surrogate end points that match the geometric shape, fiber orientation, and overall morphology with estimations of contractility, quantification of function, and overall performance.</li> <li>• Investigate imaging reliability and variance in measurements using commercial echocardiography equipment.</li> <li>• Improve the feasibility and reliability of deformation imaging, especially in preterm infants.</li> <li>• Explore the use of artificial intelligence to optimize and potentially automate echocardiography data analyses.</li> </ul>
Use of TNE to guide care	<ul style="list-style-type: none"> <li>• Develop consensus on “physiologically acceptable” states of premature infants according to maturation.</li> <li>• Generation of robust data sets to define normative values with Z scores applicable for neonates.</li> <li>• Development and validation of standardized imaging protocols for neonatal hemodynamic illnesses (e.g., PDA, PH [acute/chronic], RV/LV dysfunction, septic shock).</li> <li>• Investigate and define disease-specific thresholds associated with adverse outcomes, enabling intervention trials incorporating hemodynamic measures.</li> </ul>
Training and accreditation	<ul style="list-style-type: none"> <li>• Generate evidence for adjudication and maintenance of competency for TNE and cPOCUS.</li> <li>• Study barriers to establishment of a high-functioning neonatal hemodynamics program.</li> <li>• Investigate the impact of online platforms, simulation-based education.</li> </ul>

for oversight of training and continued quality assurance (and mandated a minimum of 200 echocardiograms spanning a 12- to 18-month period). Follow-up articles published in 2018 (<https://www.nature.com/collections/pjlqbgkmwk>) set the framework for a sustainable governance structure with the responsibility to provide accreditation to NPE in Europe.<sup>140</sup>

### Knowledge Elements and Competencies for Clinical Practice in TNE

Training programs in TNE should facilitate the acquisition of foundational knowledge (Table 6) and the development of competence in the major tasks of the discipline, which include (1) performance of neonatal echocardiography (Table 7), (2) consultation to the NICU (Table 8), and (3) management of the TNE service (Table 9).

### Proposed Training and Evaluation in TNE

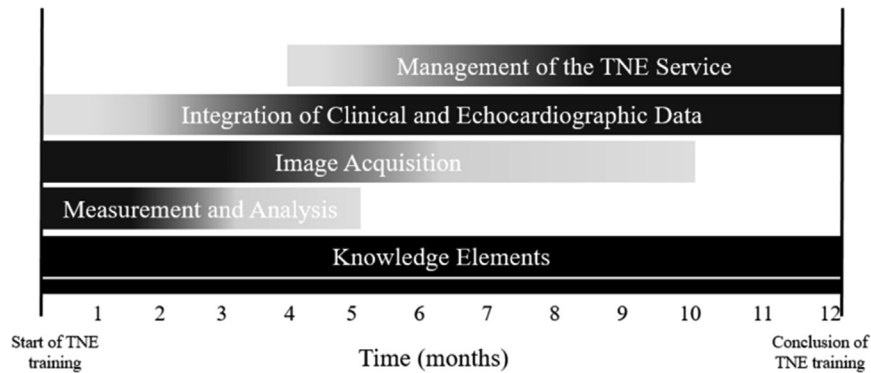
Contemporary medical education has shifted to a competency-based approach for trainee skill evaluation. In contrast to prior paradigms of training, time spent in a particular clinical experience is insufficient to determine successful acquisition of skills.<sup>141</sup> Similarly, individual learners may require different numbers of educational experiences to become proficient at a skill. Therefore, objective measures of proficiency are necessary to determine an individual clinician’s level of competence. Evaluation of a program is also important to determine

the effectiveness of the educational techniques used and to allow ongoing program improvement.<sup>142</sup>

The entry point for training in TNE is typically after successfully completing a fellowship in neonatal-perinatal medicine, which may be 3 years in the United States or 2 years in Canada. Performance of TNE involves multiple skill components, including image acquisition, image interpretation, measurement performance, and clinical application. For individuals developing skills in TNE, each of these components may be attained and assessed using different methods. Assessment should be both formative (during the learning process allowing for improvement) and summative (occurring at the conclusion of the learning process determining competence) with a clear milestone map for the trainee.<sup>141</sup> The recommended duration of training is 1 year, which is dedicated exclusively to learning the required competencies for TNE and neonatal hemodynamics.

Experience at centers with established TNE training programs has prompted the development of a timeline template for trainee acquisition of the knowledge and skills that culminate in clinical competency in the discipline. The specific timing, trajectory, and intensity of training in the development of competency in performing the major tasks occurs in an ordered fashion, with individual variability (Figure 27).

**Training and Evaluation in Image Acquisition and Analysis.** Training in image acquisition and interpretation should



**Figure 27** Depiction of the timing, trajectory, and intensity of training in the development of competency in performing the major tasks of the discipline of targeted neonatal echocardiography. The timing of greater intensity or focus of training is depicted by the shade of the horizontal bars. Darker areas of the bar correspond to the approximate time period of increased time and greater intensity of training committed to development and acquisition of the competency. Lighter areas of a bar correspond to the timing of an increasing or decreasing emphasis on the task. The length of each bar depicts the timing and duration typically allocated to competency acquisition. For example, early training is dedicated predominantly to developing the skills for echocardiography analysis and image acquisition, with increasing emphasis on integration of clinical and echocardiography data in the latter two thirds of the training period.

include a curriculum comprising competencies for which progress is evaluated and tracked through regular assessments and defined milestones (Supplemental Table 1). A registered pediatric cardiac sonographer, pediatric cardiologist, or TNE neonatologist should be designated as the educator in charge of the implementation and monitoring of progress throughout the training course.<sup>143</sup>

**Image Analysis and Measurement.** A didactic component of the program that provides instruction in image interpretation could be achieved using previously recorded images available locally or in public or private repositories (e.g., a database of teaching cases).<sup>144</sup> Image interpretation can be assessed on the basis of the content of those images which should include a variety of clinical conditions typically encountered during the practice of TNE. Exposure to cases of CHD, which may be seen less frequently, is essential to ensure the learner is able to identify deviations from normal anatomy and appropriately refer to a pediatric cardiologist. Skills in measurement performance could also be assessed using an examination based on stored images. These examinations may be created in a virtual self-administered environment or with an instructor present as an objective structured clinical examination.<sup>145,146</sup>

**Image Acquisition.** Preliminary skills in image acquisition may be developed and/or evaluated using a simulator, if available.<sup>147,148</sup> Neonatal echocardiography simulators can be used to develop basic echocardiography and imaging skills, especially in hand-eye coordination, in the early phase of learning. However, live image acquisition with patients is one of the most critical components necessary to develop proficiency in TNE. When possible, most (>75%) of the hands-on training should be completed on neonates to allow targeted and efficient training. This will allow the trainee in TNE to become familiar with normal cardiac anatomy and recognize abnormal patterns suggesting the presence of structural heart disease. To appropriately develop competence, image acquisition should be practiced under the supervision of an expert (Supplemental Table 2).<sup>149</sup> This permits real-time feedback and adjustment that will facilitate development of these skills. Newer automated technologies may be able to provide some of the same feedback necessary for effective learning.<sup>150</sup>

The evaluation of competence in image acquisition ultimately requires direct assessment of image acquisition and review of images obtained by the learner. Each trainee should achieve competency in each parameter or milestone before moving on to the next major phase of training.<sup>151</sup> Formal assessments of image acquisition and interpretation should be performed at defined intervals throughout the course of training.

Trainees should develop competence in performing standard TNE that will allow the identification of deviations from normal cardiac anatomy, prompting pediatric cardiology review.<sup>73</sup> At the end of training, the trainee should be able to independently obtain all standard imaging views, identify structural heart disease and interpret neonatal TNE for the defined indications.

**Individualization of Training.** Curriculums individualized to the institution should be developed for the trainee group and then further customized for each individual trainee to ensure competency in obtaining the desired outcome.<sup>152</sup> A milestone map (Supplemental Table 1) should be shared with the trainee at the initiation of training and reassessed at regular intervals. Support and evaluative methods for trainees should be developed and shared with the trainee and preceptor (Table 6). Customized interventions should be developed to help trainees who are not meeting their image acquisition or interpretive assessment goals.<sup>152</sup> A portfolio highlighting studies performed by the learner should be considered as a tool to demonstrate skills in acquiring images from a variety of patients.<sup>153</sup> Although there is no evidence to support a specific number of studies that would be necessary to determine that a learner is competent, the portfolio should include a broad range of clinical situations to document the types of experiences encountered.

**Duration of Training Focusing on Image Acquisition.** Trainees should expect that it will take a minimum of 2 months and up to 6 months to achieve the competencies in the image acquisition phase of the training.

### Training and Evaluation in Neonatal Hemodynamics

Evaluating a learner's ability to synthesize clinical, laboratory and imaging information and formulate therapeutic recommendations in

different clinical situations can be performed in several ways (Supplemental Table 3).<sup>154</sup> When a local TNE expert serves as the instructor, both the learner and instructor should review cases together in an apprenticeship style, an intensive format in which the instructor develops a good understanding of the learner's ability. Programs could also use case presentations and discussions to assess a learner's understanding of the clinical application of TNE findings as well as to reinforce physiologic principles. For a more objective measurement of skill, an objective structured clinical examination could be used to assess a learner's ability to apply the TNE data to clinical situations in a standardized format.

Traditionally, case logs or portfolios have been used to quantify a learner's clinical experiences. Although these are not sufficient to assess a learner's hands-on skill, they do document the breadth of cases a learner has experienced and therefore remain valuable. As an individual begins independent practice, case logs remain a valuable method of tracking experience and ongoing use of the skills previously acquired. They are also useful for leaders of programs to track the studies and case mix performed by all members of the program.

Training programs in TNE should develop a plan for objective learner assessment. The evaluation plan should include a combination of direct observation by an experienced clinician allowing formative feedback, and documented examination of knowledge, image acquisition, image interpretation, measurement, and application skills. Suggested methods of objectively assessing these components of TNE are detailed in Tables 8 and 9.

### Required Training Experiences.

- Performance of comprehensive transthoracic echocardiography in the NICU, including M-mode, two-dimensional, and Doppler echocardiography
- Performance and interpretation of targeted echocardiography in a level III or IV NICU
- Acting in the role of TNE consultant in the management of critically ill neonates
- Participation in the quality assurance activities of the TNE program
- Attendance and participation in local TNE rounds or conferences
- Participation in teaching and assessment of other trainees, sonographers, and physicians
- Scholarly activity related to TNE, which may include a research, education, or quality improvement project

The recommended minimum duration of training to achieve expertise in TNE is 12 months, or longitudinal equivalent. As highlighted earlier, it is recommended that training is commenced after successful completion of a fellowship in neonatal-perinatal medicine. This may include 2 to 4 months in a pediatric echocardiography laboratory (with access to a NICU) and the remainder within the NICU. Trainees should successfully complete (acquisition and interpretation) a minimum of 250 scans that span the entire range of indications (Section 3) to be deemed competent in the performance in TNE.

### Recommended Training Experiences.

- Performance and interpretation of tissue Doppler, two-dimensional strain echocardiography, and STE
- Review of an image library of neonatal echocardiography cases, including those with critical CHD
- Participation in educational activities by attendance at regional, national, or international conferences with significant discipline-related components
- Participation in the management and administration of the TNE service
- Participation in the review and/or revision of scanning protocols

- Creation of a proposal and business plan for development of a new TNE service
- Completion of a physics of ultrasonography course, or equivalent

**Exposure to CHD.** Guidelines for TNE training are directed toward the evaluation of patients with hemodynamic concern when there is low concern for CHD. Nevertheless, it is important for TNE practitioners to have the skills to recognize deviation from normal anatomy. Therefore, exposure to a variety of cases of CHD that are representative of right-sided, left-sided, and mixing lesions preferably cases in the newborn period. This exposure may be provided during dedicated rotations in the pediatric echocardiography laboratory (e.g., minimum 1-2 months) at a tertiary center (where feasible) or using hands-on simulators which have a range of cases of CHD.

### Practice Eligibility Route for Neonatologists With TNE Expertise

A practice eligibility route is a path to recognition of competence and certification in TNE and neonatal hemodynamics for physicians who are current TNE practitioners but who are ineligible for traditional credentials review from regulatory bodies as a result of completing unaccredited training or no formal training in the subspecialty. Certification through the practice eligibility route is most frequently undertaken by accrediting bodies.

Requirements for Practice Eligibility Route Certification in TNE.

- Practice duration: Minimum 4 years in independent clinical practice
- Practice profile
  - Setting: Tertiary or quaternary NICU
  - Medical professional activity: At least 30% of professional activity dedicated to clinical care, research, or teaching in NHTNE
  - Case mix: On an annual basis, the hemodynamics consultations performed (and TNE performed or reviewed) reflects the breadth and severity of disease states and pathophysiology of cardiorespiratory disease as outlined in the competency training requirements (Table 6)
- Evidence of competence: Multisource feedback including
  - Candidate
    - Case descriptions demonstrating appropriate performance of a hemodynamics consultation (with TNE) in the NICU
    - Demonstration of leadership in the field of neonatal hemodynamics and how these accomplishments have advanced the field
    - Scholarly activities in the field of NHTNE
    - Activities to further the education of peers, trainees, or learners in the field of NHTNE
  - Referees, including department head, other NHTNE neonatologists both within and external to candidate's institution, and non-TNE neonatologists familiar with the candidate's work in the field

### Requirements for Training Programs in TNE and Neonatal Hemodynamics

**Program Organization.** Programs providing training in TNE should have appropriate organizational structure, with leadership and administrative personnel to support the program, program director, affiliated teachers, and trainees effectively. Program organization and oversight may be facilitated by a program committee of key stakeholders, which may include representatives from pediatric cardiology and/or neonatal critical care as appropriate for the setting. Finally, programs should have a system of continuous improvement of the educational experiences of the trainees.

**Education Program: Teaching, Evaluation, and Remediation.** The training program should be designed, to facilitate trainees' development of the required competencies of the discipline. Programs should have developed and implemented a curriculum plan that is designed, on the basis of the ASE guidelines for TNE, and includes regularly scheduled formal teaching. Programs should also have an effective, organized system of trainee assessment that includes a logbook for tracking of the clinical encounters, case mix, learning reflections and acquisition of knowledge elements. Programs should have a system of assessment that includes regular, standardized review of trainee progress and portfolio, mechanisms for trainee engagement in performance review and support for trainees whose trajectory in attaining competencies falls below expectations.

Training programs should perform evaluations of the effectiveness of the educational experience through multiple different levels of assessment.<sup>142</sup> Learner surveys can determine the level of satisfaction with the program and seek feedback on ways to improve the program. The program should also track efficiency of training techniques by noting how many trainees complete the program and are considered competent at the conclusion. The program can also consider tracking how graduates use the skills in the future as a measure of effectiveness of the program. Finally, the ultimate measure of effectiveness of the program would be to determine the impact of this training on patient care, though methodology to estimate this effect is lacking.

**Resources.** Training programs in TNE should have the clinical, physical, technical, and financial resources to provide trainees with the educational experiences needed to acquire all competencies. The patient population should comprise preterm, extremely preterm, and term neonates requiring neonatal intensive care. Training should occur at sites with clinical consultative services in NHTNE. Access to a pediatric echocardiography suite and a pediatric cardiology consultation service is an asset, though may not be possible in all settings. The program should have access to equipment capable of comprehensive neonatal echocardiography, systems for securely archiving and reporting echocardiograms, and dedicated space and equipment for reviewing and reporting echocardiograms. Finally, the program should have resources to facilitate training experiences across the breadth and depth of cases, including simulation-based educational experiences in neonatal echocardiography, a teaching file of cases, or both.

**Instructors.** In the program, instructors should appropriately implement the curriculum, supervise, and assess trainees, contribute to the program, and model effective practices. The lead instructor (neonatologist or pediatric cardiologist or codirectorship) in the program must have demonstrated expertise in the discipline, including  $\geq 3$  years of practice and/or completion of a formal period of TNE training. All other neonatology instructors should have completed formal TNE training and collaborating sonographers and/or pediatric sonographers should be familiar with the unique training requirements of the neonatology TNE curriculum and the components of the standardized TNE evaluation.

### **cPOCUS: Training Recommendations**

Training in cPOCUS involves the acquisition of competence in a subset of the competencies required for clinical practice in TNE, often as a component of training alongside skill development for noncardiac indications for ultrasound imaging in the neonate (e.g., cerebral hemorrhage, vascular access). Like TNE, training in cPOCUS requires comparable program infrastructure, including quality sonographic

equipment, image archiving capability, administration, teaching, quality assurance, and methods for both formative and summative trainee evaluation (see Section 4).

The intensity and duration of training in cPOCUS should be commensurate with the complexity of the anticipated future scope of clinical practice of the trainee. There is currently a lack of standardization of training regarding the clinical scope of practice for cPOCUS in the NICU. Until a formalized training curriculum is developed, competency goals should therefore be individualized and formalized at the outset of training.

Although conclusion of training in cPOCUS should be determined on the basis of demonstrated competence, the typically shorter duration of training (relative to TNE) and associated reduced case-mix exposure implies a potential organizational benefit of recommending a minimum number of training experiences. At present, a minimum number of scans to determine competency cannot be justified on the basis of the currently available evidence for training in neonatal cPOCUS. However, given the breadth of imaging findings one could encounter, a minimum of 75 performed scans (minimum of 25 for line and heart function evaluation) is recommended as a supplement to a competency-based portfolio, commensurate with recommendations for training in cPOCUS in adults.<sup>155</sup> It must be highlighted that the actual number is an expert guide and should not replace the "in the moment" adjudication of competence in performing the required task. There is an urgent need to study the reliability of cPOCUS evaluations; in particular, the evaluation of line tip position may be particularly challenging in some patients.

### **Quality Assurance for TNE and cPOCUS**

All neonatal echocardiographers that have completed the advanced training level in TNE should continue to perform/review a minimum of 100 echocardiographic studies per year to maintain their skills and competence level. There are few data to inform a number for maintenance of competency in cPOCUS, but a minimum of 50 studies per year is suggested. Maintenance of competence by regular participation in echocardiographic conferences or training courses is strongly recommended. A structured program for continued education should be developed. Crucial for both TNE and cPOCUS programs is that they are organized according to current professional standards regarding image acquisition, image storage, and reporting. In hospitals with pediatric echocardiography laboratories, this can best be achieved by integration of the TNE activity within the pediatric echocardiography laboratory. This includes standardization of imaging protocols, uniform reporting, and a single imaging archive within the same hospital. In hospitals in which direct access to pediatric echocardiography laboratories is not available, the service should be organized according to generally accepted standards for echocardiography laboratories. This includes meeting operational standards (training of personnel, equipment, protocols, standards for storage, and reporting) as well as participation in quality improvement processes. Likewise, cPOCUS activity may be integrated either within the TNE program and/or pediatric echocardiography. All echocardiography (TNE or cPOCUS) studies should be recorded, and the images stored in a manner allowing immediate availability for review and easy retrieval. The ultrasound systems must include the ability to provide immediate playback with limited video degradation, standardized reports, and long-term storage. Digital storage is mandatory. Reporting standards should comply with the recommendations of the Intersocietal Commission for the Accreditation of Echocardiography Laboratories.<sup>156</sup> In NICU programs with no direct access to pediatric

cardiology services, telemedicine links between the NICU and the central laboratory could be organized. It is possible to transmit complete digital echocardiograms rapidly over secure high bandwidth connections, including from high-volume level 3 NICUs.<sup>157</sup> If TNE and cPOCUS are being performed in a facility without the availability of a practitioner with at least advanced-level training in TNE as outlined in this document, telemedicine capabilities should be considered a requirement. Each program should have a director who provides oversight to the operations, quality assurance and education. In addition, there should be a structured program for review of clinical cases or archived studies, that occurs at least monthly. Wherever possible, the establishment of joint educational rounds where neonatologists who perform TNE or cPOCUS evaluations, pediatric cardiologists, and sonographers participate in review of challenging cases, archived imaging studies, or new technologies should be welcomed.

### Recommendation

Programs in which standard TNE or cPOCUS assessments are performed must include a plan for ongoing quality assurance with oversight performed by an appointed director. This should include regular review of archived cases and challenging clinical dilemmas.

### Program Establishment

Institutions should evaluate the need for cPOCUS and advanced neonatal hemodynamic assessments, ability to train learners, and processes for quality assurance before program development. Common to both cPOCUS and neonatal hemodynamics programs is the need for dedicated ultrasound equipment with the appropriate size and frequency range of the probes, dedicated system for image storage, standardized reporting mechanism, and experienced program director. In addition, programs should develop clinical practice guidelines that clearly delineate the indications for either cPOCUS or TNE, scope of practice and the interface between the neonatal hemodynamics and pediatric cardiology services. As cPOCUS is only used to guide decisions in a critical situation, these evaluations should be followed by a comprehensive evaluation (TNE or pediatric echocardiography) within an agreed time frame specific to the institution. All TNE assessments should be completed by trained personnel that have completed formal training in TNE. At some centers it may be recommended that the first echocardiogram be a comprehensive pediatric echocardiogram that is performed and reviewed by pediatric cardiology staff. At other centers, the first assessment may be TNE either because pediatric cardiology services are not available or there is institutional agreement that TNE evaluation may be performed in patients with low risk for structural heart disease. A process should be established to ensure these TNE studies are reviewed by a pediatric cardiology expert to appraise the anatomy and/or arrange secondary comprehensive pediatric echocardiography. Without governance, programs may develop in which universal access is prioritized over ensuring that practitioners have the necessary knowledge, expertise, and critical volume of procedural exposure to optimize patient care. This may contribute to diagnostic or therapeutic inaccuracy.

**Equipment Standards.** TNE programs require imaging equipment which is designed for neonatal echocardiography and is dedicated for exclusive NICU use. In addition, programs should have access to a centralized storage system, which enables local or remote

viewing by both neonatologists with TNE expertise and pediatric cardiologists. Patients in whom TNE is performed may range in weight from 300 g to >5 kg, which requires the use of both phased-array and linear probes across a wide range of imaging frequencies (5-12 MHz).

### Recommendations

Programs in which standard TNE or cPOCUS assessments are performed must have access to dedicated echocardiography machines, probes with a range suitable for neonatal studies, and a centralized storage system that allows study retrieval and remote viewing.

**Billing Considerations.** Currently, there is no billing code which incorporates the diagnostic, interpretative and consultation elements of the integrated TNE evaluation which is very work-intensive. Guidelines related to the scope of billing should be established based on local institutional standards.

**Relationship Between Neonatal Hemodynamics Programs and Pediatric Cardiology.** Successful implementation of a hemodynamics program requires close collaboration between neonatologists with TNE expertise and pediatric cardiologists. There are likely to be differences in program setup among centers, according to program size, access to pediatric cardiology services, and the number of neonatologists with TNE training. First, all institutional policies for TNE evaluation, including indications, should be mutually agreeable and based on ASE (or equivalent) guidelines. These policies should stipulate those scenarios where pediatric cardiology consultation is advised (e.g., unexpected identification of CHD or persistent LV dysfunction) and the required processes. The approach to interventional PDA closure is an example of the importance of strong collaborative ties between the neonatologist with hemodynamics expertise and the pediatric cardiology team, before, during and after intervention. Second, regular joint neonatal hemodynamics-pediatric cardiology conferences to discuss clinical cases, ongoing research, or scientific controversies are advisable. Third, a process for joint morbidity and mortality discussion should be established. Fourth, a rotation in neonatal hemodynamics for pediatric cardiology trainees is advisable and, wherever possible, should be mandated to optimize exposure to neonatal hemodynamic problems. Fifth, research collaboration should be encouraged. Of note, much of the scientific advancement in the field of neonatal hemodynamics since the inaugural guidelines for TNE has resulted from close collaboration between neonatologists and pediatric cardiology imaging experts (e.g., Toronto, Iowa). Finally, regular administrative meetings between the director of the neonatal hemodynamics-TNE program and leaders in pediatric cardiology is essential to discuss patient volumes, equipment related matters, issues of quality, finances, and ongoing program challenges.

### CONCLUSION

Delineation of a clear boundary between the unique fields of neonatal hemodynamics (primary expertise in physiology-based echocardiography) and pediatric cardiology (primary expertise in

structural and functional echocardiography) has been clarified through published guidelines<sup>6,8</sup> and supported through peer reviewed publication. This document provides clarification on the scope of cPOCUS vs TNE to ensure that practitioners use these skills in accordance with approved indications. The field of neonatal hemodynamics, and the role of the neonatologist in performing echocardiography evaluations to delineate physiology, refine treatment, and monitor response to intervention has flourished at centers at which there is close collaboration between neonatologists with hemodynamic expertise and pediatric echocardiography laboratories. Training programs should be structured to ensure trainees are exposed to the broad range of patient sizes (<500 g to >5 kg) and hemodynamic scenarios in medical and surgical patients. Evaluation should focus on the achievement of imaging and cognitive competencies, rather than an arbitrary number of assessments. The usual duration of training to reach competence in TNE should be at least 1 year. Likewise, it is recommended that cPOCUS practitioners collaborate with local pediatric cardiology and/or neonatal hemodynamic programs to support the establishment of training guidelines and standards for practice to further enhance the care of neonates. Standardized process for image acquisition, interpretation and reporting, and storage are essential for quality assurance in both TNE and cPOCUS practice. Successful establishment of TNE-hemodynamics and/or cPOCUS programs requires institutional financial support to ensure the programs are appropriately resourced from both and equipment and personnel perspective. Although progress has been made in studying neonatal hemodynamic disease states and the impact of TNE-guided care there remain many gaps in scientific knowledge (Table 10). The establishment of research collaboratives to address research priorities and knowledge gaps is essential toward cultivating evolution of the field.

#### NOTICE AND DISCLAIMER

This report is made available by ASE as a courtesy reference source for members. This report contains recommendations only and should not be used as the sole basis to make medical practice decisions or for disciplinary action against any employee. The statements and recommendations contained in this report are primarily based on the opinions of experts, rather than on scientifically-verified data. ASE makes no express or implied warranties regarding the completeness or accuracy of the information in this report, including the warranty of merchantability or fitness for a particular purpose. In no event shall ASE be liable to you, your patients, or any other third parties for any decision made or action taken by you or such other parties in reliance on this information. Nor does your use of this information constitute the offering of medical advice by ASE or create any physician-patient relationship between ASE and your patients or anyone else.

#### CONFLICTS OF INTEREST

The following authors reported no actual or potential conflicts of interest in relation to this document: Patrick J. McNamara, MD, MSc, Amish Jain, MD, PhD, Afif El-Khuffash, MB BCh, Regan Giesinger, MD, Dany Weisz, MD, MSc, Lindsey Freud, MD, Philip T. Levy, MD, Shazia Bhombal, MD, Willem de Boode, MB BS, Tina Leone, MD, Bernadette Richards, RDCS, Yogen Singh, MB BCh, Jennifer M. Acevedo, ACS, Shahab Noori, MD, and Wyman W. Lai, MD.

The following authors reported relationships with one or more commercial interests: John Simpson, MB BCh, participated as a consultant for Canon Medical Systems and Philips Medical Systems.

#### ACKNOWLEDGMENTS

This document was reviewed by members of the 2023-2024 ASE Guidelines and Standards Committee, ASE Board of Directors, ASE Executive Committee, and designated reviewers (Piers Barker, MD, Kelly Boegle, ACS, RCCS, Lanqi Hua, ACS, RDCS, Jeff Jewell, RDCS, Majd Makhoul, MD, David Orsinelli, MD, Anitha Parthiban, MD, Alan Pearlman, MD, Andrew Pellet, PhD, RDCS, Gary Satou, MD, Kenan Stern, MD, and David H. Wiener, MD).

**The guidelines are dedicated to Dr Regan Giesinger, who devoted her life to the field of neonatal hemodynamics but who sadly passed away before their publication.**

#### REFERENCES

1. Nguyen J, Amimov R, Ramanathan R, et al. The state of point-of-care ultrasonography use and training in neonatal-perinatal medicine and pediatric critical care medicine fellowship programs. *J Perinatol* 2016;36:972-6.
2. Giesinger RE, Stanford AH, Rios DR, et al. Targeted neonatal echocardiography in the United States of America: the contemporary perspective and challenges to implementation. *Pediatr Res* 2019;85:919-21.
3. Corsini I, Ficial B, Fiocchi S, et al. Neonatologist performed echocardiography (NPE) in Italian neonatal intensive care units: a national survey. *Ital J Pediatr* 2019;45:131.
4. Kluckow M, Seri I, Evans N. Functional echocardiography: an emerging clinical tool for the neonatologist. *J Pediatr* 2007;150:125-30.
5. Singh Y, Gupta S, Groves AM, et al. Expert consensus statement 'Neonatologist-performed echocardiography (NoPE)'-training and accreditation in UK. *Eur J Pediatr* 2016;175:281-7.
6. de Boode WP, Singh Y, Gupta S, et al. Recommendations for neonatologist performed echocardiography in Europe: consensus statement endorsed by European Society for Paediatric Research (ESPR) and European Society for Neonatology (ESN). *Pediatr Res* 2016;80:465-71.
7. Kluckow M. Use of ultrasound in the haemodynamic assessment of the sick neonate. *Arch Dis Child Fetal Neonatal Ed* 2014;99:F332-7.
8. Mertens L, Seri I, Marek J, et al. Targeted neonatal echocardiography in the neonatal intensive care unit: practice guidelines and recommendations for training. Writing group of the American Society of Echocardiography (ASE) in collaboration with the European Association of Echocardiography (EAE) and the Association for European Pediatric Cardiologists (AEPC). *J Am Soc Echocardiogr* 2011;24:1057-78.
9. El-Khuffash A, Herbozo C, Jain A, et al. Targeted neonatal echocardiography (TnECHO) service in a Canadian neonatal intensive care unit: a 4-year experience. *J Perinatol* 2013;33:687-90.
10. Papadhima I, Louis D, Purna J, et al. Targeted neonatal echocardiography (TNE) consult service in a large tertiary perinatal center in Canada. *J Perinatol* 2018;38:1039-45.
11. Weidenbach M, Paech C. Simulation in neonatal echocardiography. *Clin Perinatol* 2020;47:487-98.
12. Siassi B, Ebrahimi M, Noori S, et al. Virtual neonatal echocardiographic training system (VNETS): an echocardiographic simulator for training basic transthoracic echocardiography skills in neonates and infants. *IEEE J Transl Eng Health Med* 2018;6:4700113.
13. Singh Y, Tissot C, Fraga MV, et al. International evidence-based guidelines on point of care ultrasound (POCUS) for critically ill neonates and children issued by the POCUS working group of the European

- Society of Paediatric and Neonatal Intensive Care (ESPNIC). *Crit Care* 2020;24:65.
14. Shefrin AE, Warkentine F, Constantine E, et al. Consensus core point-of-care ultrasound applications for pediatric emergency medicine training. *AEM Educ Train* 2019;3:251-8.
  15. Lu JC, Riley A, Conlon T, et al. Recommendations for cardiac point-of-care ultrasound in children: a report from the American Society of Echocardiography. *J Am Soc Echocardiogr* 2023;36:265-77.
  16. de Boode WP. Clinical monitoring of systemic hemodynamics in critically ill newborns. *Early Human Development* 2010;86:137-41.
  17. Tibby SM, Hatherill M, Marsh MJ, et al. Clinicians' abilities to estimate cardiac index in ventilated children and infants. *Arch Dis Child* 1997;77:516-8.
  18. Egan JR, Festa M, Cole AD, et al. Clinical assessment of cardiac performance in infants and children following cardiac surgery. *Intensive Care Med* 2005;31:568-73.
  19. Chew MS, Poelaert J. Accuracy and repeatability of pediatric cardiac output measurement using Doppler: 20-year review of the literature. *Intensive Care Med* 2003;29:1889-94.
  20. Ficial B, Finnemore AE, Cox DJ, et al. Validation study of the accuracy of echocardiographic measurements of systemic blood flow volume in newborn infants. *J Am Soc Echocardiogr* 2013;26:1365-71.
  21. Corredera A, Rodriguez MJ, Arevalo P, et al. IFunctional echocardiography in neonatal intensive care: 1 year experience in a unit in Spain. *An Pediatr (Barc)* 2014;81:167-73.
  22. Negreiros Figueira SA, de Oliveira AC, Zamith MM, et al. Echocardiography performed by the neonatologist: the impact on the clinical management. *Pediatr Res* 2023;94:724-9.
  23. El-Khuffash A, James AT, Corcoran JD, et al. A patent ductus arteriosus severity score predicts chronic lung disease or death before discharge. *J Pediatr* 2015;167:1354-61.e2.
  24. van Laere D, van Overmeire B, Gupta S, et al. Application of NPE in the assessment of a patent ductus arteriosus. *Pediatr Res* 2018;84:46-56.
  25. Su BH, Watanabe T, Shimizu M, et al. Echocardiographic assessment of patent ductus arteriosus shunt flow pattern in premature infants. *Arch Dis Child Fetal Neonatal Ed* 1997;77:F36-40.
  26. Carmo KB, Evans N, Paradisis M. Duration of indomethacin treatment of the preterm patent ductus arteriosus as directed by echocardiography. *J Pediatr* 2009;155:819-22.e1.
  27. Bravo MC, Cabanas F, Riera J, et al. Randomised controlled clinical trial of standard versus echocardiographically guided ibuprofen treatment for patent ductus arteriosus in preterm infants: a pilot study. *J Matern Fetal Neonatal Med* 2014;27:904-9.
  28. Jain A, Sahni M, El-Khuffash A, et al. Use of targeted neonatal echocardiography to prevent postoperative cardiorespiratory instability after patent ductus arteriosus ligation. *J Pediatr* 2012;160:584-9.e1.
  29. Ting JY, Resende M, More K, et al. Predictors of respiratory instability in neonates undergoing patent ductus arteriosus ligation after the introduction of targeted milrinone treatment. *J Thorac Cardiovasc Surg* 2016;152:498-504.
  30. Smith A, Breatnach CR, James AT, et al. Incidental findings on routine targeted neonatal echocardiography performed in preterm neonates younger than 29 Weeks' gestation. *J Ultrasound Med* 2018;37:843-9.
  31. Elsayed YN, Amer R, Seshia MM. The impact of integrated evaluation of hemodynamics using targeted neonatal echocardiography with indices of tissue oxygenation: a new approach. *J Perinatol* 2017;37:527-35.
  32. Elsayed YN, Louis D, Ali YH, et al. Integrated evaluation of hemodynamics: a novel approach for the assessment and management of preterm infants with compromised systemic circulation. *J Perinatol* 2018;38:1337-43.
  33. de Boode WP, Singh Y, Molnar Z, et al. Application of Neonatologist Performed Echocardiography in the assessment and management of persistent pulmonary hypertension of the newborn. *Pediatr Res* 2018;84:68-77.
  34. Aggarwal S, Natarajan G. Echocardiographic correlates of persistent pulmonary hypertension of the newborn. *Early Hum Dev* 2015;91:285-9.
  35. Malowitz JR, Forsha DE, Smith PB, et al. Right ventricular echocardiographic indices predict poor outcomes in infants with persistent pulmonary hypertension of the newborn. *Eur Heart J Cardiovasc Imaging* 2015;16:1224-31.
  36. Aggarwal S, Shanti C, Agarwal P, et al. Echocardiographic measures of ventricular-vascular interactions in congenital diaphragmatic hernia. *Early Hum Dev* 2022;165:105534.
  37. Patel N, Lally PA, Kipfmüller F, et al. Ventricular dysfunction is a critical determinant of mortality in congenital diaphragmatic hernia. *Am J Respir Crit Care Med* 2019;200:1522-30.
  38. Sehgal A, Ibrahim M, Tan K. Cardiac function and its evolution with pulmonary vasodilator therapy: a myocardial deformation study. *Echocardiography* 2014;31:E185-8.
  39. Shah DM, Kluckow M. Early functional echocardiogram and inhaled nitric oxide: usefulness in managing neonates born following extreme preterm premature rupture of membranes (PPROM). *J Paediatr Child Health* 2011;47:340-5.
  40. Lawrence KM, Monos S, Adams S, et al. Inhaled nitric oxide is associated with improved oxygenation in a Subpopulation of infants with congenital diaphragmatic hernia and pulmonary hypertension. *J Pediatr* 2020;219:167-72.
  41. Groves AM, Singh Y, Dempsey E, et al. Introduction to neonatologist-performed echocardiography. *Pediatr Res* 2018;84(Suppl 1):1-12.
  42. Giesinger RE, McNamara PJ. Hemodynamic instability in the critically ill neonate\_ an approach to cardiovascular support based on disease pathophysiology. Elsevier. *Semin Perinatol* 2016;40:174-88.
  43. Rios DR, Bhattacharya S, Levy PT, et al. Circulatory insufficiency and hypotension related to the ductus arteriosus in neonates. *Front Pediatr* 2018;6:F474.
  44. Lakshminrusimha S, Steinhorn RH. Pulmonary vascular biology during neonatal transition. *Clin Perinatol* 1999;26:601-19.
  45. Rudolph AM. The ductus arteriosus and persistent patency of the ductus arteriosus. In: Chichester, UK: Wiley-Blackwell; 2009. pp. 115-47.
  46. Bussmann NBC, Levy PT, McCallion N, et al. Early diastolic dysfunction and respiratory morbidity in premature infants: an observational study. *J Perinatol* 2018;38:1205-11.
  47. Jain A, McNamara PJ. Persistent pulmonary hypertension of the newborn: advances in diagnosis and treatment. Elsevier Ltd. *Semin Fetal Neonatal Med* 2015;20:262-71.
  48. Miller LE, Stoller JZ, Fraga MV. Point-of-care ultrasound in the neonatal ICU. *Curr Opin Pediatr* 2020;32:216-27.
  49. Arntfield RT, Millington SJ. Point of care cardiac ultrasound applications in the emergency department and intensive care unit—a review. *Curr Cardiol Rev* 2012;8:98-108.
  50. Lau YH, See KC. Point-of-care ultrasound for critically-ill patients: a mini-review of key diagnostic features and protocols. *World J Crit Care Med* 2022;11:70-84.
  51. Synnes AR, Berry M, Jones H, et al. Infants with congenital anomalies admitted to neonatal intensive care Units. *Am J Perinatol* 2004;21:199-207.
  52. Altit G, Bhombal S, Van Meurs K, et al. Ventricular performance is associated with need for extracorporeal membrane oxygenation in newborns with congenital diaphragmatic hernia. *J Pediatr* 2017;191:28-34.e1.
  53. Patel N, Mills JF, Cheung MMH, et al. Systemic haemodynamics in infants with vein of Galen malformation: assessment and basis for therapy. *J Perinatol* 2007;27:460-3.
  54. Giesinger RE, Elsayed YN, Castaldo MP, et al. Targeted neonatal echocardiography-guided therapy in vein of galen aneurysmal malformation: a report of two cases with a review of physiology and approach to management. *Am J Perinatol Rep* 2019;9:e172-6.
  55. Smith A, Purna JR, Castaldo MP, et al. Accuracy and reliability of qualitative echocardiography assessment of right ventricular size and function in neonates. *Echocardiography* 2019;36:1346-52.
  56. Broadhouse KM, Price AN, Durighel G, et al. Assessment of PDA shunt and systemic blood flow in newborns using cardiac MRI. *NMR Biomed* 2013;26:1135-41.

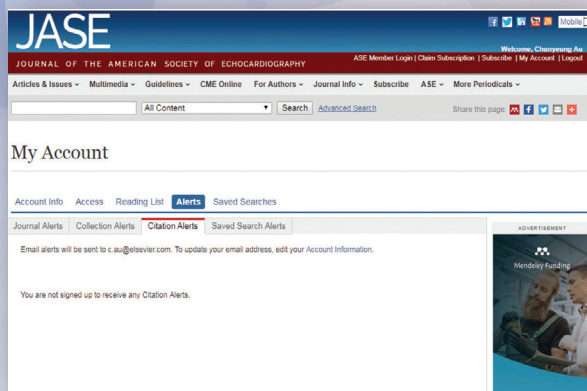


57. Jain A, Mohamed A, El-Khuffash A, et al. A comprehensive echocardiographic protocol for assessing neonatal right ventricular dimensions and function in the transitional period: normative data and z scores. *J Am Soc Echocardiogr* 2014;27:1293-304.
58. Kaul S, Tei C, Hopkins JM, et al. Assessment of right ventricular function using two-dimensional echocardiography. *Am Heart J* 1984;107:526-31.
59. Koestenberger M, Nagel B, Ravekes W, et al. Systolic right ventricular function in preterm and term neonates: reference values of the tricuspid annular plane systolic excursion (TAPSE) in 258 patients and calculation of Z-score values. *Neonatology* 2011;100:85-92.
60. Giesinger RE, El Shahed AI, Castaldo MP, et al. Impaired right ventricular performance is associated with adverse outcome following hypoxic ischemic encephalopathy. *Am J Respir Crit Care Med* 2019;200:1294-305.
61. Ryan T, Petrovic O, Dillon JC, et al. An echocardiographic index for separation of right ventricular volume and pressure overload. *J Am Coll Cardiol* 1985;5:918-27.
62. Patel MD, Breatnach CR, James AT, et al. Echocardiographic assessment of right ventricular afterload in preterm infants: maturational patterns of pulmonary artery acceleration time over the first year of age and implications for pulmonary hypertension. *J Am Soc Echocardiogr* 2019;32:884-94.e4.
63. Musewe NN, Poppe D, Smallhorn JF, et al. Doppler echocardiographic measurement of pulmonary artery pressure from ductal Doppler velocities in the newborn. *J Am Coll Cardiol* 1990;15:446-56.
64. Kupferschmid C, Lang D. The valve of the foramen ovale in interatrial right-to-left shunt: echocardiographic cineangiographic and hemodynamic observations. *Am J Cardiol* 1983;51:1489-94.
65. Kadappu KK, Thomas L. Tissue Doppler imaging in echocardiography: value and limitations. *Heart Lung Circ* 2015;24:224-33.
66. Arques S, Roux E, Luccioni R. Current clinical applications of spectral tissue Doppler echocardiography (E/E' ratio) as a noninvasive surrogate for left ventricular diastolic pressures in the diagnosis of heart failure with preserved left ventricular systolic function. *Cardiovasc Ultrasound* 2007;5:16.
67. El-Khuffash A, Schubert U, Levy PT, et al. Deformation imaging and rotational mechanics in neonates: a guide to image acquisition, measurement, interpretation, and reference values. *Pediatr Res* 2018;84:30-45.
68. Breatnach CR, Forman E, Foran A, et al. Left ventricular rotational mechanics in infants with hypoxic ischemic encephalopathy and preterm infants at 36 weeks postmenstrual age: a comparison with healthy term controls. *Echocardiography* 2017;34:232-9.
69. Cappelleri A, Bussmann N, Harvey S, et al. Myocardial function in late preterm infants during the transitional period: comprehensive appraisal with deformation mechanics and non-invasive cardiac output monitoring. *Cardiol Young* 2020;30:249-55.
70. Smith A, Bussmann N, Levy P, et al. Comparison of left ventricular rotational mechanics between term and extremely premature infants over the first week of age. *Open Heart* 2021;8:e001458.
71. Lima MSM, Villarraga HR, Abduch MCD, et al. Global longitudinal strain or left ventricular twist and torsion? Which correlates best with ejection fraction? *Arq Bras Cardiol* 2017;109:23-9.
72. Badano LP, Koliakos TJ, Muraru D, et al. Standardization of left atrial, right ventricular, and right atrial deformation imaging using two-dimensional speckle tracking echocardiography: a consensus document of the EACVI/ASE/Industry Task Force to standardize deformation imaging. *Eur Heart J Cardiovasc Imaging* 2018;19:591-600.
73. Lai WW, Geva T, Shirali GS, et al. Guidelines and standards for performance of a pediatric echocardiogram: a report from the task force of the pediatric Council of the American Society of echocardiography. *J Am Soc Echocardiogr* 2006;19:1413-30.
74. Wasserman MA, Shea E, Cassidy C, et al. Recommendations for the adult cardiac sonographer performing echocardiography to screen for critical congenital heart disease in the newborn: from the American Society of echocardiography. *J Am Soc Echocardiogr* 2021;34:207-22.
75. Bischoff AR, Giesinger RE, Rios DR, et al. Anatomic concordance of neonatologist-performed echocardiography as part of hemodynamics consultation and pediatric cardiology. *J Am Soc Echocardiogr* 2021;34:301-7.
76. Stewart DL, Elsayed Y, Fraga MV, et al. Use of point-of-care ultrasonography in the NICU for diagnostic and procedural purposes. *Pediatrics* 2022;150. e2022060053.
77. Elsayed Y, Wahab MGA, Mohamed A, et al. Point-of-care ultrasound (POCUS) protocol for systematic assessment of the crashing neonate-expert consensus statement of the international crashing neonate working group. *Eur J Pediatr* 2023;182:53-66.
78. Smith A, El-Khuffash AF. Defining "haemodynamic significance" of the patent ductus arteriosus: do we have all the answers? *Neonatology* 2020;117:225-32.
79. Arattu Thodika FMS, Nanjundappa M, Dassios T, et al. Pulmonary hypertension in infants with bronchopulmonary dysplasia: risk factors, mortality and duration of hospitalisation. *J Perinat Med* 2021;50:327-33.
80. Dasgupta S, Richardson JC, Aly AM, et al. Role of functional echocardiographic parameters in the diagnosis of bronchopulmonary dysplasia-associated pulmonary hypertension. *J Perinatol* 2021;42:19-30.
81. Berkelhamer SK, Mestan KK, Steinhorn R. An update on the diagnosis and management of bronchopulmonary dysplasia (BPD)-associated pulmonary hypertension. *Semin Perinatol* 2018;42:432-43.
82. Lawn JE, Cousens S, Zupan J. 4 million neonatal deaths: when? Where? Why? *Lancet* 2005;365:891-900.
83. Jacobs SE, Morley CJ, Inder TE, et al. Whole-body hypothermia for term and near-term newborns with hypoxic-ischemic encephalopathy: a randomized controlled trial. *Arch Pediatr Adolesc Med* 2011;165:692-700.
84. Ilves P, Lintrop M, Metsvaht T, et al. Cerebral blood-flow velocities in predicting outcome of asphyxiated newborn infants. *Acta Paediatr* 2004;93:523-8.
85. Hochwald O, Jabr M, Osiovič H, et al. Preferential cephalic redistribution of left ventricular cardiac output during therapeutic hypothermia for perinatal hypoxic-ischemic encephalopathy. *J Pediatr* 2014;164:999-1004.e1.
86. Rodriguez MJ, Corredera A, Martinez-Orgado J, et al. Cerebral blood flow velocity and oxygenation correlate predominantly with right ventricular function in cooled neonates with moderate-severe hypoxic-ischemic encephalopathy. *Eur J Pediatr* 2020;179:1609-18.
87. Giussani DA. The fetal brain sparing response to hypoxia: physiological mechanisms. *J Physiol* 2016;594:1215-30.
88. Smolich JJ. Ultrastructural and functional features of the developing mammalian heart: a brief overview. *Reprod Fertil Dev* 1995;7:451-61.
89. Pinson CW, Morton MJ, Thornburg KL. An anatomic basis for fetal right ventricular dominance and arterial pressure sensitivity. *J Dev Physiol* 1987;9:253-69.
90. Ryan JJ, Huston J, Kutty S, et al. Right ventricular adaptation and failure in pulmonary arterial hypertension. *Can J Cardiol* 2015;31:391-406.
91. Vasquez AM, Bischoff AR, McNamara PJ, et al. Impact of therapeutic hypothermia on echocardiography indices of pulmonary hemodynamics pediatric academic societies meeting. e-PAS 2022.
92. Shah S, Tracy M, Smyth J. Postnatal lactate as an early predictor of short-term outcome after intrapartum asphyxia. *J Perinatol* 2004;24:16-20.
93. Eriksen VR, Trautner S, Hahn GH, et al. Lactate acidosis and cardiac output during initial therapeutic cooling in asphyxiated newborn infants. *PLoS one* 2019;14:e0213537.
94. Guluma KZ, Liu L, Hemmen TM, et al. Therapeutic hypothermia is associated with a decrease in urine output in acute stroke patients. *Resuscitation* 2010;81:1642-7.
95. Levy P, Tissot C, Eriksen BH, et al. Application of Neonatologist Performed Echocardiography in the Assessment and Management of Neonatal Heart Failure unrelated to Congenital Heart Disease. *Nature Publishing Group: Springer US*; 2018. pp. 1-11.
96. Pauliks LB. The effect of pregestational diabetes on fetal heart function. *Expert Rev Cardiovasc Ther* 2014;13:67-74.

97. Kozák-Bárány A, Jokinen E, Kero P, et al. Impaired left ventricular diastolic function in newborn infants of mothers with pregestational or gestational diabetes with good glycemic control. *Early Hum Dev* 2004;77:13-22.
98. Miller HC. Cardiac hypertrophy and extra medullary hematopoiesis in newborn infants of prediabetic mothers. *Am J Med Sci* 1945;209.
99. Way GL, Wolfe RR, Eshaghpour E, et al. The natural history of hypertrophic cardiomyopathy in infants of diabetic mothers. *J Pediatr* 1979;95:1020-5.
100. Halliday HL. Hypertrophic cardiomyopathy in infants of poorly-controlled diabetic mothers. *Arch Dis Child* 1981;56:258-63.
101. Trowitzsch E, Bigalke U, Gisbertz R, et al. Echocardiographic profile of infants of diabetic mothers. *Eur J Pediatr* 1983;140:311-5.
102. Cade WT, Levy PT, Tinius RA, et al. Markers of maternal and infant metabolism are associated with ventricular dysfunction in infants of obese women with type 2 diabetes. *Pediatr Res* 2017;82:768-75.
103. Al-Biltagi M, Tolba OA, Rowisha MA, et al. Speckle tracking and myocardial tissue imaging in infant of diabetic mother with gestational and pregestational diabetes. *Pediatr Cardiol* 2014;36:445-53.
104. Liao WQ, Zhou HY, Chen GC, et al. Left ventricular function in newborn infants of mothers with gestational diabetes mellitus. *Zhongguo Dang Dai Er Ke Za Zhi* 2012;14:575-7.
105. Moon-Grady AJ. Fetal echocardiography in twin-twin transfusion syndrome. *Am J Perinatol* 2014;31(Suppl 1):S31-8.
106. Manning N, Archer N. Cardiac manifestations of twin-to-twin transfusion syndrome. *Twin Res Hum Genet* 2016;19:246-54.
107. Rychik J, Zeng S, Bebbington M, et al. Speckle tracking-derived myocardial tissue deformation imaging in twin-twin transfusion syndrome: differences in strain and strain rate between donor and recipient twins. *Fetal Diagn Ther* 2012;32:131-7.
108. Harkness UF, Crombleholme TM. Twin-twin transfusion syndrome: where do we go from here? *Semin Perinatol* 2005;29:296-304.
109. Roberts D, Gates S, Kilby M, et al. Interventions for twin-twin transfusion syndrome: a Cochrane review. *Ultrasound Obstet Gynecol* 2008;31:701-11.
110. Akkermans J, Peeters SHP, Klumper FJ, et al. Twenty-five years of fetoscopic laser Coagulation in twin-twin transfusion syndrome: a systematic review. *Fetal Diagn Ther* 2015;38:241-53.
111. Habli M, Lim FY, Crombleholme T. Twin-to-twin transfusion syndrome: a comprehensive update. *Clin Perinatol* 2009;36:391-416.
112. Breatnach CR, Bussmann N, Levy PT, et al. Postnatal myocardial function in monozygotic diamniotic twins with twin-to-twin transfusion syndrome following selective laser photocoagulation of the communicating placental vessels. *J Am Soc Echocardiogr* 2019;32:774-84.e1.
113. Bensouda B, Fouron JC, Raboisson MJ, et al. Relevance of measuring diastolic time intervals in the ductus venosus during the early stages of twin-twin transfusion syndrome. *Ultrasound Obstet Gynecol* 2007;30:983-7.
114. Raboisson MJ. Early intertwin differences in myocardial performance during the twin-to-twin transfusion syndrome. *Circulation* 2004;110:3043-8.
115. Breatnach CR, Levy PT, Franklin O, et al. Strain rate and its positive force-frequency relationship: further evidence from a premature infant cohort. *J Am Soc Echocardiogr* 2017;30:1045-6.
116. Mégarbané A, Ravel A, Mircher C, et al. The 50th anniversary of the discovery of trisomy 21: the past, present, and future of research and treatment of Down syndrome. *Genet Med* 2009;11:611-6.
117. Martin T, Smith A, Breatnach CR, et al. Infants born with Down syndrome: burden of disease in the early neonatal period. *J Pediatr* 2018;193:21-6.
118. Bush D, Galambos C, Ivy DD, et al. Clinical characteristics and risk factors for developing pulmonary hypertension in children with Down syndrome. *J Pediatr* 2018;202:212-9.e2.
119. Bull MJ, Committee on G. Health supervision for children with Down syndrome. *Pediatrics* 2011;128:393-406.
120. Cannon BC, Feltes TF, Fraley JK, et al. Nitric oxide in the evaluation of congenital heart disease with pulmonary hypertension: factors related to nitric oxide response. *Pediatr Cardiol* 2005;26:565-9.
121. Breatnach CR, Bussmann N, Smith A, et al. Cardiac mechanics in infants with Down syndrome in the early neonatal period. *J Perinatol* 2019;39:626-33.
122. Clur SA, Oude Rengerink K, Ottenkamp J, et al. Cardiac function in trisomy 21 fetuses. *Ultrasound Obstet Gynecol* 2011;37:163-71.
123. Mula R, Grande M, Bannasar M, et al. Further insights into diastolic dysfunction in first-trimester trisomy-21 fetuses. *Ultrasound Obstet Gynecol* 2015;45:205-10.
124. Al-Biltagi M, Serag AR, Hefidah MM, et al. Evaluation of cardiac functions with Doppler echocardiography in children with Down syndrome and anatomically normal heart. *Cardiol Young* 2013;23:174-80.
125. Balli S, Yuçel IK, Kibar AE, et al. Assessment of cardiac function in absence of congenital and acquired heart disease in patients with Down syndrome. *World J Pediatr* 2016;12:463-9.
126. Bull MJ, Trotter T, Santoro SL, et al. Health supervision for children and adolescents with Down syndrome. *Pediatrics* 2022;149.
127. Dempsey EM, Barrington KJ. Diagnostic criteria and therapeutic interventions for the hypotensive very low birth weight infant. *J Perinatol* 2006;26:677-81.
128. Pellicer A, Valverde E, Elorza MD, et al. Cardiovascular support for low birth weight infants and cerebral hemodynamics: a randomized, blinded, clinical trial. *Pediatrics* 2005;116:1501-12.
129. de waal K, Evans N. Hemodynamics presentation of late-onset sepsis in the preterm newborns. *J Paediatr Child Health* 2009;35:A84.
130. de Boode WP, van der Lee R, Eriksen BH, et al. The role of Neonatologist Performed Echocardiography in the assessment and management of neonatal shock. *Pediatr Res* 2018;84:57-67.
131. Lakshminrusimha S, Saugstad OD. The fetal circulation, pathophysiology of hypoxemic respiratory failure and pulmonary hypertension in neonates, and the role of oxygen therapy. *J Perinatol* 2016;36:S3-11.
132. Levy PT, Patel MD, Groh G, et al. Pulmonary artery acceleration time provides a reliable estimate of invasive pulmonary hemodynamics in children. *J Am Soc Echocardiogr* 2016;29:1056-65.
133. Jones KL, Adam MP. Evaluation and diagnosis of the dysmorphic infant. *Clin Perinatol* 2015;42:243-61.
134. Dal Col AK, Bhombal S, Tacy TA, et al. Comprehensive echocardiographic assessment of ventricular function and pulmonary pressure in the neonatal omphalocele population. *Am J Perinatol* 2020;38(S 01):e109-15.
135. Practice guidelines for central venous access 2020: an updated report by the American Society of Anesthesiologists task force on central venous access. *Anesthesiology* 2020;132:8-43.
136. Jain A, McNamara PJ, Ng E, et al. The use of targeted neonatal echocardiography to confirm placement of peripherally inserted central catheters in neonates. *Am J Perinatol* 2012;29:101-6.
137. Pawlowski TW, Stoller JZ, Rintoul NE, et al. Point-of-care ultrasound for the evaluation of venous cannula position in neonatal extracorporeal membrane oxygenation. *J Perinatol* 2021;41:1645-50.
138. Medicine ASU. Certificate in Clinician Performed Ultrasound - CCPU Neonatal Ultrasound Modality Proficiency and Appropriate Use Statement. NSW Australia: Crows Nest; 2009.
139. <https://www.royalcollege.ca/rcsite/ibd-search-e>. Accessed December 8, 2023.
140. Singh Y, Roeher CC, Tissot C, et al. Education, training, and accreditation of neonatologist performed echocardiography in Europe-framework for practice. *Pediatr Res* 2018;84:13-7.
141. Lockyer J, Carraccio C, Chan MK, et al. Core principles of assessment in competency-based medical education. *Med Teach* 2017;39:609-16.
142. Frye AW, Hemmer PA. Program evaluation models and related theories: AMEE guide no. 67. *Med Teach* 2012;34:e288-99.
143. Ferguson PC, Caverzagie KJ, Nousiainen MT, et al. Changing the culture of medical training: an important step toward the implementation of competency-based medical education. *Med Teach* 2017;39:599-602.
144. Brown KA, Riley AF, Alade KH, et al. A novel tool for teaching cardiac point-of-care ultrasound: an exploratory application of the design-based research approach. *Pediatr Crit Care Med* 2020;21:e1113-8.

145. Nielsen DG, Gotzsche O, Eika B. Objective structured assessment of technical competence in transthoracic echocardiography: a validity study in a standardised setting. *BMC Med Educ* 2013;13:47.
146. Mitchell JD, Amir R, Montealegre-Gallegos M, et al. Summative objective structured clinical examination assessment at the end of anesthesia residency for perioperative ultrasound. *Anesth Analg* 2018;126:2065-8.
147. Dayton JD, Groves AM, Glickstein JS, et al. Effectiveness of echocardiography simulation training for paediatric cardiology fellows in CHD. *Cardiol Young* 2018;28:611-5.
148. Noori S, Ebrahimi M, Uzunyan M, et al. Effectiveness of simulation training in acquiring echocardiography skills among neonatology care providers. *Am J Perinatol* 2022. <https://doi.org/10.1016/j.echo.2023.11.016>. Online ahead of print.
149. Cecilio-Fernandes D, Cnossen F, Coster J, et al. The effects of expert and augmented feedback on learning a complex medical skill. *Percept Mot Skills* 2020;127:766-84.
150. Skinner AA, Freeman RV, Sheehan FH. Quantitative feedback facilitates acquisition of skills in focused cardiac ultrasound. *Simul Healthc* 2016;11:134-8.
151. Frank JR, Snell LS, Cate OT, et al. Competency-based medical education: theory to practice. *Med Teach* 2010;32:638-45.
152. Desy JR, Reed DA, Wolanskyj AP. Milestones and millennials: a perfect pairing-competency-based medical education and the learning preferences of generation Y. *Mayo Clin Proc* 2017;92:243-50.
153. Hughes DR, Kube E, Gable BD, et al. The sonographic digital portfolio: a longitudinal ultrasound image tracking program. *Crit Ultrasound J* 2012;4:15.
154. Hebert A, Lavoie PM, Giesinger RE, et al. Evolution of training guidelines for echocardiography performed by the neonatologist: toward hemodynamic consultation. *J Am Soc Echocardiogr* 2019;32:785-90.
155. Canada. RCoPaSo. Acute Care Point of Care Ultrasonography; 2023. [https://www.royalcollege.ca/rcsite/ibd-search-e?N=10000033+10000034+4294967076&label=Acute%20Care%20Point%20of%20Care%20Ultrasonography%20\(POCUS\)](https://www.royalcollege.ca/rcsite/ibd-search-e?N=10000033+10000034+4294967076&label=Acute%20Care%20Point%20of%20Care%20Ultrasonography%20(POCUS)). Accessed December 8, 2023.
156. Frommelt P, Gorentz J, Deatsman S, et al. Digital imaging, archiving, and structured reporting in pediatric echocardiography: impact on laboratory efficiency and physician communication. *J Am Soc Echocardiogr* 2008;21:935-40.
157. Huang T, Moon-Grady AJ, Traugott C, et al. The availability of telecardiology consultations and transfer patterns from a remote neonatal intensive care unit. *J Telemed Telecare* 2008;14:244-8.

# Did you know?



You can track the impact of your article with citation alerts that let you know when your article (or any article you'd like to track) has been cited by another Elsevier-published journal.

Visit [onlinejase.com](http://onlinejase.com) today!

**Supplemental Table 1** Example phased milestone map for NHTNE trainees

Phase 1	Phase 2	Phase 3	Phase 4
Basic principles of echocardiography including ergonomics	Advanced principles of echocardiography	Basic report writing	Advanced report writing
Echocardiographic physics	Basic CHD identification	Advanced CHD identification	
Operational processes	Basic measurement performance	Advanced measurement performance	Advanced image interpretation
Basic image acquisition	Intermediate image acquisition	Advanced image acquisition	

**Supplemental Table 2** Formative learning support for trainees in TNE

Support	Description
Milestone map development	Jointly developed with educator at the start of training
Preceptor training pods	Avoid rotating trainee through a large number of sonographic preceptors
Training huddles and goal recalibration	Periodic (weekly or monthly) team meetings to review and calibrate specific goals
Independent study assignments	Identify and assign text or e-learning activities related to current phase of training
Technical assessments	Direct observation of procedural skills (DOPS) assessment of image acquisition on a neonate (live) or through use of a simulator
Interpretive assessments	Observation of trainee interpretation of an echocardiogram; may be enhanced with inclusion of clinical information and the formulation of a diagnostic evaluation and therapeutic management plan

DOPS, Direct observation in practice study.

**Supplemental Table 3** Evaluation tools to assess learner competence in TNE

Skill	Assessment tool	Suggested use
Image interpretation	OSCE	Instructor provides standardized set of images with questions for learners to answer.
Image acquisition	Direct observation	Instructor provides immediate feedback at the time of image acquisition.
	Portfolio	Instructor ensures adequate technique on standard set of views acquired and provides postimaging feedback. Competence determined by need for minimal feedback.
Measurement performance	OSCE	Learner performs measurements on images previously acquired. Findings compared with instructor/standardized measurements.
Clinical application	OSCE	Learner reviews cases presented with clinical information and images available and answers questions about management decisions.
Skill maintenance	Case logs	Track breadth of experiences over time.
	Case conferences	Regular discussion of clinical application with other TNE-skilled clinicians.

OSCE, Objective structured clinical assessment.