

Canadian Association of Radiologists Gastrointestinal Imaging Referral Guideline

Canadian Association of
Radiologists Journal
1–11
© The Author(s) 2024



Article reuse guidelines:
sagepub.com/journals-permissions
DOI: 10.1177/08465371231217230
journals.sagepub.com/home/caj



Candycy Hamel¹ , **Barb Avard²**, **Catherine Belanger³**,
Avi Chatterjee⁴, **Angus Hartery⁵**, **Howard Lim⁶**,
Sivaruban Kanagaratnam⁷, and **Christopher Fung⁸**

Abstract

The Canadian Association of Radiologists (CAR) Gastrointestinal Expert Panel consists of radiologists, a gastroenterologist, a general surgeon, a family physician, a patient advisor, and an epidemiologist/guideline methodologist. After developing a list of 20 clinical/diagnostic scenarios, a systematic rapid scoping review was undertaken to identify systematically produced referral guidelines that provide recommendations for one or more of these clinical/diagnostic scenarios. Recommendations from 58 guidelines and contextualization criteria in the Grading of Recommendations, Assessment, Development, and Evaluations (GRADE) for guidelines framework were used to develop 85 recommendation statements specific to the adult population across the 20 scenarios. This guideline presents the methods of development and the referral recommendations for dysphagia/dyspepsia, acute nonlocalized abdominal pain, chronic abdominal pain, inflammatory bowel disease, acute gastrointestinal bleeding, chronic gastrointestinal bleeding/anemia, abnormal liver biopsy, pancreatitis, anorectal diseases, diarrhea, fecal incontinence, and foreign body ingestion.

Résumé

Le groupe d'experts en maladies gastro-intestinales de l'Association canadienne des radiologistes (CAR) regroupe des radiologistes, un gastroentérologue, un chirurgien généraliste, un médecin de famille, une représentante des patients et un épidémiologiste spécialisé en méthodologie de l'élaboration de lignes directrices. Après avoir élaboré une liste de 20 scénarios cliniques/diagnostiques, une revue systématique rapide de délimitation du problème a été entreprise pour repérer les lignes directrices de référence produites systématiquement qui fournissent des recommandations pour un ou plusieurs de ces scénarios. Les recommandations de 58 lignes directrices et les critères de contextualisation du cadre GRADE (notation des recommandations, analyses, développements et évaluations) pour la structure des lignes directrices ont été utilisés afin d'élaborer 85 énoncés de recommandations spécifiques pour la population adulte couvrant les 20 scénarios. Ces lignes directrices présentent les méthodes d'élaboration et les recommandations d'orientation pour la dysphagie/dyspepsie, les douleurs abdominales aiguës non localisées, les douleurs abdominales chroniques, les maladies inflammatoires de l'intestin, les saignements digestifs aigus, les saignements digestifs chroniques, l'anémie digestive chronique, la biopsie hépatique anormale, la pancréatite, les maladies anorectales, la diarrhée, l'incontinence fécale et l'ingestion de corps étrangers.

Keywords

gastrointestinal system, diagnostic imaging, referrals, guideline, adults

¹ Canadian Association of Radiologists, Ottawa, ON, Canada

² North York General Hospital, Toronto, ON, Canada

³ Ormstown Medical Clinic, Ormstown, QC, Canada

⁴ The Ottawa Hospital, University of Ottawa, Ottawa, ON, Canada

⁵ Eastern Health, Memorial University, St. Clare's, St. John's, NL, Canada

⁶ University of British Columbia, BC Cancer, Vancouver Centre, Vancouver, BC, Canada

⁷ Cypress Regional Hospital, University of Saskatchewan, Swift Current, SK, Canada

⁸ University of Alberta, Edmonton, AB, Canada

Corresponding Author:

Christopher Fung, University of Alberta, 2B2.41 WMC, 8440-112 Street NW, Edmonton, AB T6G 2B7, Canada.

Email: christopherfung@mic.ca

Table 1. Recommendation Text, Symbol, and Interpretation.

Recommendation	AGAINST	FOR
STRONG	<p>Strong, against “we recommend against” (⇓)</p> <ul style="list-style-type: none"> All or almost all informed people would not recommend/choose the course of action and only a small proportion would. 	<p>Strong, for “we recommend” (⇑)</p> <ul style="list-style-type: none"> All or almost all informed people would recommend/choose the course of action and only a small proportion would not. Request discussion if the intervention is not offered.
CONDITIONAL	<p>Conditional, against “we suggest against” (↓)</p> <ul style="list-style-type: none"> Most informed people would not recommend/choose the course of action, but a substantial number would. This may be conditional upon patient values and preferences, the resources available or the setting in which the intervention will be implemented. 	<p>Conditional, for “we suggest” (↑)</p> <ul style="list-style-type: none"> Most informed people would recommend/choose the course of action, but a substantial number would not. This may be conditional upon patient values and preferences, the resources available or the setting in which the intervention will be implemented.

Note. Down arrows are red and Up arrows are green when available in colour. Created using the guidance provided in Andrews et al.⁶

Introduction

Beginning in March 2022, an Expert Panel (EP) comprised of radiologists, a gastroenterologist, a general surgeon, a family physician, a patient advisor, and an epidemiologist/guideline methodologist met to develop a new set of recommendations specific to referral pathways for adults for conditions related to the gastrointestinal (GI) system. Through discussion (via a virtual meeting) followed by offline communication, the EP developed a list of 20 clinical/diagnostic scenarios to be covered by this guideline. These recommendations are intended primarily for referring clinicians (eg, family physicians, specialty physicians, nurse practitioners); however, they may also be used by radiologists, individuals/patients, and patient representatives.

Our methods describing the guideline development process, including the rapid scoping review to identify the evidence base, has been published in *CMAJ Open*¹ and an editorial to this series of guideline publications is available in *CARJ*.² The application of well-established scoping review and rapid review guidance (JBI,³ Cochrane Handbook,⁴ Cochrane Rapid Review Methods Group⁵) and guideline methodology (ie, Grading of Recommendations Assessment, Development, and Evaluation or GRADE^{6,7}) were used to identify the evidence-base and to guide the Expert Panel in determining the strength and direction of the recommendations for each clinical scenario (Table 1). The quality of conduct and reporting of the included guidelines identified in the scoping review were evaluated with the AGREE-II checklist,⁸ using a modified scoring system. In instances where guidelines were lacking, expert consensus was used to develop the recommendation. Contextualization to the Canadian health

care system was considered for each recommendation, with discussion around the factors found in the Evidence to Decision framework in GRADE for guidelines (eg, balance of desirable and undesirable outcomes, values and preferences, resources implications).⁷

A systematic search for guidelines (with an a priori defined inclusion criteria) was run in Medline and Embase on April 28, 2022. The search was limited to publications from 2016 onward (Supplemental Appendix 1). Supplemental searching included the following national radiology and/or guideline groups: the American College of Radiology, the National Institute for Health and Care Excellence, and the Royal College of Radiologists 8th Edition (2017). Recommendations for each clinical scenario were formulated over a 1-day hybrid in-person/virtual meeting on December 8, 2022. External review and feedback were obtained from radiologists, a nuclear medicine radiologist, emergency physicians, a surgeon, a family medicine physician, and a nurse practitioner. The full guideline can be found on the CAR website (www.car.ca).

Results

Systematic Scoping Review

A total of 5614 records were identified through the electronic database and 4 additional records were added from the supplemental search. Thirty guidelines, plus 2 companion papers, were included (Figure 1). Potentially relevant guidelines published in languages other than English can be found in Supplemental Appendix 2. A list of excluded records including justifications for exclusion is available upon request.

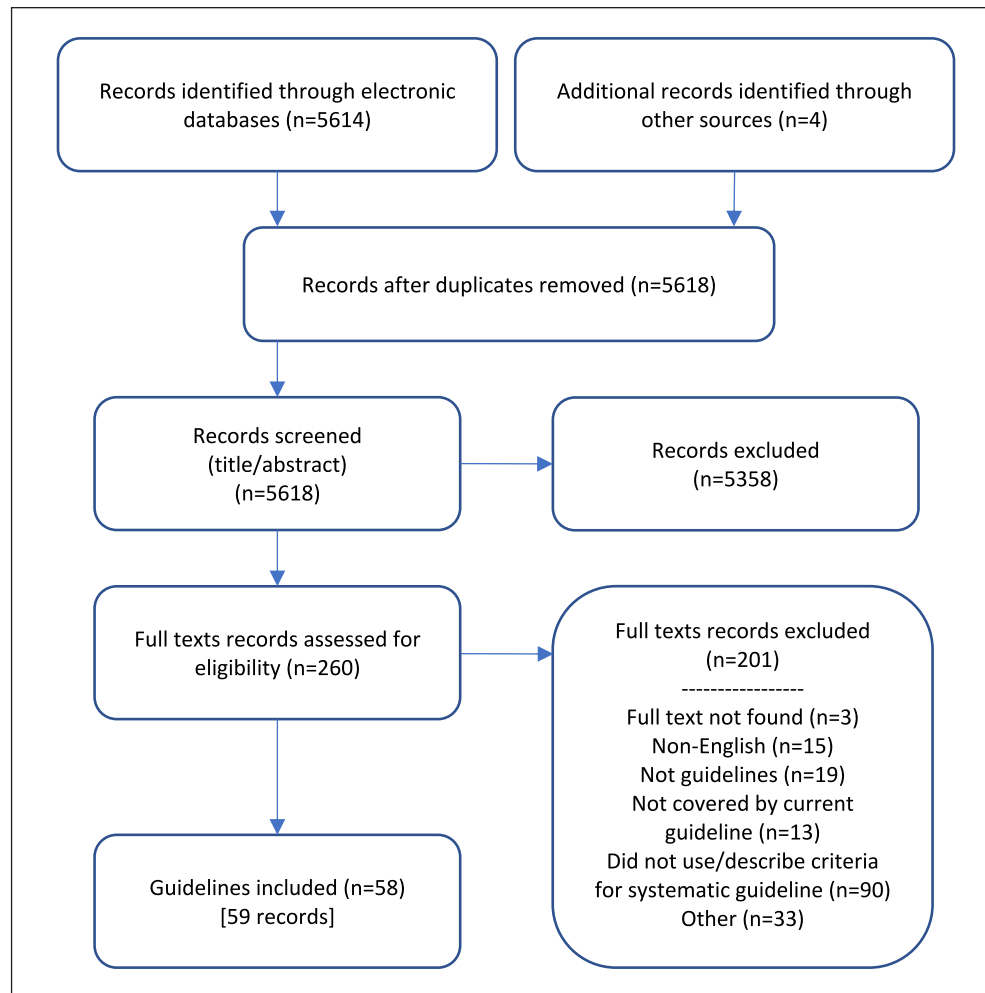


Figure 1. PRISMA flow diagram.

Most guidelines were rated as moderate or high quality, using the modified AGREE-II checklist⁸ (Supplemental Appendix 3). The number of guidelines included per clinical/diagnostic scenario ranged from 1 to 9, with a median of 4 guidelines per clinical scenario.

Recommendations

Additional details of the included guidelines, including which imaging modalities (eg, computed tomography [CT], computed tomography angiography [CTA], magnetic resonance cholangiopancreatography [MRCP], magnetic resonance imaging [MRI], nuclear medicine [NM], radiograph [XR], ultrasound [US]) that were discussed can be found in Supplemental Appendix 4.

A guideline is intended to guide and not be an absolute rule. Medical care is complex and should be based on evidence, a clinician's expert judgment, the patient's circumstances,

values, preferences, and resource availability. Not all imaging modalities are available in all clinical environments, particularly in rural or remote areas of Canada. Decisions about patient transfer, use of alternative imaging or serial clinical examination and observation can be difficult. Therefore, the expected benefits of recommended imaging, risks of travel, patient preference, and other factors must be considered. The guideline recommendations are to assist the choice of imaging modality in situations where it is deemed clinically necessary to obtain imaging.

Unless the panel agreed a specific protocol is required to optimize patient care/diagnosis, the recommendations do not specify when contrast should or should not be used, as this may vary based on clinical presentation, regional practice preferences, preference of the referring clinician, radiologist and the patient, and resource availability.

We reviewed relevant recommendations related to the 20 clinical/diagnostic scenarios previously published by radiology

and specialty societies, including: the Canadian Association of Radiologists,⁹ the American College of Gastroenterology,¹⁰ the American College of Gastroenterology,¹¹ the American College of Gastroenterology and the Canadian Association of Gastroenterology,¹² the American College of Physicians,¹³ the American College of Radiology,¹⁴⁻²⁸ the American Society for Gastrointestinal Endoscopy,^{29,30} the Asociación Mexicana de Gastroenterología,³¹ the Association of Coloproctology of Great Britain and Ireland,³² the British Society of Gastroenterology,^{33,34} the British Society of Gastroenterology and the United Kingdom Primary Sclerosing Cholangitis,³⁵ the Canadian Association of Gastroenterology,³⁶ the European Association for Endoscopic Surgery,³⁷ the European Association for Endoscopic Surgery and the Society of American Gastrointestinal and Endoscopic Surgeons,³⁸ the European Association for the Study of the Liver,³⁹ the European Society of Coloproctology,⁴⁰ the European Society of Gastrointestinal Endoscopy,^{41,42} the European Society of Gastrointestinal Endoscopy and the European Association for the Study of the Liver,⁴³ the European Society for Trauma and Emergency Surgery,⁴⁴ the German Guideline,⁴⁵ the German Society for Digestive and Metabolic Diseases (DGVS),⁴⁶ the Infectious Diseases Society of America,⁴⁷ the International Consensus on Diverticulosis and Diverticular Disease,⁴⁸ the International Society for Esophageal Diseases,⁴⁹ the Italian Association of Hospital Gastroenterologists and

Endoscopists and the Italian Society of Paediatric Gastroenterology Hepatology and Nutrition,⁵⁰ the Italian Polispecialistic Society of Young Surgeons (SPIGC),⁵¹ the Japan Gastroenterological Association,⁵² the Japanese Society of Gastroenterology,^{53,54} the Joint European Guideline,⁵⁵ the Korean Society of Neurogastroenterology and Motility and Asian Neurogastroenterology and Motility Association,⁵⁶ the National Institute for Health and Clinical Excellence,⁵⁷ the Polish Society of Gastroenterology and the Polish National Consultant in Gastroenterology,⁵⁸ the Royal College of Radiologists,⁵⁹ the Society of American Gastrointestinal and Endoscopic Surgeons, the Société française de chirurgie digestive and the Société d'imagerie abdominale et digestive,⁶⁰ the Society for Vascular Surgery,⁶¹ the Taiwanese Guideline,⁶² the United European Gastroenterology,^{63,64} the United European Gastroenterology and the European Society of Neurogastroenterology and Motility,⁶⁵ and the World Society of Emergency Surgery.^{66,67}

Recommendations are presented in 3 tables: Dysphagia/dyspepsia, acute nonlocalized and acute localized abdominal pain recommendations (Table 2), Chronic abdominal pain, inflammatory bowel disease, acute GI bleeding, chronic GI bleeding, abnormal liver biopsy recommendations (Table 3), and Pancreatitis, anorectal disease, diarrhea, fecal incontinence, and foreign body ingestion recommendations (Table 4).

Table 2. Dysphagia/Dyspepsia, Acute Nonlocalized and Acute Localized Abdominal Pain Recommendations.

Clinical/diagnostic scenario and recommendations

G101. DYSPHAGIA/DYSPEPSIA^{9,12,14,15,36,49,56,59,65}

The guideline recommendations are to assist the choice of imaging modality in situations where it is felt clinically and/or biochemically necessary to obtain imaging (eg, **if endoscopy is not readily available**, if the patient declines endoscopy). If imaging is required, then:

1. In patients with dysphagia, we suggest **fluoroscopy (esophagram or upper GI series)** as the initial imaging modality (↑).
2. In patients with dyspepsia of unknown cause, we suggest **fluoroscopy upper GI series** as the initial imaging modality (↑).
3. In patients with dyspepsia if there is clinical suspicion of abnormal gastric motility, we suggest **NM scintigraphy (gastric emptying)** as the initial imaging modality (↑).

For patients with concern for gastroesophageal reflux, see G103D. Left upper quadrant pain.

G102. ACUTE NONLOCALIZED ABDOMINAL PAIN^{9,16-18,32,59}

1. In patients with suspected uncomplicated acute infectious colitis presenting with acute nonlocalized abdominal pain, we recommend **against imaging** in the absence of other concerning clinical and/or biochemical findings (↓↓).

The guideline recommendations are to assist the choice of imaging modality in situations where it is felt clinically and/or biochemically necessary to obtain imaging. If imaging is required, then:

2. In non-pregnant patients with acute nonlocalized abdominal pain and/or bowel obstruction, we suggest **XR** as the initial imaging modality (↑).
 - ↳ **2.1** If XR is equivocal and/or further investigation is required, we recommend **CT abdomen and pelvis** as the next imaging modality (↑↑).
3. In pregnant patients with acute nonlocalized abdominal pain, we recommend **US abdomen and pelvis** as the initial imaging modality (↑↑).

If there is clinical concern for appendicitis, see G103C. Right lower quadrant pain.

(continued)

Table 2. (continued)

Clinical/diagnostic scenario and recommendations

GI03. ACUTE LOCALIZED ABDOMINAL PAIN

GI03A. Epigastric pain¹⁵

The guideline recommendations are to assist the choice of imaging modality in situations where it is felt clinically and/or biochemically necessary to obtain imaging (eg, **if endoscopy it is not readily available**, if the patient declines endoscopy). If imaging is required, then:

1. In patients with epigastric pain with probable esophageal or gastric etiology, we suggest **fluoroscopy upper GI series** as the initial imaging modality (↑).
 - ↳ 1.1 If upper GI series is not available, we suggest a **CT abdomen and pelvis** (↑).
2. In patients with epigastric pain without probable esophageal or gastric etiology, we suggest a **CT abdomen and pelvis** as the initial imaging modality (↑).

GI03B. Right upper quadrant pain^{19,35,39,43,44,59}

1. In patients with right upper quadrant pain (suspected hepatobiliary disease), we recommend against **XR** (↓↓).
2. In patients with right upper quadrant pain (suspected hepatobiliary disease), we recommend **US abdomen** as the initial imaging modality (↑↑).
 - ↳ 2.1 If US is not available or further investigation is required, we suggest **CT abdomen and pelvis or NM (HIDA scan)** as the next imaging modality (↑).
 - ↳ 2.2 If US is indeterminate and the clinical/biochemical presentation is strongly suggestive of choledocolithiasis, we suggest consultation for **endoscopic US/ERCP** and/or **MRCP** (↑).
3. In patients with right upper quadrant pain (non-hepatobiliary disease), we recommend **US abdomen** as the initial imaging modality (EP consensus).
 - ↳ 3.1 If US is indeterminate, we suggest **CT abdomen and pelvis** as the next imaging modality (EP consensus).
 - ↳ 3.2 If US and CT are not immediately available, we suggest **XR** as the initial imaging modality (EP consensus).

GI03C. Right lower quadrant pain^{20,37,51,60,66}

1. In younger patients with right lower quadrant pain, we recommend **US** as the initial imaging modality, as per ALARA principles (↑↑).
 - ↳ 1.1 In non-pregnant patients, if US is negative for appendicitis or inconclusive and further imaging is required, we suggest **CT abdomen and pelvis** as the next imaging modality (↑).
 - ↳ 1.2 In pregnant patients, if US is inconclusive for appendicitis, we recommend **MR abdomen and pelvis** as the next imaging modality (↑↑).
2. In older patients with right lower quadrant pain, we recommend **CT abdomen and pelvis** as the initial imaging modality (↑↑).
ALARA “as low as reasonably achievable” principles: Time, Distance, and Shielding
For suspected gynecologic pathology, see OG08. Evaluation of acute pelvic pain of presumed gynecology origin in the CAR Obstetrics and Gynecology Imaging Referral Guideline (DOI: 10.1177/08465371231185292)

GI03D. Left upper quadrant pain¹⁵

1. In patients with left upper quadrant pain (concern for reflux or ulcer), we suggest **against fluoroscopic upper GI series** (↓).
Fluoroscopic upper GI series may be considered in institutions with expertise in this exam for patients where endoscopy is not available, not indicated, or declined by patient.
2. In patients with left upper quadrant pain (unknown etiology), we recommend **US abdomen** as the initial imaging modality (EP consensus).
 - ↳ 2.1 If US is indeterminate, we suggest **CT abdomen and pelvis** as the next imaging modality (EP consensus).
 - ↳ 2.2 If US and CT are not immediately available, we suggest **XR** as the initial imaging modality (EP consensus).

GI03E. Left lower quadrant pain^{13,21,31,32,38,40,48,52}

1. In patients with left lower quadrant pain (suspected diverticulitis), we recommend **CT abdomen and pelvis** as the initial imaging modality (↑↑).
2. In patients with left lower quadrant pain (other intraabdominal cause), we recommend **XR** as the initial imaging modality (EP consensus).
 - ↳ 2.1 If XR is negative or indeterminate and further imaging is required, we suggest **CT abdomen and pelvis** as the next imaging modality (EP consensus).
 - ↳ 2.2 In younger patients or if CT is contraindicated, we suggest **US** as the next imaging modality (EP consensus).

For suspected gynecologic pathology, see OG08. Evaluation of acute pelvic pain of presumed gynecology origin in the CAR Obstetrics and Gynecology Imaging Referral Guideline (DOI: 10.1177/08465371231185292)

Note. Strength of recommendation: ↑↑=strong for; ↑=conditional for; ↓=conditional against; ↓↓=strong against. CT=computed tomography; ERCP=endoscopic retrograde cholangiopancreatography; GI=gastrointestinal; MRCP=magnetic resonance cholangiopancreatography; MR=magnetic resonance; NM=nuclear medicine; US=ultrasound; XR=radiograph.

Table 3. Chronic Abdominal Pain, Inflammatory Bowel Disease, Acute GI Bleeding, Chronic GI Bleeding, Abnormal Liver Biopsy Recommendations.**Clinical/diagnostic scenario and recommendations****GI04. CHRONIC ABDOMINAL PAIN**^{9,16,53,55,57,61}

1. In patients who meet the diagnostic criteria for irritable bowel syndrome, we recommend **against imaging** in the absence of concerning clinical and/or biochemical findings (↓↓).
2. In patients with chronic abdominal pain, we recommend **against MRI** as an imaging modality due to limited sensitivity and specificity (EP consensus).
3. In patients with chronic abdominal pain, we recommend **CT abdomen and pelvis** as the initial imaging modality (↑↑).
 - ↳ **3.1** If CT is unavailable, we suggest **US abdomen** as an alternative imaging modality, accepting its limited scope of assessment compared to CT (↑).
4. In patients with chronic abdominal pain (suspected chronic mesenteric ischemia), we recommend **CTA abdomen and pelvis** as the initial imaging modality (↑↑).

GI05. INFLAMMATORY BOWEL DISEASE^{9,10,22,46,54,58,59}**In endoscopy-negative patients with suspected inflammatory bowel disease**

1. In endoscopy-negative patients with suspected inflammatory bowel disease, we recommend **against fluoroscopy small bowel follow through** (↓↓).
2. In younger patients with suspected inflammatory bowel disease, we recommend **MR enterography** as the initial imaging modality (↑↑).
 - ↳ **2.1** If MR enterography is contraindicated or unavailable, we suggest **CT enterography** (↑).
3. In older patients with suspected inflammatory bowel disease, we recommend **CT enterography** as the initial imaging modality (↑↑).
 - ↳ **3.1** If CT enterography cannot be tolerated, we suggest **CT abdomen and pelvis** (↑).

In non-obstructed patients with suspected acute exacerbation of known inflammatory bowel disease

4. In younger patients with suspected acute exacerbation of known inflammatory bowel disease, we recommend **MR enterography** as the initial imaging modality (↑↑).
 - ↳ **4.1** If MR enterography is contraindicated or unavailable, we suggest **CT enterography** (↑).
 - ↳ **4.2** If MR/CT enterography cannot be tolerated, we recommend **CT abdomen and pelvis** (↑↑).
5. In older patients with inflammatory bowel disease with suspected acute exacerbation, we recommend **CT enterography** as the initial imaging modality (↑↑).
 - ↳ **5.1** If CT enterography cannot be tolerated, we recommend **CT abdomen and pelvis** (↑↑).

If clinical concern for obstruction, see GI02. Acute nonlocalized abdominal pain

GI06. ACUTE GI BLEEDING**GI06A. Upper acute GI bleeding**^{9,23,29,59}

The guideline recommendations are to assist the choice of imaging modality in situations where it is felt clinically and/or biochemically necessary to obtain imaging (eg, **if endoscopy confirms nonvariceal upper GI bleeding, endoscopy is not readily available/contraindicated**). If imaging is required, then:

1. In patients with acute upper GI bleeding, we recommend **CTA or Diagnostic angiography** as the initial imaging modality (↑↑).

GI06B. Lower acute GI bleeding^{24,32,33,41,48,52}

The guideline recommendations are to assist the choice of imaging modality in situations where it is felt clinically and/or biochemically necessary to obtain imaging (eg, **if endoscopy is not readily available/contraindicated**). If imaging is required, then:

1. In patients with acute lower GI bleeding, we recommend **CTA or Diagnostic angiography** as the initial imaging modality (↑↑).
 - ↳ **1.1** If CTA is negative or inconclusive, we suggest **NM scintigraphy (RBC scan)** (↑).

GI07. CHRONIC GI BLEEDING/ANEMIA^{9,50,59}

1. In patients with suspected chronic GI bleeding, we suggest **against routine use of MR enterography** due to limited spatial resolution (↓).

The guideline recommendations are to assist the choice of imaging modality in situations where it is felt clinically and/or biochemically necessary to obtain imaging (eg, **if endoscopy it is not readily available**, if the patient declines endoscopy). If imaging is required, then:

2. In patients with suspected chronic GI bleeding, we recommend **CT enterography** as the initial imaging modality (↑↑).
 - ↳ **2.1** If CT enterography cannot be tolerated, we suggest **CT abdomen and pelvis** (↑).
 - ↳ **2.2** If CT enterography is negative and further investigation is required, we suggest **NM scintigraphy (RBC and/or Meckel's study) ± capsule endoscopy** as the next imaging modality (↑).

Consultation with a nuclear medicine physician and/or gastroenterologist is suggested to determine the need for further evaluation with NM scintigraphy and/or capsule endoscopy due to varying regional practice preferences.

(continued)

Table 3. (continued)**Clinical/diagnostic scenario and recommendations****GI08. ABNORMAL LIVER BIOCHEMISTRY****GI08A. Acute abnormal liver biochemistry**^{9,25,30,59}

1. In patients with acute abnormal liver biochemistry, we recommend **US abdomen** as the initial imaging modality (↑↑).
 - ↳ 1.1 If US is inconclusive or if further investigation is required, we suggest **CT abdomen or MR abdomen** (equivalent alternatives) as the next imaging modality (↑).

For suspected biliary disease, see GI03B. Right upper quadrant pain.

GI08B. Chronic abnormal liver biochemistry^{9,26}

The guideline recommendations are to assist the choice of imaging modality in situations where it is felt clinically and/or biochemically necessary to obtain imaging. If imaging is required, then:

1. In patients with chronic abnormal liver biochemistry, we recommend **US abdomen** as the initial imaging modality, ideally with the use of a high frequency linear probe to assess the hepatic surface (↑↑).
 - ↳ 1.1 If further investigation is required, we recommend **MR abdomen** as the next imaging modality (↑↑).
 - ↳ 1.2 If MR abdomen is contraindicated or unavailable, we suggest **CT abdomen** (↑).
2. In noncirrhotic patients with chronic abnormal liver biochemistry, if available, we suggest **US shear wave elastography** in addition to **US abdomen** to diagnose, follow, or stage occult hepatic fibrosis (↑).
 - ↳ 2.1 If US shear wave elastography is not available or inconclusive and imaging is required, we suggest **MR elastography** (↑).

Although MR elastography is more sensitive and specific than US shear wave elastography, due to accessibility concerns, the Expert Panel chose to suggest US shear wave elastography ahead of MR elastography.

Note. Strength of recommendation: ↑↑ = strong for; ↑ = conditional for; ↓ = conditional against; ↓↓ = strong against. CT = computed tomography; CTA = computed tomography angiography; MR = magnetic resonance; MRI = magnetic resonance imaging; NM = nuclear medicine; RBC = red blood cell; US = ultrasound.

Table 4. Pancreatitis, Anorectal Disease, Diarrhea, Fecal Incontinence, Foreign Body Ingestion Recommendations.**Clinical/diagnostic scenario and recommendations****GI09. PANCREATITIS****GI09A. Acute pancreatitis**^{9,27,30,42,59,62}

1. As per the revised Atlanta Criteria, in patients who meet the diagnostic criteria for acute pancreatitis, we recommend **against imaging** for the purpose of diagnosis (↓↓).

The guideline recommendations are to assist the choice of imaging modality in situations where it is clinically and/or biochemically necessary to obtain imaging as per the revised Atlanta Criteria.⁶⁸ If imaging is required, then:

2. In patients with suspected acute pancreatitis due to gallstones, we recommend **US abdomen** as the initial imaging modality (↑↑).
 - ↳ 2.1 If further investigation is required, we recommend **MR abdomen with MRCP** as the next imaging modality (↑↑).
3. In patients with suspected complicated sub-acute pancreatitis, we recommend imaging as per the revised Atlanta Criteria (↑↑).

GI09B. Chronic pancreatitis^{9,11,59,63,64}

1. In patients with suspected chronic pancreatitis, we recommend **CT abdomen** as the initial imaging modality (↑↑).
 - ↳ 1.1 If CT is negative, we suggest **GI referral ± endoscopic US** (↑).
2. In patients with known chronic pancreatitis, we recommend **MR abdomen with MRCP** for any required follow-up imaging (↑↑).
 - ↳ 2.1 If MR abdomen is contraindicated or unavailable, we suggest **CT abdomen** (↑).

(continued)

Table 4. (continued)

Clinical/diagnostic scenario and recommendations

GI10. ANORECTAL DISEASES^{28,45}

1. In patients with suspected perianal fistula, we recommend **against CT pelvis** (↓↓).
 2. In patients with suspected perianal fistula, we recommend **MR pelvis** as the initial imaging modality (↑↑).
 - ↳ **2.1** If MRI is not available or contraindicated, we suggest **endoanal US** as an alternative imaging modality (↑).
 3. In patients with suspected perianal abscess, we recommend **MR pelvis** as the initial imaging modality (↑↑).
 - ↳ **3.1** If MRI is not available or contraindicated, we suggest **endoanal US** as an alternative imaging modality (↑).
 - ↳ **3.2** In patients with suspected large perianal abscess, if MRI or US is not available or contraindicated, we suggest **CT pelvis** as an alternative imaging modality (↑).
 4. In patients with suspected anovesicular or anovaginal fistula, we recommend **CT pelvis** (↑↑).
 - ↳ **4.1** In patients with suspected anovesicular or anovaginal fistula, we suggest **MR pelvis** as an alternative imaging modality (↑).
The choice of CT pelvis with rectal contrast or MR pelvis may vary based on regional practice preferences.
-

GI11. DIARRHEA^{34,47}

1. In patients with suspected uncomplicated acute infectious colitis presenting with acute nonlocalized abdominal pain, we recommend **against imaging** in the absence of other concerning clinical and/or biochemical findings (↓↓).

The guideline recommendations are to assist the choice of imaging modality in situations where it is felt clinically and/or biochemically necessary to obtain imaging. If imaging is required, then:

2. In patients with diarrhea (unknown cause), we suggest **XR** as the initial imaging modality (↑).
 - ↳ **2.1** If XR is inconclusive, we suggest **specialist consultation (eg, gastroenterology, general surgery)** and/or **CT abdomen and pelvis** (↑).
-

GI12. FECAL INCONTINENCE^{9,59}

1. In patients with fecal incontinence (clinically diagnosed constipation), we recommend **against imaging** in the absence of other concerning clinical and/or biochemical findings (↓↓).

The guideline recommendations are to assist the choice of imaging modality in situations where it is felt clinically and/or biochemically necessary to obtain imaging. If imaging is required, then:

2. In patients with fecal incontinence (clinically indeterminate for constipation), we suggest **XR** as the initial imaging modality (↑).
 3. In patients with fecal incontinence (suspected cauda equina), we recommend **MR lumbar spine** as the initial imaging modality (EP consensus).
 4. In patients with fecal incontinence (suspected pelvic floor dysfunction), we suggest **dynamic MR pelvic floor** (EP consensus).
 - ↳ **4.1** If MRI is not available or contraindicated, we suggest **fluoroscopic defecography** (EP consensus).
-

GI13. FOREIGN BODY INGESTION^{9,67}

1. In patients with suspected or known foreign body ingestion, we recommend **XR** as the initial imaging modality (↑↑).
 - ↳ **1.1** If XR is suspicious for obstruction or perforation, we suggest **CT abdomen and pelvis** as the next imaging modality (↑).
 - ↳ **1.2** If XR is negative and additional management is being considered, we suggest **CT abdomen and pelvis** as the next imaging modality (↑).

For foreign body ingestion in children, see the CAR Pediatrics Imaging Referral Guideline.

Note. Strength of recommendation: ↑↑ = strong for; ↑ = conditional for; ↓ = conditional against; ↓↓ = strong against. CT = computed tomography; GI = gastrointestinal; MR = magnetic resonance; MRCP = magnetic resonance cholangiopancreatography; US = ultrasound; XR = radiograph.

Acknowledgments

We would like to thank: Becky Skidmore for creating the search strategies for the systematic scoping review, Leila Esmaeilisaraji for her role as a reviewer on the scoping review, and the following individuals on the Diagnostic Imaging Referral Guidelines Working Group and external stakeholders for providing feedback on the guideline (listed alphabetically): Steve Burrell, Sam Campbell, Amanda Fowler, Joel Koops, Ryan Margau (WG co-chair), Paul Pageau (WG co-chair), Eric Sala, Erin Sarrazin, and Kaitlin Zaki-Metias.

Declaration of Conflicting Interests

The author(s) declared no potential conflicts of interest with respect to the research, authorship, and/or publication of this article.

Funding

The author(s) disclosed receipt of the following financial support for the research, authorship, and/or publication of this article: This work was supported by the Canadian Medical Association.

ORCID iDCandye Hamel  <https://orcid.org/0000-0002-5871-2137>**Supplemental Material**

Supplemental material for this article is available online.

References

- Hamel C, Margau R, Pageau P, et al. Canadian Association of Radiologists diagnostic imaging referral guidelines: a guideline development protocol. *CMAJ Open*. 2023;11(2):E248-E254. doi:10.9778/cmajo.20220098
- Hamel C, Venturi M, Margau R, Pageau P. Canadian Association of Radiologists diagnostic imaging referral guidelines. *Can Assoc Radiol J*. 2023;74:614-615. doi:10.1177/08465371231169746
- Peters M, Godfrey C, McInerney P, Munn Z, Tricco A, Khalil H. Chapter 11: Scoping reviews. In: Aromataris E, Munn Z, eds. *JBI Manual for Evidence Synthesis*. The Joanna Briggs Institute; 2020. Accessed February 24, 2021. <https://doi.org/10.46658/JBIMES-20-12>
- Higgins J, Thomas J, Chandler J, et al. *Cochrane Handbook for Systematic Reviews of Interventions Version 6.2 (Updated February 2021)*; 2021. Accessed April 20, 2022. www.training.cochrane.org/handbook
- Garrity C, Gartlehner G, Nussbaumer-Streit B, et al. Cochrane Rapid Reviews Methods Group offers evidence-informed guidance to conduct rapid reviews. *J Clin Epidemiol*. 2021;130:13-22. doi:10.1016/j.jclinepi.2020.10.007
- Andrews J, Guyatt G, Oxman AD, et al. GRADE guidelines: 14. Going from evidence to recommendations: the significance and presentation of recommendations. *J Clin Epidemiol*. 2013;66(7):719-725. doi:10.1016/j.jclinepi.2012.03.013
- Andrews JC, Schünemann HJ, Oxman AD, et al. GRADE guidelines: 15. Going from evidence to recommendation-determinants of a recommendation's direction and strength. *J Clin Epidemiol*. 2013;66(7):726-735. doi:10.1016/j.jclinepi.2013.02.003
- AGREE Next Steps Consortium. The AGREE II Instrument [Electronic Version]. Published 2017. Accessed March 3, 2022. <https://www.agreetrust.org/wp-content/uploads/2017/12/AGREE-II-Users-Manual-and-23-item-Instrument-2009-Update-2017.pdf>
- Canadian Association of Radiologists. *2012 CAR Diagnostic Imaging Referral Guidelines*. Canadian Association of Radiologists; 2012. Accessed July 5, 2021. <https://car.ca/patient-care/referral-guidelines/>
- Lichtenstein GR, Loftus EV, Isaacs KL, et al. ACG clinical guideline: management of Crohn's disease in adults. *Am J Gastroenterol*. 2018;113(4):481-517. doi:10.1038/ajg.2018.27
- Gardner TB, Adler DG, Forsmark CE, et al. ACG clinical guideline: chronic pancreatitis. *Am J Gastroenterol*. 2020;115(3):322-339. doi:10.14309/ajg.0000000000000535
- Moayyedi P, Lacy BE, Andrews CN, et al. ACG and CAG clinical guideline: management of dyspepsia. *Am J Gastroenterol*. 2017;112(7):988-1013. doi:10.1038/ajg.2017.154
- Qaseem A, Etzeandia-Ikobaltzeta I, Lin JS, et al. Diagnosis and management of acute left-sided colonic diverticulitis: a clinical guideline from the American College of Physicians. *Ann Intern Med*. 2022;175(3):399-415. doi:10.7326/M21-2710
- Expert Panel on Gastrointestinal Imaging, Levy AD, Carucci LR, et al. ACR Appropriateness Criteria® dysphagia. *J Am Coll Radiol*. 2019;16(5S):S104-S115. doi:10.1016/j.jacr.2019.02.007
- Expert Panel on Gastrointestinal Imaging, Vij A, Zaheer A, et al. ACR Appropriateness Criteria® epigastric pain. *J Am Coll Radiol*. 2021;18(11S):S330-S339. doi:10.1016/j.jacr.2021.08.006
- Ginsburg M, Obara P, Lambert DL, et al. ACR Appropriateness Criteria® imaging of mesenteric ischemia. *J Am Coll Radiol*. 2018;15(11S):S332-S340. doi:10.1016/j.jacr.2018.09.018
- Chang KJ, Marin D, Kim DH, et al. ACR Appropriateness Criteria® suspected small-bowel obstruction. *J Am Coll Radiol*. 2020;17(5S):S305-S314. doi:10.1016/j.jacr.2020.01.025
- Scheirey CD, Fowler KJ, Therrien JA, et al. ACR Appropriateness Criteria® acute nonlocalized abdominal pain. *J Am Coll Radiol*. 2018;15(11S):S217-S231. doi:10.1016/j.jacr.2018.09.010
- Expert Panel on Gastrointestinal Imaging, Peterson C, McNamara M, et al. ACR Appropriateness Criteria® right upper quadrant pain. *J Am Coll Radiol*. 2019;16(5S):S235-S243. doi:10.1016/j.jacr.2019.02.013
- Expert Panel on Gastrointestinal Imaging, Garcia EM, Camacho MA, et al. ACR Appropriateness Criteria® right lower quadrant pain-suspected appendicitis. *J Am Coll Radiol*. 2018;15(11S):S373-S387. doi:10.1016/j.jacr.2018.09.033
- Galgano SJ, McNamara MM, Peterson CM, et al. ACR Appropriateness Criteria® left lower quadrant pain-suspected diverticulitis. *J Am Coll Radiol*. 2019;16(5S):S141-S149. doi:10.1016/j.jacr.2019.02.015
- Expert Panel on Gastrointestinal Imaging, Kim DH, Chang KJ, et al. ACR Appropriateness Criteria® Crohn disease. *J Am Coll Radiol*. 2020;17(5S):S81-S99. doi:10.1016/j.jacr.2020.01.030
- Singh-Bhinder N, Kim DH, Holly BP, et al. ACR Appropriateness Criteria® nonvariceal upper gastrointestinal bleeding. *J Am Coll Radiol*. 2017;14(5S):S177-S188. doi:10.1016/j.jacr.2017.02.038
- Karuppasamy K, Kapoor BS, Fidelman N, et al. ACR Appropriateness Criteria® radiologic management of lower gastrointestinal tract bleeding: 2021 update. *J Am Coll Radiol*. 2021;18(5S):S139-S152. doi:10.1016/j.jacr.2021.02.018
- Expert Panel on Gastrointestinal Imaging, Hindman NM, Arif-Tiwari H, et al. ACR Appropriateness Criteria® Jaundice. *J Am Coll Radiol*. 2019;16(5S):S126-S140. doi:10.1016/j.jacr.2019.02.012
- Bashir MR, Horowitz JM, Kamel IR, et al. ACR Appropriateness Criteria® chronic liver disease. *J Am Coll Radiol*. 2020;17(5S):S70-S80. doi:10.1016/j.jacr.2020.01.023
- Expert Panel on Gastrointestinal Imaging, Porter KK, Zaheer A, et al. ACR Appropriateness Criteria® acute pancreatitis. *J Am Coll Radiol*. 2019;16(11S):S316-S330. doi:10.1016/j.jacr.2019.05.017
- Levy AD, Liu PS, Kim DH, et al. ACR Appropriateness Criteria® anorectal disease. *J Am Coll Radiol*. 2021;18(11S):S268-S282. doi:10.1016/j.jacr.2021.08.009
- Gurudu SR, Bruining DH, Acosta RD, et al. The role of endoscopy in the management of suspected small-bowel bleeding. *Gastrointest Endosc*. 2017;85(1):22-31. doi:10.1016/j.gie.2016.06.013
- Buxbaum JL, Abbas Fehmi SM, Sultan S, et al. ASGE guideline on the role of endoscopy in the evaluation and management of choledocholithiasis. *Gastrointest Endosc*. 2019;89(6):1075-1105.e15. doi:10.1016/j.gie.2018.10.001

31. Raña-Garibay R, Salgado-Nesme N, Carmona-Sánchez R, et al. The Mexican consensus on the diagnosis and treatment of diverticular disease of the colon. *Rev de Gastroenterol de Mex.* 2019;84(2):220-240. doi:10.1016/j.rgmexen.2019.01.006
32. Miller AS, Boyce K, Box B, et al. The Association of Coloproctology of Great Britain and Ireland consensus guidelines in emergency colorectal surgery. *Colorectal Dis.* 2021;23(2):476-547. doi:10.1111/codi.15503
33. Oakland K, Chadwick G, East JE, et al. Diagnosis and management of acute lower gastrointestinal bleeding: guidelines from the British Society of Gastroenterology. *Gut.* 2019;68(5):776-789. doi:10.1136/gutjnl-2018-317807
34. Arasaradnam RP, Brown S, Forbes A, et al. Guidelines for the investigation of chronic diarrhoea in adults: British Society of Gastroenterology, 3rd edition. *Gut.* 2018;67(8):1380-1399. doi:10.1136/gutjnl-2017-315909
35. Chapman MH, Thorburn D, Hirschfield GM, et al. British Society of Gastroenterology and UK-PSC guidelines for the diagnosis and management of primary sclerosing cholangitis. *Gut.* 2019;68(8):1356-1378. doi:10.1136/gutjnl-2018-317993
36. Liu LWC, Andrews CN, Armstrong D, et al. Clinical practice guidelines for the assessment of uninvestigated esophageal dysphagia. *J Can Assoc Gastroenterol.* 2018;1(1):5-19. doi:10.1093/jcag/gwx008
37. Antoniou SA, Mavridis D, Kontouli KM, et al. EAES rapid guideline: appendicitis in the elderly. *Surg Endosc.* 2021;35(7):3233-3243. doi:10.1007/s00464-021-08524-9
38. Francis NK, Sylla P, Abou-Khalil M, et al. EAES and SAGES 2018 consensus conference on acute diverticulitis management: evidence-based recommendations for clinical practice. *Surg Endosc.* 2019;33(9):2726-2741. doi:10.1007/s00464-019-06882-z
39. Hirschfield GM, Beuers U, Corpechot C, et al. EASL clinical practice guidelines: the diagnosis and management of patients with primary biliary cholangitis. *J Hepatol.* 2017;67(1):145-172. doi:10.1016/j.jhep.2017.03.022
40. Schultz JK, Azhar N, Binda GA, et al. European Society of Coloproctology: guidelines for the management of diverticular disease of the colon. *Colorectal Dis.* 2020;22(S2):5-28. doi:10.1111/codi.15140
41. Triantafyllou K, Gkolfakis P, Gralnek IM, et al. Diagnosis and management of acute lower gastrointestinal bleeding: European Society of Gastrointestinal Endoscopy (ESGE) guideline. *Endoscopy.* 2021;53(8):850-868. doi:10.1055/a-1528-2092
42. Manes G, Paspatis G, Aabakken L, et al. Endoscopic management of common bile duct stones: European Society of Gastrointestinal Endoscopy (ESGE) guideline. *Endoscopy.* 2019;51(5):472-491. doi:10.1055/a-0862-0346
43. Aabakken L, Karlsen T, Albert J, et al. Role of endoscopy in primary sclerosing cholangitis: European Society of Gastrointestinal Endoscopy (ESGE) and European Association for the Study of the Liver (EASL) clinical guideline. *Endoscopy.* 2017;49(6):588-608. doi:10.1055/s-0043-107029
44. Pereira J, Bass GA, Mariani D, et al. Surgeon-performed point-of-care ultrasound for acute cholecystitis: indications and limitations: a European Society for Trauma and Emergency Surgery (ESTES) consensus statement. *Eur J Trauma Emerg Surg.* 2020;46(1):173-183. doi:10.1007/s00068-019-01197-z
45. Ommer A, Herold A, Berg E, et al. German S3 guidelines: anal abscess and fistula (second revised version). *Langenbecks Arch Surg.* 2017;402(2):191-201. doi:10.1007/s00423-017-1563-z
46. Authors; Collaborators. Updated S3-Guideline Ulcerative Colitis. German Society for Digestive and Metabolic Diseases (DGVS): AWMF Registry 021/009. *Z Gastroenterol.* 2019;57(2):162-241. doi:10.1055/a-0824-0861
47. Shane AL, Mody RK, Crump JA, et al. 2017 Infectious Diseases Society of America clinical practice guidelines for the diagnosis and management of infectious diarrhea. *Clin Infect Dis.* 2017;65(12):e45-e80. doi:10.1093/cid/cix669
48. Tursi A, Brandimarte G, Di Mario F, et al. International consensus on diverticulosis and diverticular disease. Statements from the 3rd international symposium on diverticular disease. *J Gastrointestin Liver Dis.* 2020;28:57-66. doi:10.15403/jgld-562
49. Zaninotto G, Bennett C, Boeckxstaens G, et al. The 2018 ISDE achalasia guidelines. *Dis Esophagus.* 2018;31(9). doi:10.1093/dote/doy071
50. Elli L, Norsa L, Zullo A, et al. Diagnosis of chronic anaemia in gastrointestinal disorders: a guideline by the Italian Association of Hospital Gastroenterologists and Endoscopists (AIGO) and the Italian Society of Paediatric Gastroenterology Hepatology and Nutrition (SIGENP). *Dig Liver Dis.* 2019;51(4):471-483. doi:10.1016/j.dld.2019.01.022
51. Guaitoli E, Gallo G, Cardone E, et al. Consensus statement of the Italian Polispécialistic Society of Young Surgeons (SPIGC): diagnosis and treatment of acute appendicitis. *J Invest Surg.* 2021;34(10):1089-1103. doi:10.1080/08941939.2020.1740360
52. Nagata N, Ishii N, Manabe N, et al. Guidelines for colonic diverticular bleeding and colonic diverticulitis: Japan Gastroenterological Association. *Digestion.* 2019;99(Suppl. 1):1-26. doi:10.1159/000495282
53. Fukudo S, Okumura T, Inamori M, et al. Evidence-based clinical practice guidelines for irritable bowel syndrome 2020. *J Gastroenterol.* 2021;56(3):193-217. doi:10.1007/s00535-020-01746-z
54. Nakase H, Uchino M, Shinzaki S, et al. Evidence-based clinical practice guidelines for inflammatory bowel disease 2020. *J Gastroenterol.* 2021;56(6):489-526. doi:10.1007/s00535-021-01784-1
55. Terlouw LG, Moelker A, Abrahamsen J, et al. European guidelines on chronic mesenteric ischaemia – joint United European Gastroenterology, European Association for Gastroenterology, Endoscopy and nutrition, European Society of gastrointestinal and abdominal radiology, Netherlands Association of hepatogastroenterologists, Hellenic Society of Gastroenterology, Cardiovascular and Interventional Radiological Society of Europe, and Dutch mesenteric ischemia study group clinical guidelines on the diagnosis and treatment of patients with chronic mesenteric ischaemia. *United Eur Gastroenterol J.* 2020;8(4):371-395. doi:10.1177/2050640620916681
56. Jung HK, Hong SJ, Lee OY, et al. 2019 Seoul consensus on esophageal achalasia guidelines. *J Neurogastroenterol Motil.* 2020;26(2):180-203. doi:10.5056/jnm20014
57. NICE. Overview | Irritable bowel syndrome in adults: diagnosis and management | Guidance. (Updated April 4, 2017); 2008. Accessed June 17, 2022. <https://www.nice.org.uk/guidance/cg61>

58. Lodyga M, Eder P, Gawron-Kiszka M, et al. Guidelines for the management of patients with Crohn's disease. *Recommendations of the Polish Society of Gastroenterology and the Polish National Consultant in Gastroenterology*. 2021;16(4):257-296. doi:10.5114/pg.2021.110914
59. The Royal College of Radiologists. *RCR iRefer Guidelines: Making the Best Use of Clinical Radiology*. The Royal College of Radiologists; 2017.
60. Collard MK, Christou N, Lakkis Z, et al. Adult appendicitis: clinical practice guidelines from the French Society of Digestive Surgery and the Society of Abdominal and digestive imaging. *J Visc Surg*. 2021;158(3):242-252. doi:10.1016/j.jvisurg.2020.11.013
61. Huber TS, Björck M, Chandra A, et al. Chronic mesenteric ischemia: clinical practice guidelines from the Society for Vascular Surgery. *J Vasc Surg*. 2021;73(1):87S-115S. doi:10.1016/j.jvs.2020.10.029
62. Liao WC, Tu TC, Lee KC, et al. Taiwanese consensus recommendations for acute pancreatitis. *J Formos Med Assoc*. 2020;119(9):1343-1352. doi:10.1016/j.jfma.2019.07.019
63. Löhner JM, Dominguez-Munoz E, Rosendahl J, et al. United European gastroenterology evidence-based guidelines for the diagnosis and therapy of chronic pancreatitis (HaPanEU). *United Eur Gastroenterol J*. 2017;5(2):153-199. doi:10.1177/2050640616684695
64. Dominguez-Munoz JE, Drewes AM, Lindkvist B, et al. Recommendations from the United European Gastroenterology evidence-based guidelines for the diagnosis and therapy of chronic pancreatitis. *Pancreatol*. 2018;18(8):847-854. doi:10.1016/j.pan.2018.09.016
65. Oude Nijhuis RAB, Zaninotto G, Roman S, et al. European guidelines on achalasia: United European Gastroenterology and European Society of neurogastroenterology and motility recommendations. *United Eur Gastroenterol J*. 2020;8(1):13-33. doi:10.1177/2050640620903213
66. Di Saverio S, Podda M, De Simone B, et al. Diagnosis and treatment of acute appendicitis: 2020 update of the WSES Jerusalem guidelines. *World J Emerg Surg*. 2020;15(1):27. doi:10.1186/s13017-020-00306-3
67. Chirica M, Kelly MD, Siboni S, et al. Esophageal emergencies: WSES guidelines. *World J Emerg Surg*. 2019;14(1):26. doi:10.1186/s13017-019-0245-2
68. Banks PA, Bollen TL, Dervenis C, et al. Classification of acute pancreatitis—2012: revision of the Atlanta classification and definitions by international consensus. *Gut*. 2013;62(1):102-111. doi:10.1136/gutjnl-2012-302779